

## Angiographic Coronary Morphology in Patients With Ischemic Heart Disease

Toshiro NAGOSHI, MD  
Yasushi KOIWAYA, MD, FJCC  
Hideo DOI, MD  
Tanenao ETO, MD

### Abstract

**Objectives.** To determine whether ischemia- or infarct-related arteries (IRAs) are accompanied by certain findings specific to clinical settings, coronary cineangiography was reviewed of 71 patients with stable effort angina pectoris (SAP), 72 with unstable angina pectoris (UAP), 118 with acute myocardial infarction (AMI) and 137 with old myocardial infarction (OMI).

**Methods.** The morphology of identifiable ischemia- or infarct-related lesions (IRLs) was classified as totally occlusive, and simple (Type 1 lesion) or complex (Type 2 lesion). Complex lesions were subdivided into Type a lesions (narrowing with irregular, poorly defined or hazy borders, sharp leading or trailing edges that overhang or are perpendicular to vessel walls, and globular endoluminal negative images), Type b (2 or more serial, closely spaced narrowings together with multiple irregularities), Type c (luminal narrowing with extraluminal contrast pooling, single or paired short thin linear radiolucencies with or without a variable degree of outpouching, and narrowing with definite outpouching with or without radiolucency), and Type d (narrowing with morphology not included in Types a - c).

**Results.** Total occlusive lesions among identifiable IRLs occurred at 17 sites (23.9%) in patients with SAP, 7 (9.7%) with UAP, 48 (40.7%) with AMI and 30 (21.9%) with OMI. The mean diameter stenosis of identifiable IRLs was 89.4% in patients with SAP, 92.0% with UAP, 93.1% with AMI, and 87.4% with OMI. Patent identifiable IRLs in patients with SAP had a significantly higher frequency of Type 1 lesions (29 sites, 40.8%) compared with those with UAP, AMI and OMI ( $p < 0.01$ ) followed by a relatively lower occurrence of Types a (12 (16.9%), b (11.3%), c (4.2%) and d (2.9%) lesions. Patients with UAP were characterized by a higher occurrence of Type a (34 sites, 47.2%,  $p < 0.01$ ) and c (13 sites, 18.1%,  $p < 0.01$ ) lesions compared with those with SAP. Patients with AMI had total occlusion (48 sites, 40.7%,  $p < 0.05$ ) and Type a lesion (38 sites, 32.2%,  $p < 0.05$ ) more frequently than those with SAP. Patients with OMI showed fewer total occlusions (30 sites, 21.9%), same occurrence of Type a lesion (39 sites, 28.5%), and higher occurrence of b (23 sites, 16.8%) and c (20 sites, 14.6%) than those with AMI.

**Conclusions.** This analysis of coronary cineangiographies from patients with UAP, AMI and OMI, which share a common pathogenesis, shows that IRAs, especially IRLs, are associated with certain morphology specific to clinical settings, and that the morphology and severity of stenosis could change in a short period. The present results may improve coronary cineangiography interpretation about pathophysiological issues *in vivo* affecting coronary circulation.

J Cardiol 2000; 36(2): 91-102

### Key Words

Angiography      Atherosclerosis      Coronary artery disease  
Myocardial infarction, pathophysiology      Angina pectoris

宮崎医科大学 第一内科: 〒889-1692 宮崎県清武町大字木原 5200

The First Department of Internal Medicine, Miyazaki Medical College, Miyazaki

Address for reprints: KOIWAYA Y, MD, FJCC, The First Department of Internal Medicine, Miyazaki Medical College, Kihara 5200, Kiyotake, Miyazaki 889-1692

Manuscript received January 24, 2000; accepted April 17, 2000

## INTRODUCTION

The primary advantage of coronary cineangiography (CAG) is the depiction of coronary cross-sectional anatomy, and it has therefore been applied to evaluating coronary circulation. In addition to showing the extent and location of narrowing, CAG can also provide diverse *in vivo* pathophysiological information about coronary artery disease<sup>1-30</sup>. Such information includes the following observations. Some types of *in vivo* angiographic coronary morphology reflect histological findings, such as thrombus accumulation with or without underlying ruptured atheromatous plaque or ruptured plaque with or without overlying thrombus<sup>1-15</sup>. These conditions are frequent in patients with patent ischemia- or infarct-related arteries (IRAs), who have acute coronary syndrome at the acute phase or even 1 month after standard medication<sup>7</sup>. Ruptured plaque and overlaid thrombus are also found in patients with acute coronary syndrome who survive as in patients who die as suggested by histological studies<sup>11-19</sup>. Follow-up studies have shown that diseased sites with complex morphology are highly specific to the culprit lesion<sup>9</sup> and tend to progress toward clinical ischemic episodes<sup>20-29</sup>. Coronary stenosis induced by plaque rupture and superimposed thrombus is likely to improve or disappear over time and/or anticoagulant administration with or without antiplatelet therapy<sup>7,9</sup>. If antegrade distal coronary blood flow is not associated with a filling delay, the severity of coronary narrowing immediately after acute coronary syndrome does not influence later left ventricular function<sup>30</sup>.

Using such information<sup>31</sup>, we reviewed CAGs recorded in our institute to determine whether ischemic heart disease is associated with clinically specific CAG findings. For the purpose, we evaluated CAGs and examined whether or not IRAs are associated with characteristic clinical findings, then compared the results with those obtained from non-ischemia- or noninfarct-related arteries (NIRAs).

## PATIENTS AND METHODS

### Patients

We reviewed the records of all patients who underwent CAG studies in our catheterization laboratory from December 1985 to October 1998. Among 834 patients who underwent a CAG study for the first time, 158 who had undergone previous myocardial revascularization procedure before the

study, 88 with valvular disease, 46 with cardiomyopathy and 68 with vasospastic angina were excluded from the analysis. The remaining 474 patients were included in the present analysis; some CAG findings from 83 of the patients were included in previous studies<sup>7-9,22</sup>.

Baseline medical therapy was continued in most patients. The CAG studies were performed because of stable effort angina (SAP), unstable angina (new onset effort angina, spontaneous angina and worsening angina, UAP), acute myocardial infarction (< 1 month after onset, AMI) and old myocardial infarction (≥ 1 month after onset, OMI; **Table 1**).

Ninety-nine patients with AMI or UAP underwent subsequent intracoronary thrombolytic therapy or percutaneous transluminal coronary angioplasty.

### Coronary cineangiography

All CAG studies were performed using Toshiba equipment (ANGIOREX-C, Toshiba Co.) at a film speed of 50 frames per second by either Judkins or Sones technique. CAG analysis was performed using cinefilm viewers (ELK CAP-35B V, Nishimoto Sangyo Co.) by 3 independent observers. After baseline CAG recording, nitrates were administered to all patients to minimize the effects of coronary vasomotor tone on coronary luminal diameter size.

IRA was defined as an artery originally perfusing the area fulfilling at least 2 of the following: an area distal to the lesion on a specific coronary artery compatible with the distribution of transient or persistent ischemic ST changes on a 12-lead electrocardiography, transient or persistent asynergic area on two-dimensional echocardiography and/or left ventriculography, and an area with tracer accumulation by technetium-99m pyrophosphate or with a transient or persistent perfusion defect detected by thallium-201 scintigraphy<sup>22</sup>. When the possible presence of significant narrowings was shown after exercise test on more than 2 arteries in patients with SAP, the specific one originally perfusing the most severely ischemic area was defined as the IRA. An identifiable ischemia- or infarct-related coronary lesion (IRL) was defined as accompanied by complete occlusion, complex morphology or the most severe stenosis<sup>9</sup>.

We specifically focused on intraluminal morphology, including luminal diameter and intraluminal radiolucency, as well as the luminal outline on

**Table 1 Patient characteristics**

	SAP (n = 71)	UAP (n = 72)	AMI (n = 118)	OMI (n = 137)
Mean age( yr, range )	62.1 ± 9.1( 33 - 78 )	62.6 ± 10.4( 36 - 83 )	59.8 ± 11.2( 31 - 73 )	59.0 ± 9.7( 31 - 78 )
Male	54( 76.1% )	60( 83.3% )	102( 86.4% )	107( 78.1% )
Therapy with anticoagulant or fibrinolytic agents	7( 9.9% )	40( 55.6% ) <sup>*#</sup>	35( 30.0% ) <sup>*</sup>	75( 54.7% ) <sup>*#</sup>
Cath time( day )	432.6 ± 702.6	35.1 ± 26.0 <sup>*</sup>	8.7 ± 12.1 <sup>*</sup>	84.8 ± 204.6 <sup>*</sup>

Continuous values are mean ± SD. <sup>\*</sup> *p* < 0.05 vs patients with SAP, <sup>#</sup> *p* < 0.05 vs patients with AMI. Anticoagulant or fibrinolytic agents : Anticoagulant agent, or fibrinolytic and subsequent anticoagulant agents. Cath time : Ensuing time between the first ischemic episode or development of unstable angina, or myocardial infarction and coronary angiography. SAP = stable effort angina pectoris ; UAP = unstable angina pectoris ; AMI = acute myocardial infarction ; OMI = old myocardial infarction.

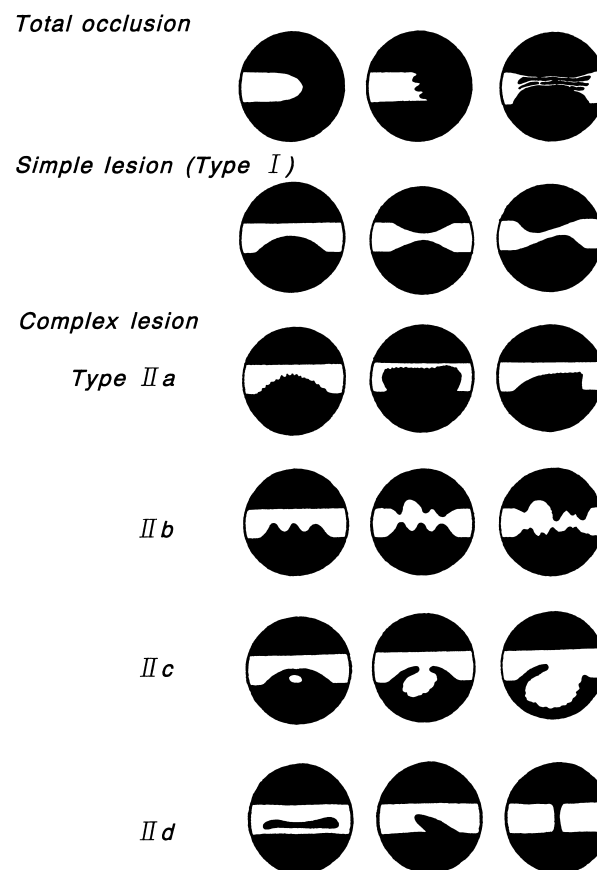
CAG, so that the spatial structure of the coronary lesions could be reconstructed<sup>7-9, 22, 31</sup>). Intraluminal diameter stenosis of all lesions was quantified in orthogonal views using a digital analysing system ( CAM-1000, Nishimoto Sangyo Co. ). Intraluminal stenosis in a lesion consisting of 2 or more closely spaced serial narrowings and accompanied by diffuse luminal irregularities or a ribbon lesion was determined based upon the most severe site.

**Coronary angiographic morphology**

Stenotic lesions with a 50% reduction or more on the major coronary branches were tabulated. In addition, based upon the agreed interpretations of all observers, angiographic morphology at the diseased sites was classified as total occlusion or variable degrees of luminal narrowing. The narrowed sites occasionally manifested variable negative images or radiolucency protruding into the coronary lumen( endoluminal negative images ). All forms of narrowing that showed concentricity or symmetry, haziness, or irregularity of the luminal outline and definite outpouching, were included in the group of patent lesions. Furthermore, the lesions were categorized as total occlusion, and as simple or complex lesions based on angiographic morphology. The complex lesions were further subdivided as follows( **Fig. 1** ).

**1 ) Total occlusion**

A totally occlusive lesion with no distal opacity caused by antegrade contrast flow( Thrombolysis in Myocardial Infarction grade 0 and 1 )<sup>32</sup> and with various forms of the distal end, or associated with multiple and tortuous channels that were quite small and close together.



**Fig. 1 Schematic coronary morphology at the diseased sites**

Morphology was classified as total occlusion, and simple( Type I lesion ) or complex( Type II lesion ). Complex lesions were subdivided into Type II a - d lesions.

**Table 2** Angiographic findings

	SAP (n = 71)	UAP (n = 72)	AMI (n = 118)	OMI (n = 137)
Number of diseased vessels				
One	36(50.7)	35(48.6)	70(59.3)	64(46.7)
Two	26(36.6)	26(36.1)	35(29.7)	55(38.7)
Three	9(12.7)	11(15.3)	13(11.0)	20(14.6)
Identifiable IRAs	71	72	118	137
Number of significant lesions	118	98	168	198
Totally occluded vessel	17(23.9)	7(9.7)	48(40.7)	30(21.9)
Mean stenosis(%)	89.4 ± 11.0	92.0 ± 11.9*	93.1 ± 11.2*	87.4 ± 14.4
Mean stenosis on patent IRAs(%)	87.1 ± 10.8	91.2 ± 12.2*#	88.3 ± 12.5*	84.0 ± 14.5
Identifiable NIRAs	22	34	36	62
Number of significant lesions	29	41	48	78
Totally occluded vessel	0	1(2.9)	0	0
Mean stenosis(%)	64.5 ± 13.6	66.2 ± 13.7	64.4 ± 15.4	67.6 ± 12.0

Continuous values are mean ± SD. ( ) %. \*  $p < 0.05$  vs patients with OMI, #  $p < 0.05$  vs patients with SAP. IRAs = ischemia- or infarct-related arteries; NIRAs = nonischemia- or noninfarct-related arteries with significant stenotic lesion (  $\geq 50\%$  ). Other abbreviations as in Table 1.

## 2) Simple and complex lesions

Simple lesion (Type 1 lesion): Luminal narrowing resulting from endoluminal negative images with smooth borders and broad necks (Type 1 lesion). Complex lesion (Type 2 lesion) were further divided into 4 subgroups, which were defined as follows (Type a - d lesions).

Type a lesion: Luminal narrowing caused by negative images with irregular, poorly defined or hazy borders, with sharp leading or trailing edges that either overhung or were perpendicular to the vessel walls<sup>4,5</sup>. "Intracoronary thrombus" was included in this category. The presence of thrombus was judged by globular endoluminal negative images surrounded by contrast material.

Type b lesion: Two or more closely spaced serial narrowings. This category included "ulcerative lesions" characterized by focal external eversion or protrusion of contrast medium in the diseased segment. This classification also included diffuse luminal irregularities<sup>1,6</sup>.

Type c lesion: Luminal narrowing with ellipsoid contrast pooling adjacent to the diseased portion, so-called "extraluminal contrast pooling", single or paired short thin linear radiolucency with or without a variable degree of outpouching, and definite outpouching with or without radiolucency<sup>7,8,31</sup>.

Type d lesion: Variable forms and grades of

linear or cudgel intraluminal radiolucency caused by membranous or band-like structures. The radiolucent regions may be parallel, spiral, angulated or perpendicular to the vessel wall. This category also included lesions with extraluminal linear opacification parallel to the coronary lumen, some of the opacification being significantly late after contrast injection. A very short lesion with a "napkin-ring" form caused by linear or cudgel intraluminal radiolucency perpendicular to the vessel wall, so-called "ectatic changes" and all other lesions not categorized in totally occlusive, Type 1 or a - c lesions were also included in this type.

## Data analyses

Variables derived from CAG analyses were determined using either the unpaired *t*-test or chi squared test. ANOVA was used to compare data between 3 or more groups. Significance was defined as a *p* value below 0.05. Values are expressed as mean ± SD.

## RESULTS

Eight patients were excluded from the study because of poor film quality, and another 68 were excluded because the IRA could not be determined. Thus, the final study included 398 patients (323 men and 75 women). The number of patients with SAP, UAP, AMI and OMI was 71 (male 54,

76.1% ), 72( male 60, 83.3% ), 118( male 102, 86.4% ) and 137( male 107, 78.1% ), respectively. The mean ages in each group were 62.1, 62.6, 59.8, and 59.0 years, respectively. The time between the first episode of these coronary events and CAG testing in the groups was 432.6, 35.1, 8.7 and 84.8 days, respectively. The clinical profiles in each group are summarized in **Table 1**. Age and gender did not significantly differ between any 2 groups of the 4. However, the use of anticoagulant agent or fibrinolytic and subsequent anticoagulant agents was more common in the patients with UAP and OMI than in those with SAP and AMI. The time between the development of the coronary events and the CAG study was significantly different between all groups.

#### Coronary angiographic findings

The CAG findings in each group are summarized in **Table 2**. There were no significant differences in the number of diseased vessels between the 4 groups. Among patients with SAP, 36( 50.7% ), 26( 36.6% ) and 9( 12.7% ) had disease of one-, 2- and 3-vessels( including left main trunk stenosis ), respectively. Among patients with UAP, 35( 48.6% ), 26( 36.1% ) and 11( 15.3% ) had one-, 2- or 3-vessel disease, respectively. Among the 7 patients with complete occlusion of IRAs, the distal vessels were totally reconstituted through collaterals, and the donor arteries were accompanied by no significant stenosis. Among patients with AMI, 70( 59.3% ), 35( 29.7% ) and 13( 11.0% ) had one-, 2- and 3-vessel disease, respectively. Among patients with OMI, 64( 46.7% ), 55( 38.7% ) and 20( 14.6% ) had one-, 2- or 3-vessel disease, respectively.

Significantly stenotic IRAs were found in 71 patients with SAP, 72 with UAP, 118 with AMI, and 137 with OMI, at 118, 98, 168 and 198 sites, respectively. Seventeen( 23.9% ), 7( 9.7% ), 48( 40.7% ) and 30( 21.9% ) sites were totally occluded at the identifiable IRAs in these groups, respectively.

The mean diameter stenosis at significant sites of identifiable IRLs in these groups was 89.4%, 92.0%, 93.1% and 87.4%, respectively, and that at significant sites of patent identifiable IRLs was 87.1%, 91.2%, 88.3% and 84.0%, respectively. Thus, the intraluminal stenosis on IRLs was more severe in patients with UAP and AMI as compared with that in patients with SAP regardless of the inclusion or exclusion of complete occlusion.

Twenty-nine sites on 22 NIRAs in patients with SAP were significantly stenotic. Similarly, 41, 48 and 78 sites on 34, 36 and 62 NIRAs in patients with UAP, AMI and OMI, respectively, were significantly stenotic. Only one site in patients with UAP was totally occluded. The mean diameter stenosis at the significantly stenotic sites of identifiable NIRAs was 64.5%, 66.2%, 64.4%, and 67.6% in each group. There were no differences in the intraluminal diameter stenosis between the 4 groups, however, the stenosis on the NIRAs was less severe than that on the IRAs.

#### Angiographic morphology of diseased vessels

##### 1) Angiographic morphology at significantly stenotic sites on identifiable ischemia- or infarct-related arteries

Among the significantly stenotic sites at the identifiable IRAs, 17 sites in patients with SAP, 7 with UAP, 48 with AMI and 30 with OMI were determined as identifiable IRLs on the basis of total occlusion, 25 sites in patients with SAP, 54 with UAP, 53 with AMI and 86 with OMI were also identified on the basis of complex morphology, and 29 sites in patients with SAP, 11 with UAP, 17 with AMI, and 21 with OMI were identified on the basis of the severity of occlusion. The morphological findings at the sites of significant stenosis are shown in **Tables 3, 4** and **Fig. 2**.

Of the identifiable IRAs in patients with SAP except for the 17 patients with total occlusion, 29( 40.8% ) sites exhibited Type morphology, 12( 16.9% ) Type a, 8( 11.3% ) Type b, 3( 4.2% ) Type c and 2( 2.9% ) Type d. In patients with UAP, 11( 15.3% ) sites exhibited Type morphology, 34( 47.2% ) Type a, 5( 6.9% ) Type b, 13( 18.1% ) Type c, and 2( 2.8% ) Type d. In patients with AMI, 17( 14.4% ) sites exhibited Type morphology, 38( 32.2% ) Type a, 5( 4.2% ) Type b, 7( 5.9% ) Type c and 3( 2.6% ) Type d. In patients with OMI, 21( 15.3% ) sites exhibited Type morphology, 39( 28.5% ) Type a, 23( 16.8% ) Type b, 20( 14.6% ) Type c, and 4( 2.9% ) Type d. Thus, many IRLs in patients with SAP exhibited Type morphology, representing a significantly higher occurrence than in the other groups(  $p < 0.01$  ). In patients with UAP, many IRLs were accompanied by Type a(  $p < 0.01$  ) and c morphology(  $p < 0.01$  ) at higher frequency than those in patients with SAP. In patients with AMI, total occlusion(  $p < 0.05$  ) and Type a morphology(  $p <$

**Table 3** Angiographic morphology at the sites of ischemia- or infarct-related lesions

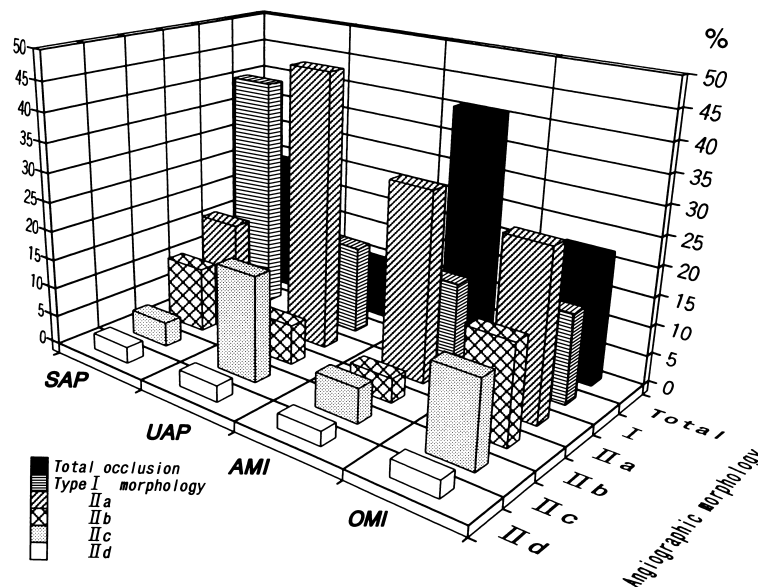
	SAP (n = 71)	UAP (n = 72)	AMI (n = 118)	OMI (n = 137)
Total occlusion	17(23.9)	7(9.7)*	48(40.7)*	30(21.9)
Type	29(40.8)	11(15.3)**	17(14.4)**	21(15.3)**
Type a	12(16.9)	34(47.2)**	38(32.2)*	39(28.5)*
Type b	8(11.3)	5(6.9)	5(4.2)	23(16.8)
Type c	3(4.2)	13(18.1)**	7(5.9)	20(14.6)*
Type d	3(2.9)	3(2.8)	3(2.6)	4(2.9)

( ) %. \*  $p < 0.05$  vs patients with SAP, \*\*  $p < 0.01$  vs patients with SAP. Types and a-d, see text for details. Abbreviations as in Table 1.

**Table 4** Angiographic morphology at the sites of nonischemia-related lesions on nonischemia-related arteries

	SAP (n = 22)	UAP (n = 34)	AMI (n = 36)	OMI (n = 62)
Total occlusion	0	1(2.9)	0	0
Type	18(81.8)	28(82.4)	32(88.8)	48(77.4)
Type a	2(9.1)	1(2.9)	2(5.6)	8(12.9)
Type b	2(9.1)	2(5.9)	2(5.6)	4(6.5)
Type c	0	2(5.9)	0	2(3.2)
Type d	0	0	0	0

( ) %. Types and a-d, see text for details. Abbreviations as in Table 1.



**Fig. 2** Prevalence of angiographic morphology at sites of identifiable ischemia- or infarct-related coronary lesion in variable coronary heart disease. SAP, UAP, AMI and OMI are composed of 71, 72, 118 and 137 patients, respectively. Total, I, and a-d indicate total occlusion, Type I simple lesion and Type II a-d complex lesions, respectively. Abbreviations as in Table 1.

0.01) at higher frequency coincided, whereas patients with OMI had a higher occurrence of Type a ( $p < 0.05$ ) and c morphology ( $p < 0.05$ ) than those with SAP. Comparison of the lesion morphology in patients with AMI and OMI showed total occlusion was less frequent in those with OMI, Type a lesions occurred at the same frequency, and the occurrence of Type b and c lesions was higher in those with OMI.

## 2) Angiographic morphology at significantly stenotic sites on the identifiable nonischemia- or noninfarct-related arteries

Of the 154 significantly stenotic sites at the identifiable NIRAs in patients with SAP, Type morphology occurred most frequently at 18 (81.8%) sites, whereas Types a, b and c were found only on 2 (9.1%), 2 (9.1%) and 0 sites, respectively (Table 4). In patients with UAP, one (2.9%) site was totally occluded, 28 (82.4%) sites exhibited Type morphology and 2 (5.9%) showed Type c. In patients with AMI, 32 (88.8%) sites exhibited Type morphology, but 0 sites showed c. In patients with OMI, 48 (77.4%) sites showed Type morphology, 8 (12.9%) Type a, 4 (6.5%) Type b, and 2 (3.2%) Type c. Type d morphology was undetectable in all groups. Thus, almost 80% of significantly stenotic sites on NIRAs were accompanied by Type morphology, but the occurrence of each subgroup of Type morphology did not significantly differ regardless of clinical background.

## DISCUSSION

CAG is the accepted procedure to evaluate coronary circulation. However, CAG provides only a silhouette of the internal edges of coronary arteries and the information obtained is rather limited. Because of these methodological restrictions, it appears that interpretation of CAG findings has mainly focused on the extent and location of coronary artery disease.

However, several studies have suggested that CAG includes and can provide considerable pathophysiological information<sup>1-24</sup>). Through serial observation of CAGs before, during and after intracoronary urokinase therapy, we have demonstrated recanalization and/or reduction in luminal narrowing at the site of occlusion, as well as the frequent development of morphological features suggesting ruptured atheromatous plaque with adherent thrombus<sup>7</sup>). Subsequently, we attempted to record CAGs

in multiple projections. When interpreting CAG findings, we focused upon the following. The findings may occasionally be dynamic in nature, and the morphology and severity of stenosis could change in a period shorter rather than that anticipated, and thus angiographic profiles merely represent vascular lesions only at a specific point in time. Meanwhile, it is shown that thrombotic occlusion can develop at sites with plaque erosion but not with plaque rupture<sup>33,34</sup>). On this occasion, plaque erosion was defined as an acute thrombus in direct contact with the intimal plaque without rupture of the lipid pool<sup>33,34</sup>).

One key goal of the present study was to try to define whether or not various coronary heart diseases have specific CAG findings associated with clinical settings. Based on the above observations<sup>31</sup>), we reviewed the CAGs recorded between December 1985 and October 1998 at our institute. We initially obtained intensive records of CAGs that focused on diseased sites in multiple projections from 1985. To avoid the influence of treatment, CAGs from patients with prior revascularization procedures were excluded from the present review. The CAGs from patients with variant angina were also excluded because of the difficulty in confirming the IRA, IRL and the complete elimination of vasospasm.

## Angiographic morphology of coronary arteries at diseased sites and classification

In the present analysis, we attempted to establish a classification applicable to serial observations along a time course, to reveal how the morphology and the severity of occlusive lesions can change and how the time course can be modified by pharmacological intervention. Therefore, we revised the classification of the morphology at diseased sites<sup>7,9,22</sup>) based on recent observations<sup>31</sup>), in which diseased sites are graded as total occlusion, or as simple and complex lesions (Fig. 1). Complex lesions were subdivided according to the increasing likelihood of ruptured plaque or adhering thrombus. The criteria for the present classification do not include concentricity or symmetry of the stenotic sites because of the difficulties in determining such features in individual lesions. Furthermore, culprit stenoses even in UAP are not necessarily eccentric<sup>11</sup>).

The Type a complex lesion is probably indicative of thrombus accumulation with or without

underlying ruptured atheromatous plaque<sup>4,5</sup>), although to our knowledge, this has not been correlated with histological findings. Many investigators and clinicians appear to refer to some Type b and c complex lesions in the present classification as “ulcerated plaques or lesions”. However, lesions that may be easily interpreted as “ulcerated plaques or lesions” may have focal eversion or outpouching of contrast medium at diseased sites<sup>1</sup>) (Fig. 1). In the present study, lesions with focal protrusions of contrast medium in a segment with 2 or more closely spaced serial narrowings, or having diffuse luminal irregularities, were classified as Type b lesions. This was because of the following reasons. Type b and c lesions were more frequently associated with a smaller amount of thrombi when compared with Type a lesions. Type c lesions were more often accompanied by ruptured atheromatous plaque than Type b lesions<sup>6,9</sup>). These findings may indicate that the natural history of the morphology and the luminal cross-sectional area differs between Type b and c lesions.

All other lesions, not classified in simple or complex lesions of Types a - c, were included in Type d category, since they appeared to occur less frequently. The angiographic definitions for each lesion in this category should be standardized when a large number of patients are analyzed by histopathological correlation. For example, many clinicians may interpret apparent intraluminal radiolucency or endothelial discontinuity as “dissection”, but histologically, it is simply defined as tears or fractures that penetrate the vessel media<sup>35</sup>).

#### Patency, severity and morphology of diseased sites

Total occlusion was more frequent in IRAs than in NIRAs, with the frequency increasing in the order of AMI, OMI, SAP, UAP (Table 3, Fig. 2). The severity of stenosis in IRAs was about 90%, which was significantly higher than that in NIRAs. Simple lesions were found in over 40% of IRAs in SAP, whereas Type a lesions were prevalent in patients with UAP, AMI and OMI in increasing order of frequency. Type a lesions may have been associated with thrombus regardless of the presence of underlying ruptured atheromatous plaque<sup>4,5</sup>). Type b lesions were most prevalent in patients with OMI, whereas Type c complex lesions predominated in patients with UAP and OMI. Some of the Type b and c lesions may have been accom-

panied by ruptured atheromatous plaque with or without overlying thrombus. Thus, the present *in vivo* findings are compatible with those from previous histological studies, which demonstrated that ruptured atheromatous plaque and overlaid thrombus occasionally plays an important role in the development of acute coronary syndrome<sup>16-19</sup>). However, the occurrence of thrombus formation may be affected by other factors, such as whether or not the patient has received anticoagulation prior to catheterization, the duration of anticoagulation and the timing of the CAG study relative to the onset and ensuing time after the development of unstable angina or the last episode of chest pain at rest.

We do not understand the role of the Type c lesion in UAP. The diseased sites with Type c morphology could have been severely or totally occluded during the active phase by superimposed thrombus, inducing UAP with severe stenosis and followed by a decrease over a short period. Some sites representing such morphology, however, could not be associated with much thrombi during the active phase, only releasing plaque contents and a small amount of thrombus<sup>7-9</sup>).

The role of the complex morphology in NIRAs (Table 4) also remains unclear, and we can only comment briefly on its pathophysiological role. Most sites were repaired without any significant reduction of coronary blood flow leading to myocardial necrosis<sup>9</sup>).

#### Limitations of the present study

Coronary angiographic resolution, and possible incompatibility between the coronary morphology and histological findings are limitations of the present study. In addition, the study group may have included some bias, because only patients obliged to undergo a CAG study were recruited. The retrospective nature of the investigation may also be limited by the reliability or credibility of the findings. Long intervals among the patients may also be a cause for concern.

CAG findings are based on indirect estimates of luminal narrowing, which accounts for significant limitations in the detection of narrowing and assessing the severity of the lesion. To determine the latter, the minimal luminal narrowing at a stenotic site is compared to an adjacent, presumably “normal” reference segment. However, pathological studies have revealed that coronary



atherosclerosis is usually diffuse<sup>36</sup>), and that diffusely diseased vessels often do not have a truly normal segment from which the percentage stenosis can be calculated. As a result, the angiographic estimation of percentage luminal reduction or cross-sectional area may often underestimate lesion severity<sup>37</sup>).

Some vessel walls around atherosclerotic sites may be undergo compensatory enlargement or "remodeling", preserving the lumen diameter or cross-sectional area, and the angiographical lumen size or luminal diameter, so apparently remain unchanged<sup>38</sup>). Despite imaging by multiple projections, it may be difficult to reveal the presence of stenotic lesions at coronary ostia and bifurcations, and some lesions are occasionally apparent only in a single projection<sup>37</sup>). Subsequently, even when such measurements taken at diseased sites are computer-assisted, significant problems remain such as magnification errors and the adequacy of the projections taken. On the other hand, the real stenosis of the intraluminal diameter is hardly measurable even in necropsy specimens, since these vessels are collapsed and do not preserve a physiological luminal diameter<sup>39</sup>).

Morphology at the diseased sites may be quite difficult to determine, because CAG fills the lumen with contrast medium and portrays a complex three-dimensional coronary anatomy as a pale planar silhouette. This is also due to the lack of a standardized angiographic definition of coronary morphology. For example, the diagnosis of an intracoronary thrombus among complex lesions is by no means definite. The presence of thrombus is defined in the present study by globular endoluminal negative images surrounded by contrast material. However, some severely eccentric and stenotic lesions, or calcified lesions may be accompanied by such findings. Thus, some sites with Type b and c morphology might be misinterpreted as "ulceration with or without adherent thrombus". Furthermore, the detection of thrombus may depend upon several factors, as described above. In the present study, 7 totally occlusive sites in the 7 patients with UAP were determined as IRLs, since all arteries providing collaterals were associated with no significant stenosis, however, we should note that completely occlusive sites are not necessarily the culprit lesions.

Another major limitation can be attributed to the fact that the morphology in each lesion does not

always match a comparable histopathological finding. Thus, what each lesion actually represents remains to be clarified. However, we did confirm that the Type c lesion histologically implicated ruptured plaque in 2 patients, which we described in 2 previous reports<sup>7,8</sup>). In addition, at least 25 of the 43 patients with AMI who were included in both our previous<sup>7</sup>) and present studies may have been associated with ruptured atheromatous plaque and superimposed thrombus. In the previous study<sup>7</sup>), we observed the development of Type c morphology in the 25 patients as follows: an intracoronary infusion of urokinase progressively removes the overlying thrombus and plaque content, thereby induces recanalization and/or a reduction in luminal narrowing at the site of the occlusion. Subsequent continuous and longitudinal observations of coronary angiographic morphology and qualitative analyses of comparable necropsy specimens will further address these issues.

#### Clinical implications

Based on the present findings, the CAG findings could occasionally be dynamic in terms of the morphology, severity of stenosis and clinical manifestations. In other words, CAG findings are changing within a shorter period than was previously anticipated, and simply reflect the angiographic profiles of individuals at the time point of a CAG study. Thus, the severity of the luminal diameter could progress or even regress over a short period, especially at diseased sites with a complex morphology<sup>20-29</sup>). When severe stenoses developed at previously mildly occlusive sites, many of these sites might have been associated with a complex histological structure such as ruptured atheromatous plaque too small to be detected by CAG, or with unstable but not ruptured plaque. Thrombotic occlusion can also develop at sites with plaque erosion but not with plaque rupture<sup>33,34</sup>).

A definite relationship between CAG findings and "coronary artery disease" has not yet been established, possibly because of the broad spectrum of patients with coronary artery occlusion and because a wide variety of causal diseases are included in a single diagnosis of "coronary artery disease". The lack of a definite relationship is also attributable to the types of studies performed, the patient populations involved and the applied definitions.

The time interval between the onset of symptoms

and the CAG study may also be critical, since CAG studies are often performed long after the first symptoms manifest. Regardless of such limitations, CAG is applied widely to evaluate coronary circulation, and is routinely performed in many institutes and hospitals to get important information for the planning of a treatment strategy.

Diseased sites with complex morphology are occasionally found in patent IRAs 1 month after acute coronary syndrome in patients receiving standard medication except for thrombolytic agents<sup>9</sup>). Moreover, such sites are highly specific to the culprit lesion<sup>9</sup> and the diseased sites with complex morphology tend to progress toward clinical ischemic episodes<sup>20-29</sup>). Again, to clarify what each morphology actually represents, how the morphology changes over time and how these changes are

modified by pharmacological intervention, subsequent serial or longitudinal observations using intravascular angioscopic and ultrasonic procedures and histological correlation are required. Under such conditions, CAG studies may help to improve understanding of the *in vivo* pathophysiology in each patient as well as "coronary artery disease".

Despite various limitations and pitfalls, CAG is essential for the diagnosis and management of patients with "coronary artery disease". When the criteria are further refined to provide a more detailed classification correlating each CAG finding to a histopathological condition, CAG studies will deliver more therapeutic information regarding the pathophysiology of coronary circulation as well as the choice of optimal therapeutic strategies for individual patients.

## 要 約

### 虚血性心疾患における造影上の冠動脈病変形態の検討

名越 敏郎 小岩屋 靖 土居 英生 江藤 胤尚

目的: 心筋梗塞や心筋虚血の責任病変は, 冠動脈造影上, 各病型によって特有な形態を有するか, また, 病期によって相異があるかを検討した. 対象は安定労作狭心症 71 例, 不安定狭心症 72 例, 急性心筋梗塞(発症 1 ヶ月以内) 118 例, 陳旧性心筋梗塞(発症 1 ヶ月以上) 137 例の計 398 例である.

方法: 有意狭窄部の形態を完全閉塞(TO), 単純病変(Type )および複雑病変(Type )に分け, Type 病変はさらに haziness や overhang を伴い血栓が付着しているとされるもの(a), multiple irregularity を伴うもの(b), 円形の管腔外造影剤貯留や outpouching を伴う破裂粥腫の一部が描出されていると思われるもの(c), その他(d)に分類した.

結果: 責任病変の狭窄率は, 安定労作狭心症で 89.4%, 不安定狭心症で 92.0%, 急性心筋梗塞で 93.1%, 陳旧性心筋梗塞で 87.4% であった. 病変形態は TO, a, b, c, d の順に, 安定労作狭心症ではそれぞれ 17(23.9%), 29(40.8%), 12(16.9%), 8(11.3%), 3(4.2%), 2(2.9%) であり, 不安定狭心症では 7(9.7%), 11(15.3%), 34(47.2%), 5(6.9%), 13(18.1%), 2(2.8%), 急性心筋梗塞では 48(40.7%), 17(14.4%), 38(32.2%), 5(4.2%), 7(5.9%), 3(2.6%), 陳旧性心筋梗塞では 30(21.9%), 21(15.3%), 39(28.5%), 23(16.8%), 20(14.6%), 4(2.9%) であった. 安定労作狭心症では他群に比べて a が有意に多く( $p < 0.01$ ), 不安定狭心症では安定労作狭心症に比べて a ( $p < 0.01$ ), c ( $p < 0.01$ ) が, 急性心筋梗塞では TO ( $p < 0.01$ ), a ( $p < 0.05$ ) が, 陳旧性心筋梗塞では c ( $p < 0.05$ ) が高頻度であった. 非責任病変の狭窄形態は各群とも a が多く, 疾患群間の頻度に差を認めなかった.

結論: 以上のように, 責任病変の形態は病型により特有な所見を示し, また, 病期により変化することが示された. これらを認識して冠動脈造影を解析することにより, 当該症例の病態の解釈が容易になると思われる.

References

- 1) Rösch J, Antonovic R, Trenouth RS, Rahimtoola SH, Sim DN, Dotter CT: The natural history of coronary artery stenosis: A longitudinal angiographic assessment. *Radiology* 1976; **119**: 513 - 520
- 2) Levin DC, Fallon JT: Significance of the angiographic morphology of localized coronary stenosis: Histopathologic correlations. *Circulation* 1982; **66**: 316 - 320
- 3) Levin DC, Gardiner GA Jr: Complex and simple coronary artery stenosis: A new way to interpret coronary angiograms based on morphologic features of lesion. *Radiology* 1987; **164**: 675 - 680
- 4) Ambrose JA, Winters SL, Arora RR, Haft JI, Goldstein J, Rentrop KP, Gorlin R, Fuster V: Coronary angiographic morphology in myocardial infarction: A link between the pathogenesis of unstable angina and myocardial infarction. *J Am Coll Cardiol* 1985; **6**: 1233 - 1238
- 5) Ambrose JA, Israel DH: Angiography in unstable angina. *Am J Cardiol* 1991; **68**: 78B - 84B
- 6) Wilson RF, Holida MD, White CW: Quantitative angiographic morphology of coronary stenoses leading to myocardial infarction or unstable angina. *Circulation* 1986; **73**: 286 - 293
- 7) Nakagawa S, Hanada Y, Koiwaya Y, Tanaka K: Angiographic features in the infarct-related artery after intracoronary urokinase followed by prolonged anticoagulation: Role of ruptured atheromatous plaque and adherent thrombus in acute myocardial infarction in vivo. *Circulation* 1988; **78**: 1335 - 1344
- 8) Unoki T, Nakagawa S, Koiwaya Y, Tanaka K: Extra-luminal contrast pooling on coronary angiography as an expression of ruptured atheromatous plaque. *Am Heart J* 1989; **117**: 1159 - 1161
- 9) Hanada Y, Koiwaya Y, Tanaka K: Coronary angiographic findings in infarct-related arteries following 1 month of medical treatment. *Cardiovasc Intervent Radiol* 1994; **17**: 87 - 94
- 10) Falk E, Shah PK, Fuster V: Coronary plaque disruption. *Circulation* 1995; **92**: 657 - 671
- 11) Falk E, Fuster V: Angina pectoris and disease progression. *Circulation* 1995; **92**: 2033 - 2035
- 12) DeWood MA, Spores J, Notske R, Mouser LT, Burroughs R, Golden MS, Lang HT: Prevalence of total coronary occlusion during the early hours of transmural myocardial infarction. *N Engl J Med* 1980; **303**: 897 - 902
- 13) Capone G, Wolf NM, Meyer B, Meister SG: Frequency of intracoronary filling defects by angiography in angina pectoris at rest. *Am J Cardiol* 1985; **56**: 403 - 406
- 14) Brown BG, Gallery CA, Badger RS, Kennedy JW, Mathey D, Bolson EL, Dodge HT: Incomplete lysis of thrombus in the moderate underlying atherosclerotic lesion during intracoronary infusion of streptokinase for acute myocardial infarction: Quantitative angiographic observations. *Circulation* 1986; **73**: 653 - 661
- 15) de Zwaan C, Bar FW, Janssen JH, de Swart HB, Vermeer F, Wellens HJ: Effects of thrombolytic therapy in unstable angina: Clinical and angiographic results. *J Am Coll Cardiol* 1988; **12**: 301 - 309
- 16) Horie T, Sekiguchi M, Hirosaka K: Coronary thrombosis in pathogenesis of acute myocardial infarction: Histopathological study of coronary arteries in 108 necropsied cases using serial section. *Br Heart J* 1978; **40**: 153 - 161
- 17) Silver MD, Baroldi B, Mariani F: The relationship between acute occlusive coronary thrombi and myocardial infarction studied in 100 consecutive patients. *Circulation* 1980; **61**: 219 - 227
- 18) Falk E: Plaque rupture with severe pre-existing stenosis precipitating coronary thrombosis: Characteristics of coronary atherosclerotic plaques underlying fatal occlusive thrombi. *Br Heart J* 1983; **50**: 127 - 134
- 19) Davies MJ, Thomas AC: Plaque fissuring: The cause of acute myocardial infarction, sudden ischaemic death, and crescendo angina. *Br Heart J* 1985; **53**: 363 - 373
- 20) Ellis S, Alderman EL, Cain K, Wright A, Bourassa M, Fisher L: Morphology of left anterior descending coronary territory lesions as a predictor of anterior myocardial infarction: A CASS Registry Study. *J Am Coll Cardiol* 1989; **13**: 1481 - 1491
- 21) Rehr R, Disciasco G, Vertovec G, Cowley M: Angiographic morphology of coronary artery stenoses in prolonged rest angina: Evidence of intracoronary thrombosis. *J Am Coll Cardiol* 1989; **14**: 1429 - 1437
- 22) Nagatomo Y, Nakagawa S, Koiwaya Y, Tanaka K: Coronary angiographic ruptured atheromatous plaque as a predictor of future progression of stenosis. *Am Heart J* 1990; **119**: 1244 - 1253
- 23) Nagatomo Y, Nakagawa S, Koiwaya Y, Tanaka K: Progression of coronary stenosis (Letter). *Am Heart J* 1991; **121**: 1842 - 1843
- 24) Myler RK, Shaw RE, Stertz SH, Bashour TT, Ryan C, Hecht HS, Cumberland DC: Unstable angina and coronary angioplasty. *Circulation* 1990; **82** (Suppl): 88 - 95
- 25) Chen L, Chester MR, Redwood S, Huang J, Leatham E, Kaski JC: Angiographic stenosis progression and coronary events in patients with 'stabilized' unstable angina. *Circulation* 1995; **91**: 2319 - 2324
- 26) Kaski JC, Chester MR, Chen L, Katritsis D: Rapid angiographic progression of coronary artery disease in patients with angina pectoris: The role of complex stenosis morphology. *Circulation* 1995; **92**: 2058 - 2065
- 27) Chester MR, Chen L, Tousoulis D, Poloniecki J, Kaski JC: Differential progression of complex and smooth stenoses within the same coronary tree in men with stable coronary artery disease. *J Am Coll Cardiol* 1995; **25**: 837 - 842
- 28) Cox ID, Schwartzman RA, Atenza F, Brown SJ, Kaski JC: Angiographic progression in patients with angina pectoris and normal or near normal coronary angiograms who are restudied due to unstable symptoms. *Eur Heart J* 1998; **19**: 1027 - 1033
- 29) Yokoya K, Takatsu H, Suzuki T, Hosokawa H, Ojio S, Matsubara T, Tanaka T, Watanabe S, Morita N, Nishigaki K, Takemura G, Noda T, Minatoguchi S, Fujiwara H: Process of progression of coronary artery lesions from mild or moderate stenosis to moderate or severe stenosis: A study based on four serial coronary arteriograms per year. *Circulation* 1999; **100**: 903 - 909
- 30) Fukunaga T, Hanada Y, Koiwaya Y, Eto T: The severity of residual coronary stenosis immediately after thrombolytic therapy does not influence the size of later left ventricular asynergic area. *Clin Cardiol* 1994; **17**: 589 - 595

- 31) Koiwaya Y, Doi H, Nagoshi T, Eto T: Coronary angiography provides considerable in vivo pathophysiological information on coronary artery disease. *J Cardiol* 1998; **32**: 101 - 105
- 32) The TIMI Study Group: The Thrombolysis in Myocardial Infarction (TIMI) trial: Phase II findings. *N Engl J Med* 1985; **312**: 932 - 936
- 33) Burke AP, Farb A, Malcom GT, Liang YH, Smialek J, Virmani R: Coronary risk factors and plaque morphology in men with coronary disease who died suddenly. *N Engl J Med* 1997; **336**: 1276 - 1282
- 34) Arbustini E, Dal Bello B, Morbini P, Burke AP, Bocciaelli M, Specchia G, Virmani R: Plaque erosion is a major substrate for coronary thrombosis in acute myocardial infarction. *Heart* 1999; **82**: 269 - 272
- 35) Zidar JP, Phillips HR, Jackman JD Jr, Stack RS, Labinaz M: Dissection, abrupt closure, and perforation. *in* *Interventional Cardiovascular Medicine. Principles and Practice* (ed by Roubin GS, Calif RM, O'Neill WW, Phillips HR, Stack RS), Churchill Livingstone, New York, 1994; pp 601 - 615
- 36) Roberts W, Jones: Quantitation of coronary arterial narrowing at necropsy in sudden coronary death: Analysis of 31 patients and comparison with 25 control subjects. *Am J Cardiol* 1979; **44**: 39 - 45
- 37) De Fanco AC, Tuzcu EM, Nissen SE: Interventional applications of coronary intravascular ultrasound. *in* *Current Review of Interventional Cardiology* (ed by Topol EJ, Serruys PW), 2nd Ed. Current Medicine, Philadelphia, 1995; pp 173 - 191
- 38) Hermiller JB, Tenaglia AN, Kisslo KB, Phillips HR, Bashore TM, Stack RS, Davidson CJ: In vivo validation of compensatory enlargement of atherosclerotic coronary arteries. *Am J Cardiol* 1993; **71**: 665 - 668
- 39) Nissen SE: Intravascular ultrasound. *in* *The Heart* (ed by Schlant RC, Alexander RW), 8th Ed. McGraw-Hill, New York, 1994; pp 2273 - 2278