

Challenging Case of Pulse Infusion Thrombolysis Using a Unique Pump System for a Patient With Deep Vein Thrombosis: A Case Report

Seiji HOKIMOTO, MD

Taro SAITO, MD, FJCC

Katsuo NODA, MD

Yasushi MORIYAMA, MD

Fumiyuki ISHIBASHI, MD

Keishi MIYATA, MD

Satoshi TAKAYANAGI,

MD

Hide Nobu KOGA, MD

Abstract

A 69-year-old man presented with chronic deep vein thrombosis due to massive thrombi extending from the inferior vena cava to both femoral veins. He had undergone surgery for prostatic cancer in 1991, and since then he had been taking an artificial estrogen agent. He was successfully treated by pulse infusion thrombolysis using a unique pump system, which we have developed, without complication.

J Cardiol 2002 Feb; 39(2): 115-119

Key Words

■Thrombosis (deep vein)

■Thrombolysis

■Pulmonary embolism

INTRODUCTION

Deep vein thrombosis is a commonly observed disorder and sometimes triggers serious complications, but no treatment has been established. Pulse infusion thrombolysis is an effective strategy for the treatment of huge thrombus in artery obstructions. We treated a 69-year-old man with massive deep vein thrombosis by pulse infusion thrombolysis.

CASE REPORT

A 69-year-old man underwent surgery for prostatic cancer in 1991, and since then he had been taking an artificial estrogen agent. He suffered from pain and swelling edema of the bilateral lower

limbs for 2 years. He was hospitalized due to worsening leg pain and dyspnea even at rest in September 1999. Color photography of the swollen lower limbs is demonstrated in **Fig. 1 - upper**. Computed tomography with contrast medium showed occlusion of the lower inferior vena cava and thrombi extending into the bilateral femoral veins. Perfusion lung scanning scintigraphy detected some perfusion defects in the right and left lung fields. These findings indicated deep vein thrombosis and pulmonary thromboembolism. The artificial estrogen agent may have been involved in the etiology.

Based upon the size and duration of the thrombus, pulse infusion thrombolysis treatment was selected. The pulse infusion thrombolysis pump

熊本中央病院 循環器科: 〒862-0965 熊本県熊本市田井島1-5-1

Division of Cardiology, Kumamoto Central Hospital, Kumamoto

Address for correspondence: HOKIMOTO S, MD, Division of Cardiology, Kumamoto Central Hospital, Tainoshima 1-5-1, Kumamoto, Kumamoto 862-0965

Manuscript received September 28, 2001; revised November 9, 2001; accepted November 9, 2001

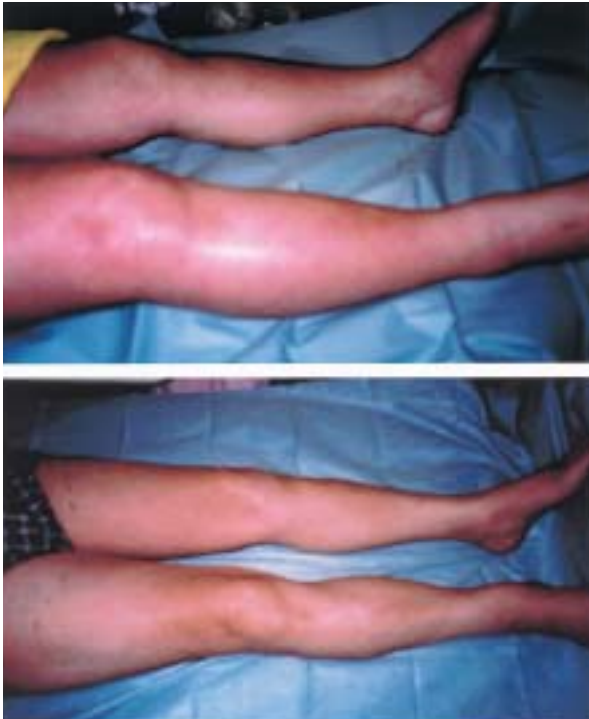


Fig. 1 Color photographs of the patient's lower limbs
Swelling edema before (upper) and after pulse infusion thrombolysis for deep vein thrombosis (lower).

(Nemoto Kyorindo) allows constant forceful delivery of fibrinolytic agent in a spray-like fashion through multiple side holes of the pulse infusion thrombolysis catheter directly into the thrombus (Fig. 2). The pump system also has the advantage that extended times are possible. The detailed system was described before¹⁾. The pulse infusion thrombolysis catheter was a Cragg-McNamara catheter (Micro Therapeutics, Inc.).

A temporary inferior vena cava filter (Neuhaus Laboratories, Inc.) was placed in the proximal inferior vena cava before pulse infusion thrombolysis to inhibit pulmonary thromboembolism. A bolus of heparin (5,000 U) was given through the venous line. The Cragg-McNamara infusion catheter was introduced via a sheath placed in the right jugular vein and passed downward through the filter. After the 0.035 inch radifocus guide wire crossed the thrombus lesion, the pulse infusion thrombolysis catheter was passed from the inferior vena cava to the femoral vein. Pulse infusion thrombolysis (96×10^4 U of urokinase/200 ml of saline) was performed step by step at each site for 10 min (Fig. 3). As reported in our previous study, the injection mode used the following conditions: three injections per min, 0.5 ml bolus at 2 ml/sec forced flow¹⁾. The final venography demonstrated flow restora-




Fig. 2 Pump system

The compact electrically powered pump incorporates a 5 ml syringe. A T-shape one-way valve allows aspiration of thrombolytic agent solution and forced flow into the catheter. Delivery of the drug can be changed in times/min, volume/bolus and forced flow/sec (velocity) to fit the thrombus age, size and stability.

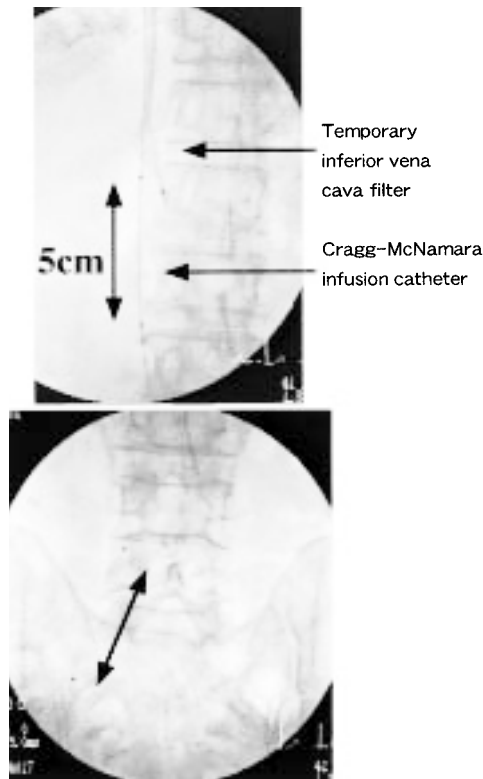


Fig. 3 Photographs of the temporary inferior vena cava filter and Cragg-McNamara infusion catheter used in the first pulse infusion thrombolysis procedure

The Cragg-McNamara infusion catheter was inserted through the sheath into the right jugular vein, and the temporary inferior vena cava filter was delivered from another puncture site of the right jugular vein.

Upper: Level of inferior vena cava. *Lower:* Level of iliac veins.

tion, but a significant amount of thrombus remained after use of the total amount of urokinase ($96 \times 10^4 \text{U}$; **Fig. 4**) There was no symptom of dyspnea and no findings of hematoma, pulmonary infarction, or worsening of oxidization.

One week after the first procedure, repeat venography showed slow flow and persistent thrombus in the iliac to femoral veins. Second pulse infusion thrombolysis therapy using $48 \times 10^4 \text{U}$ of urokinase was performed in a similar way. As shown in **Fig. 5**, final venography showed constant flow from the bilateral iliac to femoral veins. However, venography of the inferior vena cava showed thin flow (**Fig. 5 - D**), so flow recovery was possibly not sufficient. Physical examination showed dramatic improvement of symptoms and concordant normalized extremities (**Fig. 1 - lower**) A few days later, a permanent venous filter was placed and anticoagulant therapy was started. There was no recurrence of deep vein thrombosis.

DISCUSSION

Pulse infusion thrombolysis lyses thrombi by the synergetic mechanisms of mechanical maceration of the thrombus by direct spray-like delivery of thrombolytic solution into the thrombus and the lytic mechanism of the agent. Fibrinolytic acceleration by pulse infusion thrombolysis was confirmed experimentally^{2,3}). We have used pulse infusion thrombolysis for acute myocardial infarction with huge intracoronary thrombus and early vein graft occlusion after coronary artery bypass surgery.

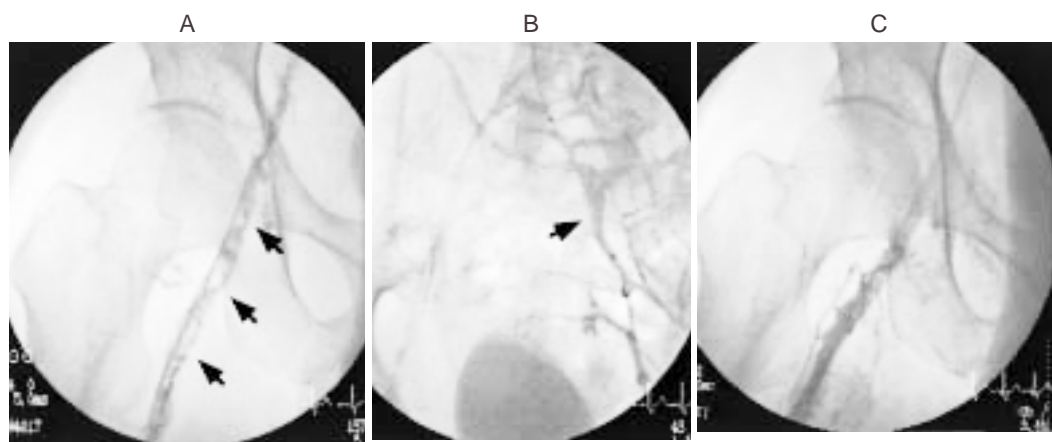


Fig. 4 Venographs after the first pulse infusion thrombolysis therapy

A: Residual thrombus (arrows) is present in the right iliac to femoral veins, after administration of urokinase $48 \times 10^4 \text{U}$. *B:* Flow recovery of the left iliac vein (arrow). *C:* Final venograph of the right iliac to femoral veins after use of urokinase $96 \times 10^4 \text{U}$ shows few residual thrombi.

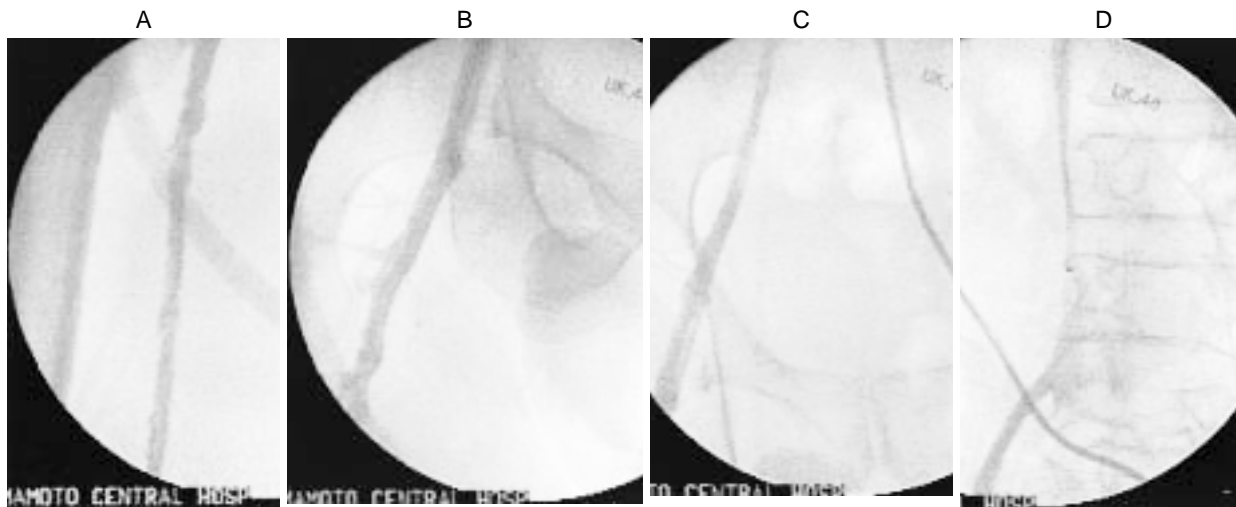


Fig. 5 Venographs after the second pulse infusion thrombolysis therapy

A, B, C and D show flow recovery of the right femoral and iliac veins and the inferior vena cava, respectively.

Hemodialysis shunt obstruction can be successfully recanalized in more than 90% of cases by pulse infusion thrombolysis⁴⁻⁶.

Deep vein thrombosis is an uncommon and elusive illness that can result in suffering and death if not recognized and treated effectively. The strategy for deep vein thrombosis is classified by its status, onset time, or clinical course^{7,8}. In this case, pulmonary embolism had occurred and the patient was suffering from dyspnea and needed analgesic agents to relieve leg pain and could not walk. Furthermore, the occluded section of the inferior vena cava was long and intravenous thrombus was considered to be partially organized. Based on our experience of vein graft thrombus occlusion, we thought that pulse infusion thrombolysis was the best treatment strategy for this particular case of deep vein thrombosis.

Experimental pulse spray thrombolysis with tissue plasminogen activator is effective for the treatment of rabbit inferior vena cava thrombosis, and pulse spray thrombolysis is superior to only intravenous injection of thrombolytic agent⁹. Moreover, by changing the setting of pulse frequency, concentration and amount of thrombolytic agent, compli-

cations including hematoma and bleeding requiring blood transfusion can be reduced. Catheter-directed thrombolysis for deep vein thrombosis is safe and effective and the mean infusion time of urokinase through the catheter is 53 hr¹⁰. This infusion time is too long. Thus, considering that complete flow restoration time in patients with peripheral ischemia was shorter in pulse spray thrombolysis than in conventional treatment¹¹, the pulse infusion thrombolysis technique may reduce the procedural time and total amount of thrombolytic agent. In the present case, urokinase of 96×10^4 U was used in the first and 48×10^4 U in the second procedure and the time was about 2 hr for each treatment. Therefore, the pulse infusion thrombolysis technique using a special pump system reduced the amount of thrombolytic agent and the procedure time.

We concluded that catheter-directed pulse infusion thrombolysis using a pump system for deep vein thrombosis is safe and effective.

Acknowledgments

We are grateful to Namiko Sakamoto and Eiko Kikuchi for their assistance with collecting the data.

要 約

深部静脈血栓症に対し特殊ポンプを用いたパルススプレー血栓溶解療法により
再疎通が得られた1症例

掃本 誠治 斉藤 太郎 野田 勝生 森山 泰 石橋 史之
宮田 敬士 高柳 聡 古賀 英信 大嶋 秀一

症例は69歳，男性．1991年に前立腺癌で摘出術が施行され，合成エストロゲン薬を投与されていた．1999年9月に下肢の腫脹増悪と，息切れで当科紹介となる．診断の結果，下大静脈下部から大腿静脈まで血栓性に閉塞した深部静脈血栓症であり，大量の血栓であることを考えると，通常の血栓溶解薬投与では血流再開は困難と考え，我々が開発した特殊ポンプ機器を用いたパルススプレーによる血栓溶解療法を施行した．その後，ウロキナーゼと一時的な下大静脈フィルターを併用し，合併症なく安全に再疎通が得られた．大量の血栓性閉塞を呈する血管疾患に対しパルススプレーによる血栓溶解療法は有効と考えられた．

J Cardiol 2002 Feb; 39(2): 115 - 119

References

- 1) Saito T, Taniguchi I, Nakamura S, Oka H, Mizuno Y, Noda K, Yamashita S, Oshima S: Pulse-spray thrombolysis in acutely obstructed coronary artery in critical situations. *Cathet Cardiovasc Diagn* 1997; **40**: 101 - 108
- 2) Bookstein JJ, Saldinger E: Accelerated thrombolysis: In vitro evaluation of agents and methods of administration. *Invest Radiol* 1985; **20**: 731 - 735
- 3) Kandarpa K, Drinker PA, Singer SJ, Caramore D: Forceful pulsatile local infusion of enzyme accelerates thrombolysis: In vivo evaluation of a new delivery system. *Radiology* 1988; **168**: 739 - 744
- 4) Bookstein JJ, Fellmeth B, Roberts AC, Valji K, Davis G, Machado T: Pulsed-spray pharmacomechanical thrombolysis: Preliminary clinical results. *Am J Roentgenol* 1989; **152**: 1097 - 1100
- 5) Valji K, Bookstein JJ, Roberts AC, Davis GB: Pharmacomechanical thrombolysis and angioplasty in the management of clotted hemodialysis grafts: Early and late clinical results. *Radiology* 1991; **178**: 243 - 247
- 6) Valji K, Bookstein JJ, Roberts AC, Oglevie SB, Pittman C, O'Neill MP: Pulse-spray pharmacomechanical thrombolysis of thrombosed hemodialysis access grafts: Long-term experience and comparison of original and current techniques. *Am J Roentgenol* 1995; **164**: 1495 - 1500
- 7) Hirsh J, Hoak J, for the Council on Thrombosis (in consultation with the Council on Cardiovascular Radiology), American Heart Association: Management of deep vein thrombosis and pulmonary embolism: A statement for healthcare professionals. *Circulation* 1996; **93**: 2212 - 2245
- 8) Sakakibara Y: Deep vein thrombosis. *Nippon Rinsho* 1999; **57**: 1631 - 1635 (in Jpn with Eng abstr)
- 9) Bookstein JJ, Bookstein FL: Augmented experimental pulse-spray thrombolysis with tissue plasminogen activator, enabling dose reduction by one or more orders of magnitude. *J Vasc Interv Radiol* 2000; **11**: 299 - 303
- 10) Mewissen MW, Seabrook GR, Meissner MH, Cynamon J, Labropoulos N, Haughton SH: Catheter-directed thrombolysis for lower extremity deep venous thrombosis: Report of a national multicenter registry. *Radiology* 1999; **211**: 39 - 49
- 11) Yusuf SW, Whitaker SC, Gregson RH, Wenham PW, Hopkinson BR, Makin GS: Immediate and early follow-up results of pulse spray thrombolysis in patients with peripheral ischaemia. *Br J Surg* 1995; **82**: 338 - 340