

Reversible Subacute Effusive-Constrictive Pericarditis After Correction of Double-Chambered Right Ventricle: A Case Report

Kimihiro TANAKA, MD
Motohiro KAWAUCHI, MD, FJCC
Yoshihiro MUROTA, MD
Iseki TAKAMOTO, MD*
Hiroshi IKENOUCI, MD, FJCC*
Yoshiyuki HADA, MD, FJCC*
Akira FURUSE, MD, FJCC

Abstract

A 15-year-old girl developed subacute constrictive pericarditis following successful surgical repair of double-chambered right ventricle. Two weeks after surgery, the patient had massive pericardial effusion, which acutely progressed to constrictive pericarditis with the symptoms of cardiac tamponade. Further surgery was necessary to resect the parietal pericardium. No blood transfusion was required for this patient, who was a Jehovah's Witness. She was doing well 9 months after the second operation, with residual pericardium of normal thickness.

J Cardiol 2002 May; 39(5): 267 - 270

Key Words

■ Cardiac surgery (double-chambered right ventricle) ■ Pericarditis (subacute constrictive)

INTRODUCTION

Subacute constrictive pericarditis is a rare complication of open heart surgery. Recently we treated a 15-year-old girl with double-chambered right ventricle. Surgery was performed to improve the low cardiac output state due to subacute constrictive pericarditis. No blood transfusion was needed for this patient who was a Jehovah's Witness. She is now well and the resting pericardium has normal thickness.

CASE REPORT

A 15-year-old girl was referred to our hospital for surgical repair of double-chambered right ventricle. The diagnosis of double-chambered right ventricle with situs inversus was made when she

was 2 years old. She had been followed up at a children's hospital. Surgical repair had been postponed because the patient and her entire family were Jehovah's Witnesses. Physical examination found a systolic murmur of Levine / at the second and third right sternal borders. Electrocardiography and chest roentgenography showed situs inversus, but no other abnormality. Cardiac catheterization data measured in 1999 are shown in **Table 1**. Abnormal muscle bands were noticed within the right ventricle and a pressure gradient of 45 mmHg was measured between the inflow and outflow chambers of right ventricle. The small ventricular septal defect was identified as the perimembranous type with aneurysm formation.

Surgery was performed on December 19, 2000. The procedures were division of abnormal muscle

JR 東京総合病院 心臓血管外科, *循環器内科: 〒151-8528 東京都渋谷区代々木2-1-3

Divisions of Thoracic and Cardiovascular Surgery and *Cardiology, JR Tokyo General Hospital, Tokyo

Address for correspondence: KAWAUCHI M, MD, FJCC, Division of Thoracic and Cardiovascular Surgery, JR Tokyo General Hospital, Yoyogi 2-1-3, Shibuya-ku, Tokyo 151-8528

Manuscript received November 15, 2001; revised February 12, 2002; accepted February 12, 2002

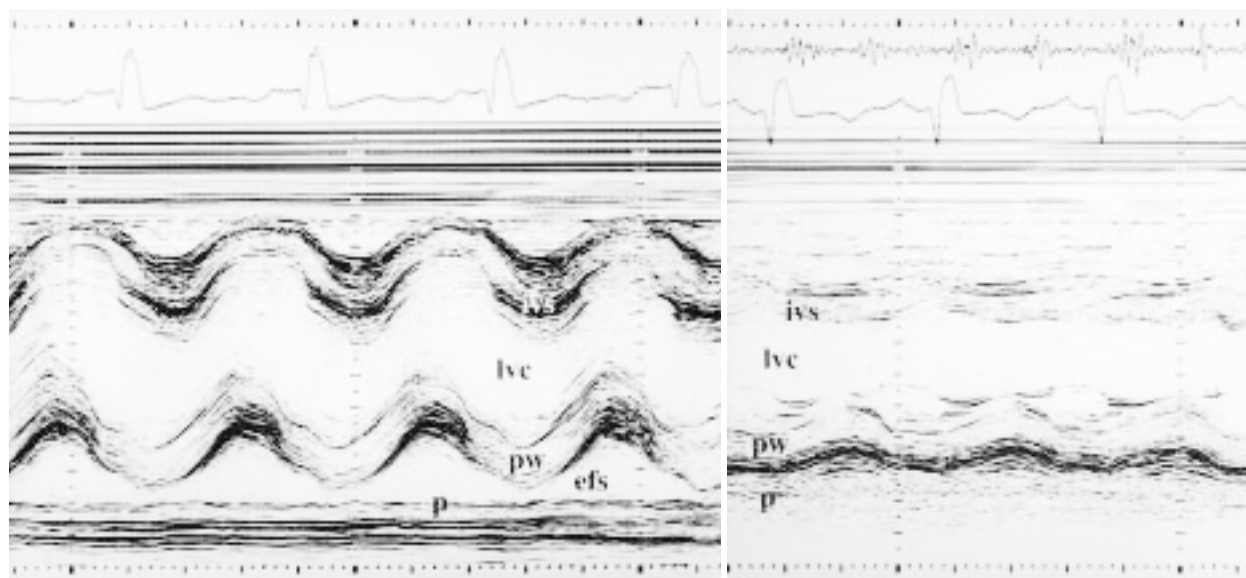
Table 1 Cardiac catheterization data before cardiac repair

Site	SaO ₂ (%)	Pressure (mmHg)
Superior vena cava	72.4	
Right atrium	75.0	(10)
Inferior vena cava	77.9	
Left pulmonary artery	80.8	20/8 (16)
Left PAWP		(12)
Right pulmonary artery	79.2	24/12 (17)
Right PAWP		(11)
Main pulmonary artery	79.2	24/12 (17)
RV _{out} flow	80.2	24/8
RV _{in} flow	75.1	70/10
Left ventricle	97.2	110/12
Aorta	96.6	110/85

Pressure indicates systole/diastole(mean)

Systemic blood flow : 2.8 l/min/m², pulmonary blood flow : 3.6 l/min/m², right-to-left shunt 0%, left-to-right shunt 23%, pulmonary vascular resistance : 1.4 Ru/m²(November 1, 1999) PAWP = pulmonary arterial wedge pressure ; RV = right ventricle.

bands, direct suture closure of the ventricular septal defect, and patch enlargement of right ventricular outflow with expanded poly-tetrafluoroethylene graft reinforced by autologous pericardium. The patient did not require blood transfusion. The post-operative course was uneventful till 2 weeks after surgery, when echocardiography revealed massive pericardial effusion(**Fig. 1**) and pendulum motion of the entire heart. Serous pericardial effusion totalling more than 1,000ml was drained through the intercostal wound for T sternotomy over the next few days. Two weeks later, she began to vomit. Echocardiography(**Fig. 1**) and chest computed tomography(CT ; **Fig. 2**) revealed pericardial thickening and a small amount of fluid collection in the pericardial space. Swan-Ganz catheter examination showed elevated mean pulmonary arterial wedge pressure(26mmHg) and low cardiac output (2.08 l/min) The second operation was performed on February 3, 2001. Only a small amount of serous pericardial fluid collection was found. However, the parietal pericardium and pleura had fused to form a hard shell with a fibrous layer more than 10mm thick(**Fig. 3**) Partial pericardiectomy on both sides of the heart was performed. Immediately after the operation, central venous

**Fig. 1** M-mode echocardiograms

Left: Two weeks after the initial operation, massive pericardial effusion is observed.

Right: Two weeks later, a small amount of pericardial effusion and markedly thickened pericardium is seen.

p = pericardium ; pw = posterior wall ; efs = echo free space ; ivs = interventricular septum ; lvc = left ventricular cavity.

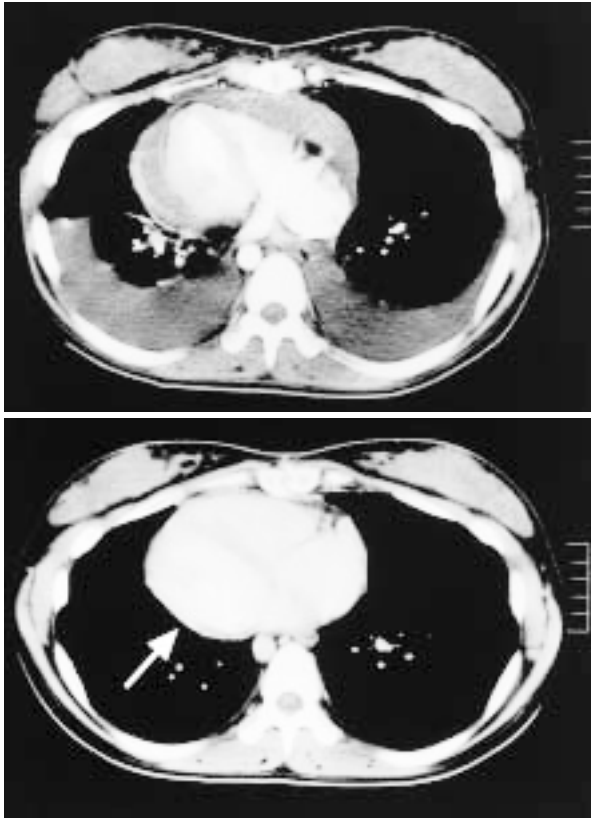


Fig. 2 Chest computed tomography scans

Upper: Before the pericardiectomy, small amounts of pericardial effusion, markedly thickened pericardium, small ventricles, and moderate pleural effusion are recognized as well as situs inversus.

Lower: Five months after pericardiectomy, the residual pericardium has become thin as indicated by the white arrow.

pressure was reduced to 14 mmHg. She was given 5 mg prednisolone orally for about 2 weeks. She was discharged from hospital on March 10, 2001.

Chest CT after discharge showed the residual pericardium was thinner than before (Fig. 2). She is now enjoying school life, including gymnastics. Histological examination of the resected pericardium revealed fibrous thickening with chronic inflammation.

DISCUSSION

Although Jehovah's Witnesses with congenital heart anomalies are often refused surgical therapy, we do not believe this is a contraindication because the surgery is feasible without blood transfusion^{1,2}. The patient was a high school student, so we treated her as an adult case according to the guidelines of the Tokyo Metropolitan Government³, and informed consent was acquired before surgery.

Pericardial thickening occurring so soon after surgery is rare⁴⁻⁶. The pathogenesis of such a pericardial thickening is not well documented, but irritation of the pericardial layer during the initial operation and postoperative fluid collection in the pericardial space may contribute to the development of constrictive pericarditis⁴. Constrictive pericarditis has an incidence of 0.2% after open heart surgery, but only 3 of 11 patients presented with symptoms within 60 days of the initial surgery. The current patient required surgical intervention as well as oral prednisolone administration to avoid the recurrence of constrictive pericarditis.

The thinning of the residual pericardium sug-

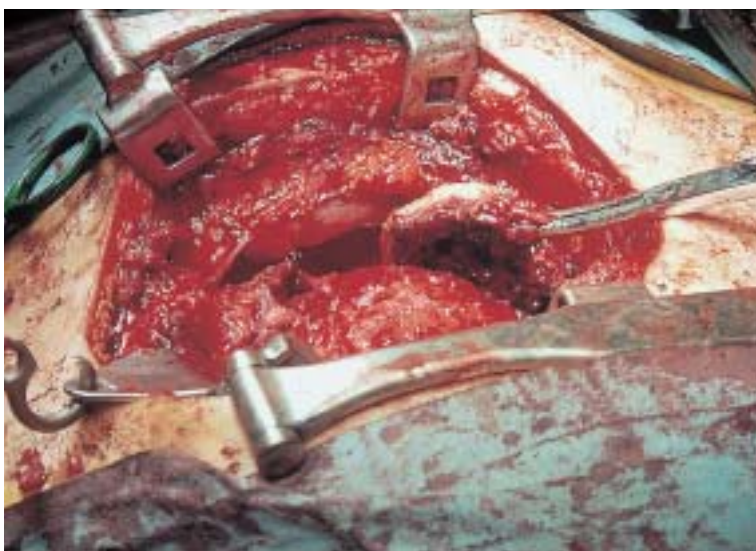


Fig. 3 Operative photograph showing thickened pericardium

gests that the process of pericardial thickening might be caused by reversible inflammatory reaction of the pericardium and the surrounding tissues. In contrast to previous cases⁷⁾, the pericardial fluid of our patient was serous and not bloody, which may support this hypothesis. However, the question arises whether steroid pulse therapy alone may

resolve the progression of constriction during the period of rapid development of pericardial thickening. We do not think that double-chambered right ventricle and constrictive pericarditis have any relationship. Further experience will answer these questions.

要 約

右室二腔症根治手術後に併発した可逆性亜急性収縮性心膜炎の1例

田中 公啓 川内 基裕 室田 欣宏 高本 偉碩
池ノ内 浩 羽田 勝征 古瀬 彰

15歳女性のエホバの証人派信者の右室二腔症根治手術後に亜急性収縮性心膜炎を併発し、心膜切除術と副腎皮質ステロイドにより治療した。開心術後の亜急性心膜炎の報告は少ないが、急性期の炎症が関与していたのではないかと思われた。手術の9ヵ月後、心膜は正常の厚さまで戻った。

J Cardiol 2002 May; 39(5): 267 - 270

References

- 1) Tanaka K, Furuse A, Matsunaga H, Okabe H, Shindoh G, Tanaka O, Sekiguchi A, Nakajima J, Igarashi H, Murakami R: Cardiac operation in children of Jehovah's Witnesses. *Kyobu Geka* 1989; **42**: 185 - 188 (in Jpn with Eng abstr)
- 2) Furuse A, Kotsuka Y, Kawauchi M, Tanaka O, Hirata K: Cardiac surgery in Jehovah's Witness. *Kyobu Geka* 1998; **51**: 89 - 94 (in Jpn with Eng abstr)
- 3) Ethic committee of Tokyo Metropolitan Government: *in* Guidelines for refusal of blood transfusion by religious reasons. Tokyo Metropolitan Government, Tokyo, 1995 (in Japanese)
- 4) Kutcher MA, King SB, Alimurung BN, Craver JM, Louge RB: Constrictive pericarditis as a complication of cardiac surgery: Recognition of an entity. *Am J Cardiol* 1982; **50**: 742 - 748
- 5) Ito M, Tanabe Y, Suzuki K, Kumakura M, Nakayama K, Kanazawa H, Yamazaki Y, Aizawa Y: A case of effusive-constrictive pericarditis after cardiac surgery. *Mayo Clin Proc* 2001; **76**: 555 - 558
- 6) Cimino JJ, Kogan AD: Constrictive pericarditis after cardiac surgery: Report of three cases and review of the literature. *Am Heart J* 1989; **118**: 1292 - 1301
- 7) Matsuyama K, Matsumoto M, Sugita T, Nishizawa J, Yoshioka T, Tokuda Y, Ueda Y: Clinical characteristics of patients with constrictive pericarditis after coronary bypass surgery. *Jpn Circ J* 2001; **65**: 480 - 482