

Multi-Focus Setting Improves the Heterogeneity of Myocardial Opacification in Intravenous Contrast Echocardiography

Masao DAIMON, MD^{*1}
Shintaro BEPPU, MD, FJCC^{*2}
Fuminobu ISHIKURA, MD, FJCC^{*2}
Hiroaki UEDA, MD^{*2}
Hiroyuki KAYANO, MD^{*2}
Haruka KOBAYASHI, BS^{*2}
Yasushi KASHIWAGI, BS^{*2}
Sachiko YAGURA, BS^{*2}
Kumiko HIRATA, MD
Junichi YOSHIKAWA, MD,

Abstract

Objectives. Myocardial contrast echocardiography observes heterogeneous opacification between regions near and far from the transducer depending on the depth of the focus point. The efficacy of the multi-focus setting was investigated for the improvement of this heterogeneous opacification of the myocardium in myocardial contrast echocardiography.

Methods. Myocardial contrast echocardiography was performed in five closed-chest dogs using triggered (every fourth cardiac cycle) second harmonic technology (1.8/3.6 MHz) following intravenous injection of 0.1 ml of Optison™. The short-axis view of the left ventricle was recorded and baseline subtracted video intensity (peak intensity) was calculated in the anterior, septal and posterior left ventricular walls to evaluate myocardial opacification. Three different single foci at near (2 cm), middle (4 cm), and far (6 cm) points were examined, as well as the multi-focus setting combining the near and far foci.

Results. Using any single focus point, the peak intensities of segments far from the focus points were decreased and heterogeneous myocardial opacification was observed. Only the multi-focus setting demonstrated absence of differences in peak intensities between each segment with sufficient myocardial opacification of all segments.

Conclusions. The multi-focus setting may be advantageous for improving the heterogeneity of myocardial opacification in myocardial contrast echocardiography.

J Cardiol 2002 Jul; 40(1): 11-17

Key Words

■ Contrast echocardiography ■ Coronary circulation (myocardial perfusion)
■ Myocardium (myocardial opacification) ■ Diagnostic techniques
■ Experimental medicine

大阪市立大学大学院医学研究科 循環器病態内科学: 〒545-8585 大阪市阿倍野区旭町1-4-3; * (現) 千葉大学大学院医学研究科 循環病態内科学, 千葉: 〒260-8670 千葉市中央区亥鼻1-8-1; *² 大阪大学医学部 保健学科, 大阪
Department of Internal Medicine of Cardiology, Graduate School of Medicine, Osaka City University, Osaka; * (present) Department of Cardiovascular Science and Medicine, Graduate School of Medicine, Chiba University, Chiba; *² School of Allied Health Sciences, Osaka University, Faculty of Medicine, Osaka

Address for correspondence: DAIMON M, MD, Department of Cardiovascular Science and Medicine, Graduate School of Medicine, Chiba University, Inohana 1-8-1, Chuo-ku, Chiba 260-8670

Manuscript received January 7, 2002; revised May 22, 2002; accepted May 22, 2002

BS = bachelor of science

INTRODUCTION

Intravenous myocardial contrast echocardiography (MCE) is based on various technological advances, such as intermittent imaging¹⁻⁴ or second harmonic imaging⁵, and is now widely used for assessing myocardial perfusion. MCE uses ultrasonography to detect microbubbles injected into the vascular system and passed into the myocardium. Recent studies have reported real-time visualization of myocardial perfusion using low emission power that reduced microbubble destruction^{6,7}. In addition, a number of technical details relating to both contrast agents and imaging have been examined⁸. However, the optimal technique of MCE has yet to be determined.

The identification of myocardial opacification defects by MCE allows the assessment of myocardial perfusion abnormalities in many clinical settings. In particular, the accurate estimation of myocardial perfusion abnormalities at rest or during stress by MCE has important implications for the diagnosis of coronary artery disease^{9,10}. However, heterogeneous myocardial opacification is often observed between regions located near and far from the transducer, depending on the depth of the focus point¹¹. This heterogeneity may lead to difficulties in interpretation of myocardial opacification defects and erroneous estimation of perfusion abnormalities in MCE. The multi-focus method, in which two focus points can be set simultaneously, is a new technique for improving this heterogeneity, but the efficacy remains unclear.

This study examined the efficacy of the multi-focus method for improving the heterogeneous opacification in MCE.

METHODS

Animal preparation

This study used five closed-chest dogs. All procedures were approved by the Institutional Animal Care Committee and conformed to the guidelines of the American Heart Association on Research Animal Use. Each dog was anesthetized with intravenous sodium pentobarbital after premedication with ketamine hydrochloride, intubated, and mechanically ventilated with a Harvard respirator. Additional anesthesia was administered during the experiment as needed. The dogs were then placed in the left lateral decubitus position. A 20-gauge Teflon catheter was placed in the left cephalic vein

as a peripheral venous line.

Myocardial contrast echocardiography

MCE used a SONOS5500 (Phillips Medical Systems) with an S4 transducer. MCE was performed using electrocardiogram-triggered (one to four cardiac cycles) second harmonic technology at end-systole in which ultrasound was transmitted at 1.75 MHz and received at 3.5 MHz. To image the same cardiac cross-section at all stages, the transducer was affixed to the procedure table with a clamp. Image registration of the left ventricle was set to provide a short-axis view at the midpapillary muscle level. The mechanical index was set at 1.1. The gain and reject settings were optimized at the beginning of each experiment and kept constant throughout the experiment. Three different single focus points and one multi-focus setting were examined. The single focus points were set at near (2 cm), middle (4 cm) and far (6 cm), and the multi-focus setting was the combination of the near and far foci (Fig. 1).

Optison (Molecular Biosystems, Inc.) was used as a contrast agent. The microbubbles from this agent have no effect on systemic hemodynamics or pulmonary gas exchange¹². Optison (0.1 ml) was injected through the peripheral venous line followed by intravenous saline at 10 ml/min. All images before and after injection of the contrast agent were recorded, until the disappearance of myocardial opacification, on 1/2-inch S-VHS tape for later analysis. To minimize motion artifacts during injections of contrast agent, the respirator was turned off during image acquisition¹³.

Myocardial contrast analysis

Videointensity was used to examine myocardial opacification. To examine heterogeneous myocardial opacification, three different elliptic regions of interest (100 square pixels, 5 × 10 mm in diameter) were placed in the anterior wall, septum, and posterior wall of the left ventricle for measurements of videointensity. An off-line image analysis system (Color Cardiology Work Station, TomTec) was used to measure the videointensity of each region using a gray scale of 256 levels. To correct for interanimal variability, peak intensity was defined as the peak videointensity from which the baseline videointensity was subtracted.

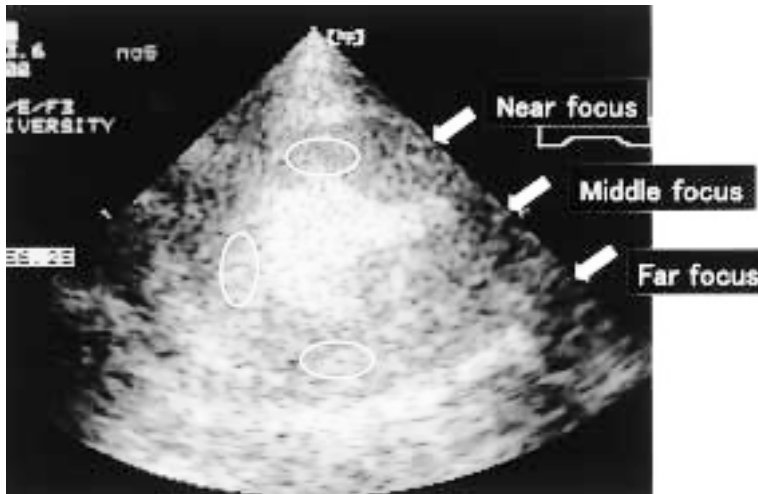

Fig. 1 Positions of the focus points and three different regions of interest

The single focus point was set at near (2 cm), middle (4 cm), far (6 cm), and the multi-focus setting was the combination of the near and far foci.

The *ellipsoids* on the left ventricle indicate three different regions of interest.

Statistical analysis

Data from all animals are presented as the mean \pm SD. One-way analysis of variance (ANOVA) was used to compare group means. The Fisher least significant difference test was used for the post hoc test. $p < 0.05$ was considered significant for all analyses.

RESULTS

Three different single focus settings and one multi-focus setting were evaluated in each of the five closed-chest dogs. Any setting showed visually appreciable myocardial opacification. However, the peak intensities of each region of interest varied in response to the focus setting (Fig. 2). The difference of peak intensities at each region of interest at the different focus points is shown in Fig. 3.

Using any single focus point, the peak intensities were higher in the regions of interest nearest to the focus point and lower in regions far from the focus points. Therefore, heterogeneous myocardial opacification was observed.

At the near focus point, the peak intensity of the posterior wall was 28.6 ± 13.3 , which was significantly less than that of the septum (67.4 ± 16.2 , $p < 0.01$), and was also significantly less than that measured at the far focus point (43.8 ± 14.9). At the middle focus point, the peak intensities of the anterior and posterior wall were 37.2 ± 20.9 and 38.4 ± 7.0 , respectively, and were significantly less than that of the septum (76.4 ± 12.9 , $p < 0.01$). At the far focus point, the peak intensity of the anterior wall was 23.0 ± 12.1 , significantly less than that of the septum (64.4 ± 17.5 , $p < 0.001$) or posterior

wall (43.8 ± 12.9), and significantly less than that measured at the near focus point (48.2 ± 19.8). Only the multi-focus setting demonstrated no significant differences in peak intensities between each segment as well as sufficient myocardial opacification of all segments.

DISCUSSION

Myocardial perfusion can now be assessed by MCE during venous administration of contrast agents with microbubbles. However, the ultrasound machine settings, such as the transducer standoff¹⁴, focus points¹⁵, mechanical index¹⁶, or pulsing interval¹⁷, affect myocardial opacification in MCE, and the optimal setup of ultrasonic equipment for adequate myocardial opacification has yet to be determined.

This animal study demonstrated heterogeneous myocardial opacification between regions near and far from the transducer as a function of the depth of focus, and indicated that the multi-focus method can reduce this heterogeneity.

Influence of focus point setting on myocardial opacification

Contrast agent microbubbles are resonated and destroyed by ultrasound in proportion to the acoustic power. MCE visualizes myocardial perfusion using such contrast emissions from microbubbles. Therefore, different acoustic outputs may produce different intensities of contrast enhancement.

The sector probe used in the ultrasound system for echocardiography allows alternation of "focus points" by changing the timing of the phased array.

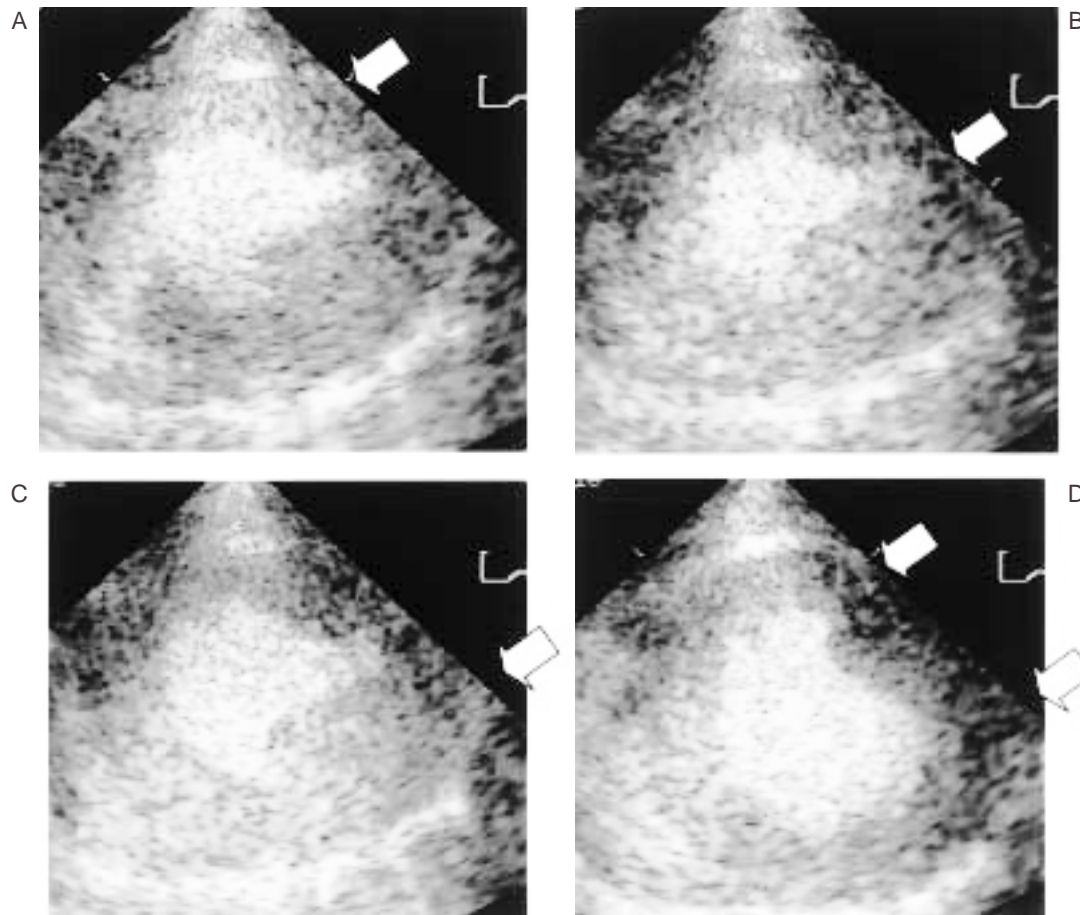


Fig. 2 Differences in myocardial opacification measured at the focus points

Using a single focus, the peak intensities of regions far from the foci were reduced and heterogeneous myocardial opacification was observed. The multi-focus setting provided more homogeneous myocardial opacification.

A: Near focus(2 cm) B: Middle focus(4 cm) C: Far focus(6 cm) D: Multi-focus[combination of the near(upper arrow)and far(lower arrow)foci]

At the near-field focus points, both the convergence of the ultrasound beam and the acoustic power are maximum. Therefore, the intensity of contrast enhancement from regions around the focus points should be increased. Furthermore, in the field near the transducer, the width of the ultrasound beam may induce excessive destruction of microbubbles, and subsequently reduce the contrast enhancement of these regions. Thus, the myocardial opacification of the anterior wall was especially susceptible to the position of the focus points in this study. We have previously shown that such heterogeneous microbubble destruction may cause heterogeneous myocardial opacification in MCE¹¹). The current animal study found that the peak intensities were highest in regions near the focus points but lower in regions far from the focus points. Thus, heteroge-

neous myocardial opacification occurs between regions near and far from the transducer depending on the depth of focus. Such heterogeneity can mimic myocardial perfusion abnormality in the assessment of myocardial perfusion with contrast echocardiography.

Efficacy of the multi-focus setting for myocardial opacification

The multi-focus setting using two focus points is one of the techniques for improvement of this heterogeneous myocardial opacification. However, the efficacy of the multi-focus method to determine myocardial opacification was unclear. This study examined the efficacy of the multi-focus method using a combination of two focus points(one at the depth of the anterior wall of the left ventricle and

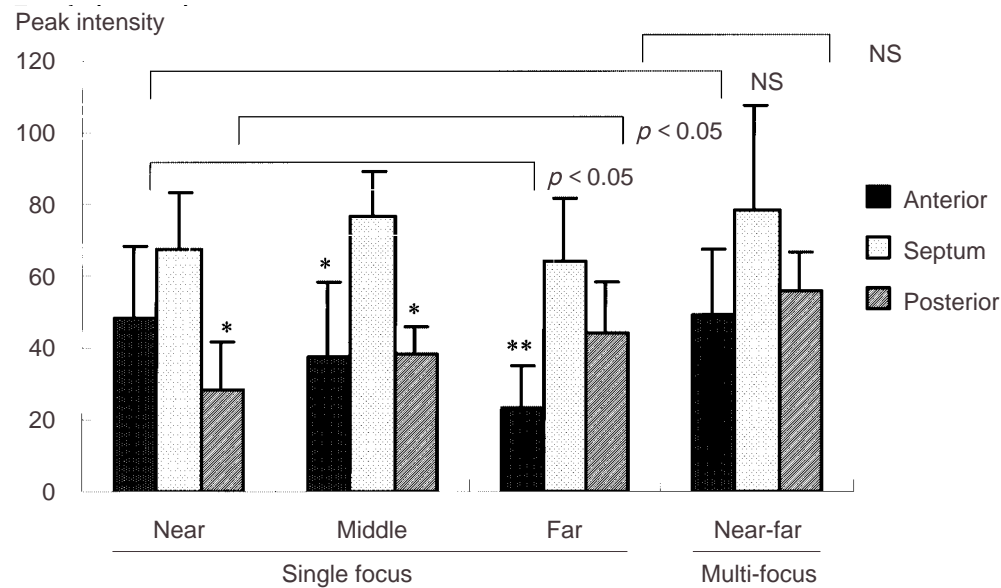


Fig. 3 Differences in peak intensities of the anterior wall, septum, and posterior wall of the left ventricle at different focus points

Peak intensity of the posterior wall measured at the near focus point was significantly less than that measured at the far focus point, whereas the peak intensity of the anterior wall measured at the far focus point was significantly less than that measured at the near focus point ($p < 0.05$). Only the multi-focus setting demonstrated no significant differences in peak intensities.

* $p < 0.01$, ** $p < 0.001$ vs septum.

the other at the depth of the posterior wall of the left ventricle) in the short-axis view at the midpapillary muscle level. In the current study, only the multi-focus point setting demonstrated no significant differences in peak intensities between each segment together with adequate peak intensities of all segments. Therefore, decreasing myocardial opacification as a function of distance from the transducer was not observed. The multi-focus method can reduce erroneous estimation of myocardial perfusion abnormalities caused by the distance from the transducer and the relationship to the depth of focus in the clinical setting.

Study limitations

This experimental study demonstrated that the multi-focus method significantly improved the heterogeneous myocardial opacification that is characteristic of MCE compared with the conventional single focus methods. However, the clinical implications of this method need careful consideration. First of all, in this study, MCE was performed in the short-axis view of the left ventricle in anesthetized closed-chest dogs. Therefore, some of the conditions in this experiment were different from

those in the clinical setting. The electronic sector probe employing the phased array produces low acoustic power in both sides of the lateral acoustic fields, in contrast to the mechanical sector probes. Therefore, myocardial opacification of the septum or lateral wall in short-axis views of the left ventricle may be an effect of that reduced acoustic power. Next, in the clinical setting, apical four-, two-, or three-chamber views are commonly used to avoid the effect of microbubbles in the right ventricular cavity, so the basal portion of the left ventricle and the transducer are further separated. Therefore, the effect of acoustic power on myocardial opacification may differ from that in this study. Additionally, the adjacent lung may influence myocardial opacification in the clinical setting. The canines in this study were ventilated mechanically with positive pressure and had higher heart rates (140 - 180 beats/min) than humans. Ventilation with positive pressure may affect the distribution of microbubble size when microbubbles pass through the lung¹⁷). High heart rates require more frequent exposure in the triggered images and this may possibly influence myocardial opacification.

At present, all sets of two focus points are not

feasible. For example, the multi-focus method did not permit the combination of middle and far foci in this study. The basal portion of the left ventricle is located further from the transducer in the clinical setting, so that the multi-focus setting with near and far foci may not have the same effect on myocardial opacification as observed in this study.

CONCLUSIONS

Heterogeneous myocardial opacification occurs between regions near and far from the transducer

depending on the depth of the focus point. This study demonstrated that the multi-focus setting achieves more homogeneous myocardial opacification in MCE. The effect of focus point setting is not an issue restricted to MCE, but is relevant to the entire field of echocardiography, and the multi-focus method is one way to address this issue. However, further investigations are needed for the clinical use of the multi-focus method because experimental conditions as used in the current study may differ from those in the clinical setting.

要 約

経静脈性心筋コントラストエコー法における心筋染影の不均一性に対する多重焦点法の効果

大門 雅夫 別府慎太郎 石蔵 文信 上田 宏昭 茅野 博行
小林 春香 柏木 寧 矢倉佐知子 平田久美子 吉川 純一

目 的: 心筋コントラストエコー法では, 焦点位置の設定に依存して, 探触子から遠近が異なる領域の心筋染影に不均一が生じることが知られている. 我々は2点の焦点の組み合わせが可能な多重焦点法を用いて, これらの不均一な心筋染影が改善されるか検討した.

方 法: 麻酔閉胸犬5匹に対して, 超音波造影剤オプチゾン™ 0.1 mlを静脈投与し, セカンドハーモニック法(1.8/3.6 MHz), 4心拍に1回の収縮末期同期で心筋コントラストエコー法を施行した. 乳頭筋レベルの左室短軸像を描出し, 焦点位置の設定を上(2 cm: 左室前壁の高さ), 中(4 cm: 左室中央の高さ), 下(6 cm: 左室後壁の高さ)の3通りの単一焦点法, および上と下の焦点の組み合わせからなる多重焦点法に変化させた. 記録されたビデオテープから心筋染影度を評価するために左室前壁, 中隔, 後壁における心筋輝度上昇度をそれぞれ計測し, それぞれの焦点設定での心筋輝度上昇度を比較検討した.

結 果: 単一焦点を用いた場合, いずれの設定においても焦点から離れた領域の心筋染影度は低下し, 不均一な心筋染影が観察された. 多重焦点法を用いた場合のみ各領域の心筋輝度上昇度に有意差を生じず, 各領域に十分な心筋染影が観察された.

結 論: 2点の焦点の組み合わせが可能な多重焦点法により, 心筋コントラストエコー法における不均一な心筋染影が改善される可能性がある.

J Cardiol 2002 Jul; 40(1): 11-17

References

- 1) Porter TR, Xie F: Transient myocardial contrast after initial exposure to diagnostic ultrasound pressures with minute doses of intravenously injected microbubbles: Demonstration and potential mechanisms. *Circulation* 1995; **92**: 2391 - 2395
- 2) Porter TR, Xie F, Kricsfeld D, Armsbruster RW: Improved myocardial contrast with second harmonic transient ultrasound response imaging in humans using intravenous perfluorocarbon-exposed sonicated dextrose albumin. *J Am Coll Cardiol* 1996; **27**: 1497 - 1501
- 3) Porter TR, Li S, Kricsfeld D, Armsbruster RW: Detection of myocardial perfusion in multiple echocardiographic windows with one intravenous injection of microbubbles using transient response second harmonic imaging. *J Am Coll Cardiol* 1997; **29**: 791 - 799
- 4) Wei K, Jayaweera AR, Firoozan S, Linka A, Skyba DM, Kaul S: Quantification of myocardial blood flow with ultrasound-induced destruction of microbubbles administered as a constant venous infusion. *Circulation* 1998; **97**: 473 - 483
- 5) Schrope BA, Newhouse VL: Second harmonic ultrasonic blood perfusion measurement. *Ultrasound Med Biol* 1993; **19**: 567 - 579
- 6) Porter TR, Li S, Jiang L, Grayburn P, Deligonul U: Real-

J Cardiol 2002 Jul; 40(1): 11-17

- time visualization of myocardial perfusion and wall thickening in human beings with intravenous ultrasonographic contrast and accelerated intermittent harmonic imaging. *J Am Soc Echocardiogr* 1999; **12**: 266 - 271
- 7) Tiemann K, Lohmeier S, Kuntz S, Köster J, Pohl C, Burns P, Porter TR, Nanda NC, Lüderitz B, Becher H: Real-time contrast echo assessment of myocardial perfusion at low emission power: First experimental and clinical results using power pulse inversion imaging. *Echocardiography* 1999; **16**: 799 - 809
 - 8) Block RJ, Brodsky L, Ostonic T, Fernandez A, Hickie P, Devries S, Bieniarz T, In M, Feinstein SB: Optimizing albumex in the left ventricle: An analysis of the technical parameters of four ultrasound systems in canines and humans. *J Am Soc Echocardiogr* 1996; **9**: 787 - 794
 - 9) Kaul S, Senior R, Dittrich H, Raval U, Khattar R, Lahiri A: Detection of coronary artery disease with myocardial contrast echocardiography: Comparison with ^{99m}Tc-sestamibi single-photon emission computed tomography. *Circulation* 1997; **96**: 785 - 792
 - 10) Marwick TH, Brunken R, Meland N, Brochet E, Baer FM, Binder T, Flachskampf F, Kamp O, Nienaber C, Nihoyannopoulos P, Pierard L, Vanoverschelde JL, van der Wouw P, Lindvall K, for the Nycomed NC 100100 Investigators: Accuracy and feasibility of contrast echocardiography for detection of perfusion defects in routine practice: Comparison with wall motion and technetium-99m sestamibi single-photon emission computed tomography. *J Am Coll Cardiol* 1998; **32**: 1260 - 1269
 - 11) Daimon M, Beppu S, Ishikura F, Ueda H, Kobayashi H, Kashiwagi Y, Yagura S, Yoshikawa J: Optimal setting of focus points for myocardial contrast echocardiography with intravenous Optison(FS-69): An experimental study. *J Cardiol* 2001; **37**: 201 - 207 (in Jpn with Eng abstr)
 - 12) Meza M, Greener Y, Hunt R, Perry B, Revall S, Barbee W, Murgo JP, Cheirif J: Myocardial contrast echocardiography: Reliable, safe, and efficacious myocardial perfusion assessment after intravenous injections of a new echocardiographic contrast agent. *Am Heart J* 1996; **132**: 871 - 881
 - 13) Cheirif J, Zoghbi WA, Bolli R, O'Neill PG, Hoyt BD, Quinones MA: Assessment of regional myocardial perfusion by contrast echocardiography: II. Detection of changes in transmural and subendocardial perfusion during dipyridamole-induced hyperemia in a model of critical coronary stenosis. *J Am Coll Cardiol* 1989; **14**: 1555 - 1565
 - 14) Porter TR, Xie F, Li S, Kricsfeld D, Deligonul U: Effect of transducer standoff on the detection, spatial extent, and quantification of myocardial contrast defects caused by coronary stenoses. *J Am Soc Echocardiogr* 1999; **12**: 951 - 960
 - 15) Kobayashi H, Beppu S, Ishikura F, Ueda H, Matsushita K, Kashiwagi Y, Yagura S, Hamada T: Setting up ultrasound equipment for myocardial contrast echocardiography with venous injection of Optison(FS-69): An experimental study. *J Med Ultrasonics* 2000; **27**: 103 - 109
 - 16) Pelberg RA, Wei K, Komiyama N, Sklenar J, Bin J, Kaul S: Potential advantage of flash echocardiography for digital subtraction of B-mode images acquired during myocardial contrast echocardiography. *J Am Soc Echocardiogr* 1999; **12**: 85 - 93
 - 17) de Jong N, Hoff L, Skotland T, Bom N: Absorption and scatter of encapsulated gas filled microspheres: Theoretical considerations and some measurements. *Ultrasonics* 1992; **30**: 95 - 103