

## Idiopathic Left Ventricular Aneurysm Associated With Pleomorphic Ventricular Tachycardia: A Case Report

Fumiya UCHIDA, BHS

Eitaro FUJII, MD\*<sup>1</sup>

Koji MATSUOKA, MD\*<sup>1</sup>

Setsuya OKUBO, MD\*<sup>1</sup>

Atsunobu KASAI, MD\*<sup>2</sup>

Chikaya OMICHI, MD\*<sup>2</sup>

Takeshi NAKANO, MD, FJCC\*<sup>2</sup>

### Abstract

A 39-year-old Japanese woman presented with an idiopathic left ventricular aneurysm manifesting as recurrent episodes of palpitation. She was referred to our hospital for evaluation of sustained ventricular tachycardia. Echocardiography disclosed a dyskinetic well-defined wall bulge during both systole and diastole at the basal region of the interventricular septum, and reduced left ventricular wall thickness and severe hypokinesis at the anterolateral to posterolateral region. These appearances were confirmed by the angiographic findings. The sustained ventricular tachycardia was reproducibly induced by a single extrastimulus from the right ventricular apex. Subsequently, 4-type ventricular tachycardias were induced during the electrophysiological study and the mechanism of these ventricular tachycardias was considered reentry. Radiofrequency catheter ablation failed due to the changing QRS morphologies during the entrainment study. The patient was treated with cibenzoline 300 mg a day, and there has been no recurrence of tachycardia during the 18-month follow-up period.

J Cardiol 2002 Dec; 40( 6 ): 275 - 282

### Key Words

■Aneurysms      ■Ventricular tachycardia      ■Echocardiography, transthoracic  
■Ablation-catheter      ■Electrophysiology

### INTRODUCTION

The vast majority of left ventricular aneurysms occur in patients with coronary artery disease<sup>1-3</sup>. On the other hand, localized aneurysms of the left ventricle of unknown etiology are rare, and are defined as idiopathic left ventricular aneurysm (ILVA)<sup>4-6</sup>. ILVA is frequently associated with monomorphic ventricular tachycardia (VT) and located more often at the posterior and/or inferior wall<sup>5,6</sup>. Here, we describe a case of ILVA located at

the basal region of the anterolateral wall associated with pleomorphic VT (4-type VTs induced by electrophysiological study).

### CASE REPORT

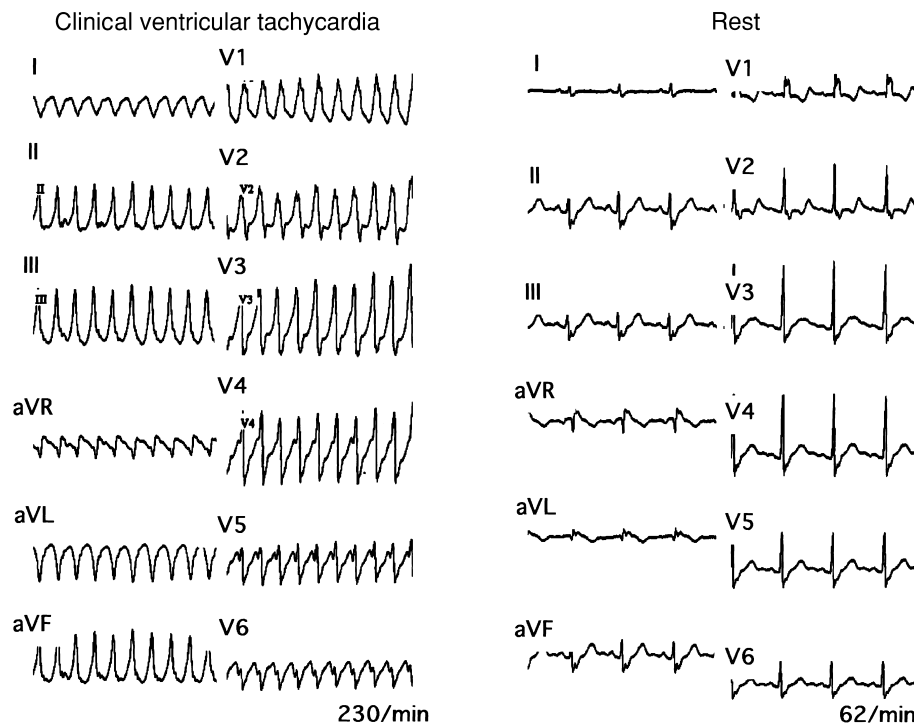
A 39-year-old Japanese woman with recurrent episodes of palpitation occurring once a week was referred to our hospital for evaluation of wide QRS complex tachycardia (Fig. 1 - left). During the tachycardia, systolic blood pressure was 100 mmHg, heart rate was 230 beats/min, and the

松阪市民病院 中央検査室, \*<sup>1</sup>内科: 〒515 - 8544 三重県松阪市殿町 1550; \*<sup>2</sup>三重大学医学部 第一内科, 三重  
Departments of Clinical Laboratory Medicine and \*<sup>1</sup>Internal Medicine and Cardiology, Matsusaka City Hospital, Mie; \*<sup>2</sup>The First  
Department of Internal Medicine, Mie University School of Medicine, Mie

**Address for correspondence:** UCHIDA F, BHS, Department of Clinical Laboratory Medicine, Matsusaka City Hospital, Tonomachi  
1550, Matsusaka, Mie 515 - 8544

Manuscript received July 4, 2002; revised August 27, 2002; accepted September 26, 2002

BHS = bachelor of health science



**Fig. 1** Twelve-lead electrocardiograms taken during palpitation attack and on admission

*Left:* During the wide QRS complex tachycardia, the QRS configuration reveals right bundle branch block and inferior axis and atrioventricular dissociation was seen in leads I, II, aVR, and aVF, confirming the diagnosis of ventricular tachycardia.

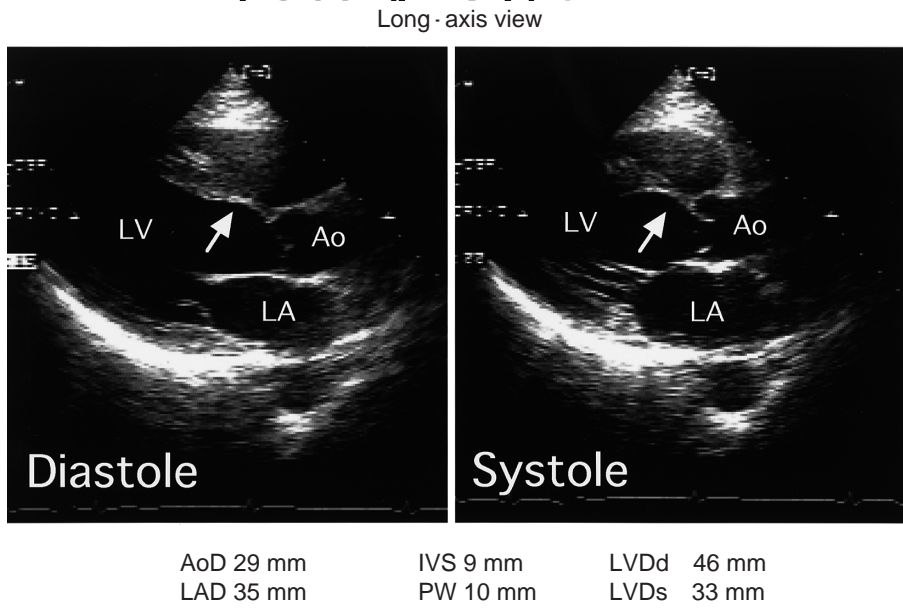
*Right:* On admission, the baseline electrocardiogram reveals normal sinus rhythm with complete right bundle branch block and no abnormal Q wave.

QRS configuration showed right bundle branch block pattern and inferior axis. Atrioventricular dissociation was seen in leads I, II, aVR, and aVF, confirming the diagnosis of VT. Verapamil, adenosine triphosphate and procainamide were administered intravenously. However, the clinical VT was not interrupted, and required electrical cardioversion (100 J) for termination. On admission, the baseline electrocardiogram revealed normal sinus rhythm with complete right bundle branch block and no abnormal Q wave (Fig. 1 - right). Physical examination, chest radiography, and cardiac enzymatic and serologic data were all within normal limits. Furthermore, no hilar, mediastinal, or superficial lymphadenopathy, pulmonary, liver or spleen infiltrates, and no ophthalmic or cutaneous lesion indicating systemic sarcoidosis were detected.

Echocardiography disclosed a dyskinetic well-defined wall bulge during systole and diastole at the basal region of the intraventricular septum in the parasternal left ventricular long-axis view (Fig. 2). Similarly, the dyskinetic systolic outward aneurysm was demonstrated from the anteroseptal region to

the anterolateral region at the level of the mitral valve in the parasternal left ventricular short-axis view. Furthermore, reduction of left ventricular wall thickness and severe hypokinesia were revealed at the level of the papillary muscle from the anterolateral region to the posterolateral region (Fig. 3). The echogenicity at the site of aneurysmal wall was not higher than the scar of post myocardial infarction.

Coronary angiography, left ventriculography, biopsy of the left endomyocardium and electrophysiological study were carried out after informed written consent was obtained. Coronary arteries were normal (Fig. 4 - left). Left ventriculography in two projections (right anterior oblique 30°, left anterior oblique 45°) disclosed the dyskinetic well-defined wall bulge persisting during both systole and diastole at the basal region from the anteroseptum to the anterolateral wall. The wall motion of the posterolateral region was severely reduced (Fig. 4 - right). These findings were identical with those obtained from two-dimensional echocardiography. Left endomyocardial biopsy found no aspects of

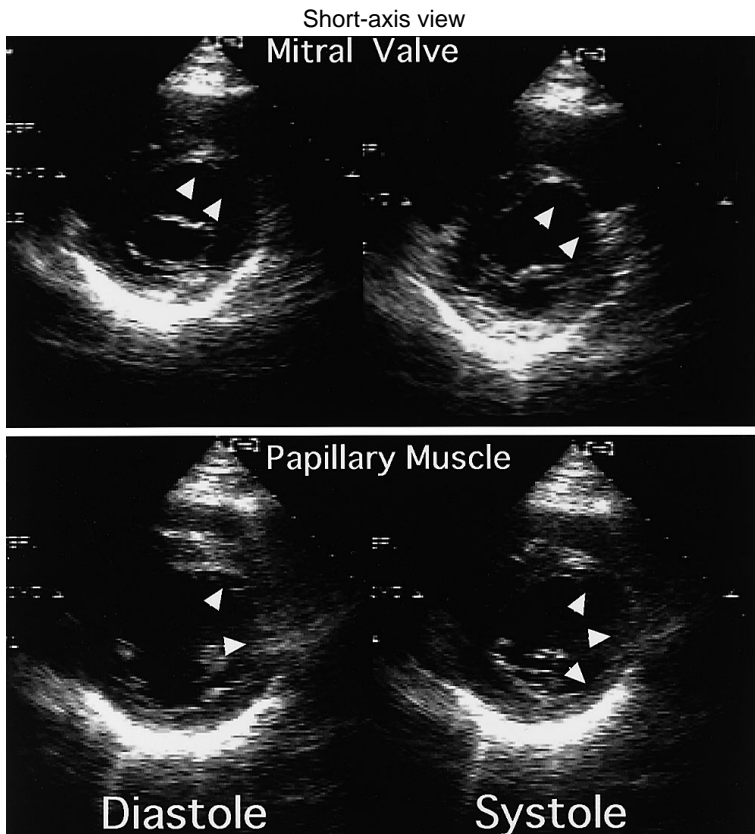


**Fig. 2** Two-dimensional echocardiograms in the left ventricular long-axis view (upper) and measurements obtained from the M-mode echocardiogram (lower)

Upper: The two echocardiograms show the dyskinetic well-defined wall bulge persisting during systole and diastole at the basal region of the intraventricular septum (arrow).

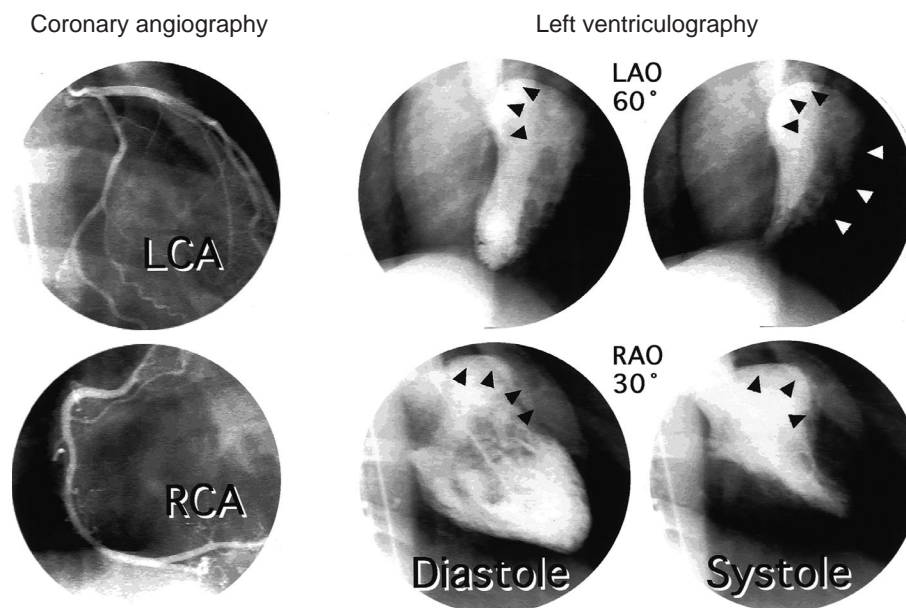
Lower: These data are all within normal limits.

LV = left ventricle; Ao = Aorta; LA = left atrium; AoD = aortic diameter; IVS = interventricular septum; LVDd = left ventricular end-diastolic diameter; LAD = left atrial diameter; PW = posterior wall; LVDs = left ventricular end-systolic diameter.



**Fig. 3** Two-dimensional echocardiograms at the level of the mitral valve (upper) and the papillary muscle (lower) in the left ventricular short-axis view (left: diastolic frame, right: systolic frame)

The dyskinetic systolic outward aneurysm extends from the anteroseptal region to the anterolateral region at the level of the mitral valve (arrowheads). Reduction of left ventricular wall thickness and severe hypokinesis are seen from the anterolateral region to the posterolateral region at the level of the papillary muscle (arrowheads). Note that the echogenicity at the site of aneurysmal wall and asynergic area is not so high and little different from the scar of post myocardial infarction.



**Fig. 4** Coronary angiograms (left) and left ventriculograms (right) in the left anterior oblique and right anterior oblique views

Coronary arteries are normal (left panel). Left ventriculograms disclose the dyskinetic well-defined wall bulge persisting during both systole and diastole at the basal region from the antero-septum to the anterolateral wall (solid arrowheads). The wall motion of the posterolateral region is severely reduced (white arrowheads). These findings are identical with those obtained from two-dimensional echocardiography.

LCA = left coronary artery; RCA = right coronary artery; LAO = left anterior oblique; RAO = right anterior oblique.

acute or healing myocarditis, granulomatous infiltrations, interstitial fibrosis or myocardial degeneration.

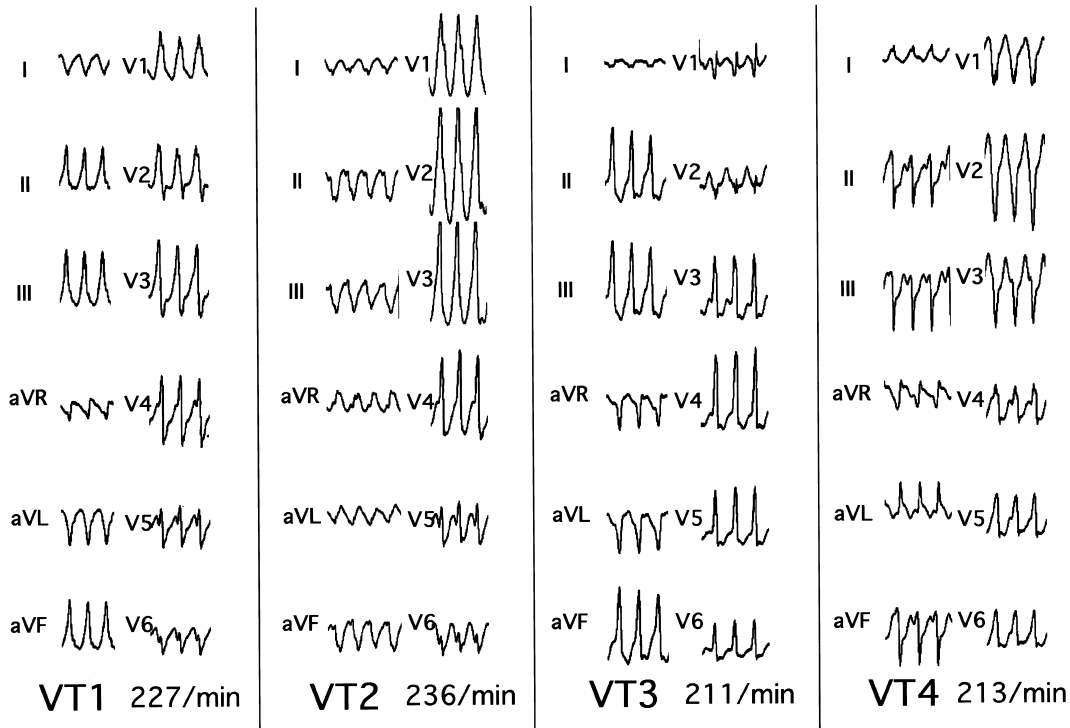
Electrophysiological study was performed with the patient in the fasting state and under light sedation with oral diazepam. All antiarrhythmic therapy was discontinued for at least five half-lives. Sustained VT was induced reproducibly by a single extrastimulus from the right ventricular apex. The QRS morphology was identical with that of clinical VT. Entrainment study was performed during the VT<sup>7,8</sup>). Pacing from the right ventricular apex demonstrated QRS-complex constant fusion at a constant pacing cycle length or different degrees of fusion at different pacing cycle lengths (progressive fusion), except for the last captured QRS complex. However, the QRS morphology immediately changed after termination of the pacing. Subsequently, 4-type VTs were induced (Fig. 5). Meticulous mapping along the aneurysm was performed using a steerable ablation catheter with a 4-mm distal electrode. The sustained VT2 was frequently observed during the electrophysiological study. Diastolic potentials were recorded during the

VT2 when the ablation catheter was positioned at the middle region of the anterolateral wall at the border of the aneurysm (Fig. 6). Radiofrequency catheter ablation was attempted. However, the critical site was difficult to identify due to the changing VT morphologies and the ablation failed. Programmed electrical stimulation was performed for evaluation of antiarrhythmic therapy. The VTs were not induced after cibenzoline was infused intravenously at a dose of 1.4 mg/kg.

There were no complications during these procedures. The patient was treated with cibenzoline 300 mg a day, and there has been no recurrence of tachycardia during the 18-month follow-up period.

## DISCUSSION

The present case of ILVA located at the basal region of the anterolateral wall was associated with 4-type VTs induced by electrophysiological study. Echocardiography may be helpful in evaluating the localized aneurysm and the wall motion abnormalities of the left ventricle. Radiofrequency catheter ablation failed due to the changing VT morphologies during the entrainment study. This is an unusu-



**Fig. 5** Tracings of 4-type VTs induced by extra stimulus or entrainment study from the right ventricular apex or close to the aneurysm of the left ventricle

The VT1 is identical with the clinical VT. VT1, VT2 and VT3 show right bundle branch block configurations. VT4 shows left bundle branch block configuration. The QRS axis of VT1 and VT3 is the inferior axis. VT2 and VT4 show the superior axis.

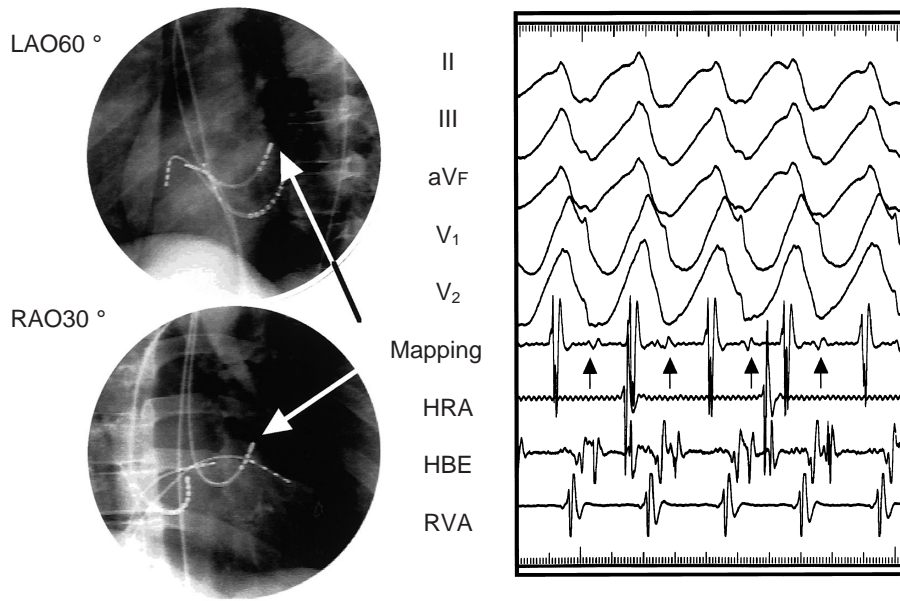
VT = ventricular tachycardia.

al case demonstrating the anatomic and electrophysiological features of ILVA associated with pleomorphic VT.

Several etiologies for ventricular aneurysm have to be excluded before the diagnosis of ILVA can be established. Left ventricular aneurysm is a common complication of myocardial infarction<sup>1-3</sup>). However, we could exclude ischemic heart disease based on the findings that the location of the left ventricular aneurysm and the asynergic area were not related to the coronary artery distribution and the echogenicity at the site of aneurysmal wall was not so high. Furthermore, the patient had no coronary risk factors, no history of chest pain and normal coronary arteries. Other etiologies of ventricular aneurysm include congenital diverticulum and congenital aneurysm<sup>9-16</sup>). In the past, the terms congenital diverticulum and congenital aneurysm have been used interchangeably. The lesion is termed diverticulum if the connection to the ventricular cavity is narrow, and as aneurysm if the point of connection to the ventricular cavity is

wide<sup>10,12,13,16</sup>). The congenital diverticulum has muscular and fibrous types. The muscular type has a preserved three-layered structure and is contractile. The fibrous type has a three-layered structure, but the myocardium is mostly replaced by fibrous tissue and is not contractile<sup>9,11,12</sup>). These two types can be distinguished by the location of the aneurysm, such as the apex of the left ventricle or the subvalvular region of the mitral or aortic annulus, and the presence of complications such as midline congenital abnormalities, and mitral or aortic incompetence<sup>12</sup>). Congenital aneurysm seems to belong to the fibrous type of congenital diverticulum<sup>9,11</sup>). We do not consider these congenital etiologies as likely because our case was a middle-aged woman in contrast to known patients with congenital diverticulum and congenital aneurysm.

Several specific causes of myocardial damage most also be excluded, including sarcoidosis, myocarditis, tuberculosis, syphilis and rheumatic heart disease. Echocardiography is a useful noninvasive technique for possible markers of sarcoid



**Fig. 6** Fluoroscopic images showing the mapping catheter close to the aneurysm of the left ventricle (left) and tracing recording the diastolic potential indicating the slow conduction zone (right; arrows) during VT2

The mapping catheter is located at the middle region of the anterolateral wall at the border of the aneurysm. The surface leads II, III, aVF, V<sub>1</sub>, V<sub>2</sub> and intracardiac recordings from the mapping catheter, high right atrium, His-bundle recording region, and right ventricular apex are shown.

HRA = high right atrium; HBE = His-bundle recording region; RVA = right ventricular apex. Other abbreviations as in Figs. 4, 5.

heart disease such as septal thickness or scars, pericardial effusion and decreased ventricular systolic function<sup>17</sup>). Focal abnormalities of wall motion affecting the basal portion of the ventricular septum should suggest the possibility of myocardial sarcoidosis even in the absence of recognized systemic manifestations<sup>18</sup>). ILVA might be difficult to distinguish from myocardial sarcoidosis based only on anatomic findings. Echocardiographic findings of myocarditis are polymorphous and nonspecific, as segmental wall motion abnormalities were identified in 25 (64%) of 41 patients, but left ventricular septal aneurysm was seen in only one patient<sup>19</sup>). These specific causes can also be excluded by the clinical course, physical examination, serologic data, absence of recognized systemic sarcoid manifestations and left endomyocardial biopsy showing no abnormal findings.

Left ventricular aneurysm due to transmural myocardial infarction is frequently associated with VT, but the incidence of ILVA as the anatomical substrate for sustained VT is very low. Comparison of the clinical and electrophysiologic features of ILVA with those of left ventricular aneurysm due to

myocardial infarction found no patients with 4-type VTs, and the location of aneurysms in 9 of 10 patients was at the posterior and/or inferior wall<sup>6</sup>). The mechanism of 4-type VTs in our case was considered to be reentry because induction and termination of VTs by programmed extrastimuli and entrainment phenomenon were observed reproducibly. Diastolic potential, which may suggest the slow conduction zone<sup>8,20</sup>), could be recorded at the border between the aneurysm and the asynergic area rather than the center of the aneurysm. The asynergic area was relatively wide and the VTs were easily degenerated to another QRS morphology during the entrainment study. These findings suggest that the reentrant circuit of the VTs was extremely complicated and the common critical slow conduction zone for these VTs may have been absent. In addition, the left ventricular aneurysm in our case was considered to be the fibrous type based on the absence of contractility and the slightly increased echogenicity of the aneurysm. The wide left ventricular aneurysm of fibrous type might be the complex arrhythmogenic substrate. Therefore, we could not interrupt the reentrant cir-



cuit for these VTs by radiofrequency catheter ablation.

The treatment for ILVA associated with sustained VT is diverse. Eight out of 340 consecutive patients were characterized by a left ventricular aneurysm of no detectable etiology in primary myocardial disease and all patients were successfully treated with anti-arrhythmic drugs<sup>5</sup>. On the other hand, surgical treatment has been required to control VT or implantation of an implantable cardioverter defibrillator to prevent sudden cardiac death<sup>21,22</sup>.

The long-term prognosis of ILVA caused by unknown etiology still needs further investigation. Echocardiography may be useful in the evaluation of the left ventricular aneurysm and function. However, we have to carefully examine ambulatory-Holter recording or electrophysiological study to assess whether the anti-arrhythmic drug is effective or not against the ventricular arrhythmia. If the VT is recurrent, further treatment such as implantable cardioverter defibrillator implantation may be needed.

## 要 約

### 複数単形性持続性心室頻拍を合併した特発性左室瘤の1例

内田 文也 藤井英太郎 松岡 宏治 大久保節也  
笠井 篤信 大道 近也 中野 赳

複数の単形性持続性心室頻拍を合併した特発性左室瘤の1例を経験したので報告する。症例は39歳、女性で、主訴は動悸である。動悸発作時、近医にて心室頻拍を指摘され、精査目的により当院へ紹介となった。心エコー図検査では、左室前中隔から前側壁の基部において限局性の菲薄化を伴った dyskinetic bulge と、前側壁から後側壁にかけての重篤な壁運動低下を認めた。これらは、左室造影により同様の所見が確認された。心臓電気生理学的検査では、4種類の持続性心室頻拍が右室心尖部からの単発期外刺激により再現性をもって誘発された。心室頻拍の機序は、リエントリーであった。高周波カテーテルアブレーションは、至適電部位決定のためのエントレインメントペーシングにより、異なった心室頻拍へ容易に移行するなどして成功には至らなかった。シベンゾリン静注下で心室頻拍の抑制効果を確認し、現在、シベンゾリン 300 mg/day の内服 18 カ月の経過観察により頻拍の再発を認めていない。

*J Cardiol* 2002 Dec; 40(6): 275 - 282

## References

- 1) Ba 'alabaki HA, Clements SD Jr: Left ventricular aneurysm: A review. *Clin Cardiol* 1989; **12**: 5 - 13
- 2) Friedman BM, Dunn MI: Postinfarction ventricular aneurysms. *Clin Cardiol* 1995; **18**: 505 - 511
- 3) Visser CA, Kan G, David GK, Lie KI, Durrer D: Echocardiographic-cineangiographic correlation in detecting left ventricular aneurysm: A prospective study of 422 patients. *Am J Cardiol* 1982; **50**: 337 - 341
- 4) Maloy WC, Arrants JE, Sowell BF, Hendrix GH: Left ventricular aneurysm of uncertain etiology with recurrent ventricular arrhythmias. *N Engl J Med* 1971; **285**: 662 - 663
- 5) Mestroni L, Morgera T, Miani D, Pinamonti B, Sinagra G, Tanganelli P, Silvestri F, Camerini F: Idiopathic left ventricular aneurysm: A clinical and pathological study of a new entity in the spectrum of cardiomyopathies. *Postgrad Med J* 1994; **70**(Suppl): S13 - S20
- 6) Tada H, Kurita T, Ohe T, Shimizu W, Suyama K, Aihara N, Shimomura K, Kamakura S: Clinical and electrophysiologic features of idiopathic left ventricular aneurysm with sustained ventricular tachycardia. *Int J Cardiol* 1998; **67**: 27 - 38
- 7) Waldo AL, Henthorn RW: Use of transient entrainment during ventricular tachycardia to localize a critical area in the reentry circuit for ablation. *Pacing Clin Electrophysiol* 1989; **12**: 231 - 244
- 8) Stevenson WG, Khan H, Sager P, Saxon LA, Middlekauff HR, Natterson PD, Wiener I: Identification of reentry circuit sites during catheter mapping and radiofrequency ablation of ventricular tachycardia late after myocardial infarction. *Circulation* 1993; **88**: 1647 - 1670
- 9) Chesler E, Tucker RBK, Barlow JB: Subvalvular and apical left ventricular aneurysms in the Bantu as a source of systemic emboli. *Circulation* 1967; **35**: 1156 - 1162
- 10) Treistman B, Cooley DA, Lufschanowski R, Leachman RD: Diverticulum or aneurysm of left ventricle. *Am J Cardiol* 1973; **32**: 119 - 123
- 11) Baltaxe HA, Wilson WJ, Amiel M: Diverticulosis of the left ventricle. *Am J Radiol* 1979; **133**: 257 - 261
- 12) Gueron M, Hirsch M, Opschitzer I, Mogel P: Left ventricular diverticulum and mitral incompetence in asymptomatic

- children. *Circulation* 1976; **53**: 181 - 186
- 13) Mardini MK: Congenital diverticulum of the left ventricle: Report of two unusual cases. *Br Heart J* 1984; **51**: 321 - 326
  - 14) Singh A, Katkov H, Zavoral JH, Sane SM, McLeod JD: Congenital aneurysms of the left ventricle. *Am Heart J* 1980; **99**: 25 - 32
  - 15) Nair M, Mohan JC, Arora R: Cross-sectional echocardiographic features of congenital submitral left ventricular aneurysm. *Int J Cardiol* 1989; **25**: 346 - 348
  - 16) Hamaoka K, Onaka M, Tanaka T, Onouchi Z: Congenital ventricular aneurysm and diverticulum in children. *Pediatr Cardiol* 1987; **8**: 169 - 175
  - 17) Lewin RF, Mor R, Spitzer S, Arditti A, Hellman C, Agmon J: Echocardiographic evaluation of patients with systemic sarcoidosis. *Am Heart J* 1985; **110**: 116 - 122
  - 18) Valantine H, McKenna WJ, Nihoyannopoulos P, Mitchell A, Foale RA, Davies MJ, Oakley CM: Sarcoidosis: A pattern of clinical and morphological presentation. *Br Heart J* 1987; **57**: 256 - 263
  - 19) Pinamonti B, Alberti E, Cigalotto A, Dreas L, Salvi A, Silvestri F, Camerini F: Echocardiographic findings in myocarditis. *Am J Cardiol* 1988; **62**: 285 - 291
  - 20) Bogun F, Bahu M, Knight BP, Weiss R, Goyal R, Daoud E, Man KC, Strickberger SA, Morady F: Response to pacing at sites of isolated diastolic potentials during ventricular tachycardia in patients with previous myocardial infarction. *J Am Coll Cardiol* 1997; **30**: 505 - 513
  - 21) Aizawa Y, Murata M, Satoh M, Aizawa M, Suzuki K, Kato H, Funazaki T, Shibata A, Eguchi S: Five cases of arrhythmogenic left ventricular aneurysm unrelated to coronary occlusion. *Jpn Circ J* 1986; **50**: 45 - 55
  - 22) Proclemer A, Miani D, Basasdonna PT, Rocco M, Nicotra G: Idiopathic left ventricular aneurysm: An unusual substrate of ventricular fibrillation and ventricular tachycardia. *J Interv Card Electrophysiol* 1998; **2**: 187 - 191