

## Impedance Cardiography and Quantitative Tissue Doppler Echocardiography for Evaluating the Effect of Cardiac Resynchronization Therapy: A Case Report

Hitoshi ADACHI, MD  
Tomoya HIRATSUJI, MD  
Shigeki SAKURAI, MD  
Hiroshi TADA, MD  
Takuji TOYAMA, MD, FJCC  
Shigeto NAITO, MD  
Hiroshi HOSHIZAKI, MD  
Shigeru OSHIMA, MD, FJCC  
Koichi TANIGUCHI, MD,

### Abstract

An 83-year-old woman presented with dilated cardiomyopathy. Cardiac resynchronization therapy was performed. Two weeks later, cardiac output and ventricular wall motion were estimated using impedance cardiography and tissue Doppler echocardiography with and without pacing. Cardiac output increased from 3.5 to 4.5 l/min during biventricular pacing with a 120 msec atrioventricular interval. Intraventricular phase difference for contraction decreased from 190 to 150 msec. When the atrioventricular interval was 180 msec, cardiac output and phase difference became 4.6 l/min and 170 msec. These assessments were performed rapidly and non-invasively. New impedance cardiography and tissue Doppler echocardiography are useful to evaluate the effect of cardiac resynchronization therapy.

*J Cardiol* 2003 Jul; 42(1): 37-42

### Key Words

- Cardiomyopathy, dilated
- Cardiac output (impedance cardiography)
- Cardiac pacing, artificial (cardiac resynchronization therapy, biventricular pacing)
- Doppler ultrasound (tissue Doppler echocardiography)

### INTRODUCTION

Biventricular pacing for severe heart failure has been used since the early 1990s<sup>1,2</sup>). The MIRACLE study and other studies have demonstrated that cardiac resynchronization therapy improves cardiac function, quality of life and exercise tolerance<sup>3,4</sup>). However, although most patients benefit from resynchronization therapy, some patients show no

improvement in cardiac function. Therefore, it is important to determine in advance whether biventricular pacing implantation will improve cardiac output. Temporary biventricular lead placement is sometimes used to determine whether cardiac resynchronization therapy will be beneficial before permanent pacemaker implantation is performed. This protocol uses pulmonary arterial catheterization to evaluate the cardiac output and pulmonary

群馬県立心臓血管センター 循環器内科: 〒371-0004 群馬県前橋市亀泉町甲3-12

Division of Cardiology, Gunma Prefectural Cardiovascular Center, Gunma

**Address for correspondence:** ADACHI H, MD, Division of Cardiology, Gunma Prefectural Cardiovascular Center, Ko 3-12, Kameizumi-cho, Maebashi, Gunma 371-0004

Manuscript received February 12, 2003; revised March 25, 2003; accepted March 25, 2003

wedge pressure. However, the pulmonary arterial catheter can sometimes interfere with placement of the lead of the biventricular pacemaker. In addition, the 5 to 10 ml of cold saline that is used to measure the cardiac output can sometimes elevate the pulmonary wedge pressure. Therefore, other techniques are required to measure the cardiac output. Recently, an accurate cardiac bio-impedance technique, impedance cardiography, has been developed<sup>5,6</sup>). Using this method, we can assess cardiac output non-invasively during biventricular pacemaker implantation.

The contraction and relaxation processes of the left ventricle are complex. In addition to the shortening and radial displacement, the ventricular wall moves towards the apex resulting in translational motion. Recently, quantitative tissue tracing methods using tissue Doppler echocardiography have been developed<sup>7,8</sup>). Tissue Doppler echocardiography can detect the translational motion and can be used to evaluate the phase difference between left ventricular free wall and intraventricular septal wall motion. The main purpose of cardiac resynchronization therapy is to minimize asynchronous ventricular wall motion. Therefore, it is extremely important to quantify the phase difference.

We treated a patient using these new methods to determine the effect of cardiac resynchronization therapy on cardiac output and ventricular wall motion.

### CASE REPORT

An 83-year-old woman was admitted to our hospital because of appetite loss, shortness of breath and fatigue. Chest roentgenography showed the cardiothoracic ratio was 74% (**Fig. 1 - left**). Moderate bilateral pulmonary congestion was present. The QRS duration was 190 msec and the complex had a left ventricular bundle branch block morphology (**Fig. 2 - left**). The left ventricular diameter was increased to 60 mm and the left ventricular ejection fraction was 13%. There was moderate mitral and tricuspid regurgitation. There was no evidence of myocardial ischemia, infection, history of hypertension, excessive alcohol use or metabolic diseases that could influence cardiac function. Therefore, the diagnosis was dilated cardiomyopathy. She had New York Heart Association (NYHA) class heart failure. Medical therapy was started with a diuretic, anti-phosphodiesterase inhibitor, atrial natriuretic peptide agent and

nitrate. However, the pulmonary vascular congestion did not improve. Beta-blockade and physical therapy were difficult to initiate because of the presence of persistent pulmonary congestion.

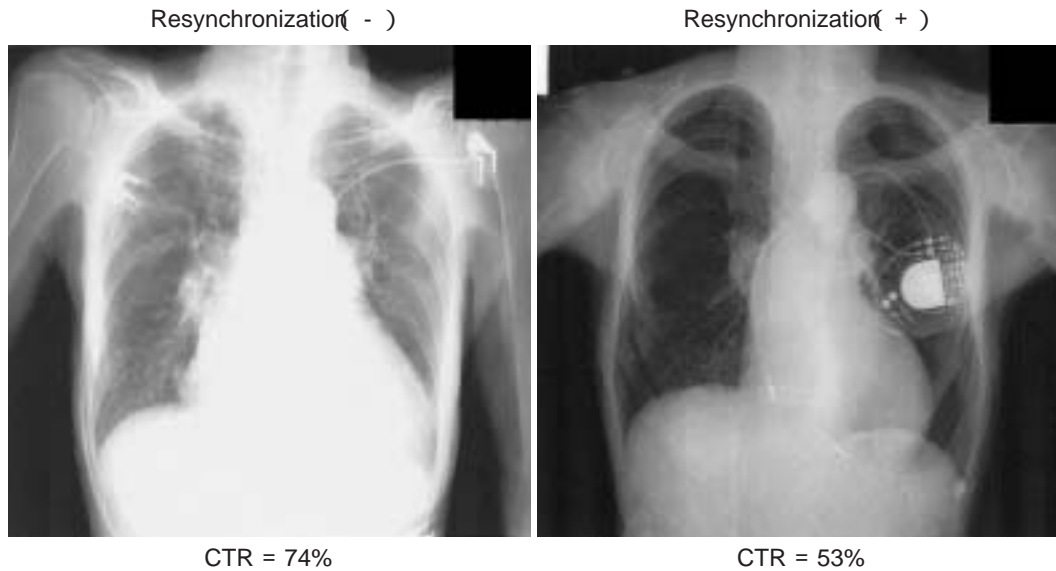
Three weeks after admission, cardiac resynchronization therapy was instituted with biventricular DDD-mode pacemaker implantation. The ventricular lead was divided using a Y-connector. One lead was inserted into the apex of the right ventricle, the other was advanced into a posterolateral branch of the coronary sinus. The pacing rate was initially set at 70/min. The atrioventricular (AV) delay time was set at 120 msec. The pacing output, and atrial and ventricular lead sensitivity were set as usual.

Ethical approval for this treatment was granted by the Human Subjects Committee of the Gunma Prefectural Cardiovascular Center. Written informed consent was given by the patient.

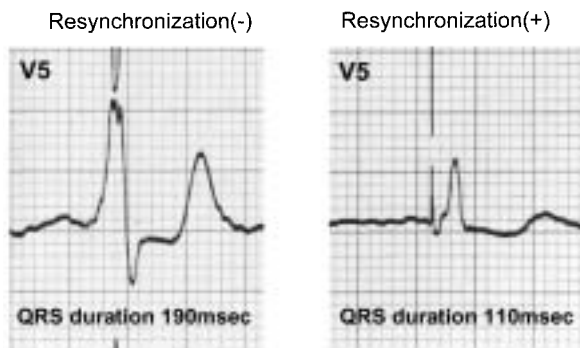
Soon after the resynchronization therapy was initiated, the QRS duration decreased to 110 msec (**Fig. 2 - right**). The day after successfully performing the resynchronization therapy, the patient regained her appetite and stopped complaining of shortness of breath. Within 3 days, dopamine, nitrate and diuretic therapy were terminated without worsening of the heart failure. The NYHA classification improved from class to . Seven days after the procedure, the cardiac size decreased to 53% (**Fig. 1 - right**). The ejection fraction increased to 15%. Mitral regurgitation diminished to trivial soon after the procedure.

Two weeks after the procedure, cardiac output and ventricular wall motion were evaluated without cardiac pacing and during pacing at various AV delay intervals. Cardiac output was measured using a cardiac bio-impedance device (Physio Flow, Manatec). Bio-impedance was measured using two leads placed on the thorax and the neck. After calibration for 15 sec, cardiac output was measured every 15 sec. The accuracy of the method had been determined previously<sup>5</sup>). This new impedance method is based on analysis of instant thoracic impedance variations, using six electrodes [two for electrocardiography (measurement of heart rate) and four for impedance cardiography]. Measured parameters are heart rate, cardiac index, and thoracic flow inversion time (active period of left ventricular ejection). Stroke volume is derived from cardiac index and thoracic flow inversion time.

Cardiac output = heart rate × stroke volume  
Translational motion of the left ventricular free



**Fig. 1** Chest roentgenograms obtained before and after the start of cardiac resynchronization therapy. The cardiac size decreased by 21% after resynchronization therapy was started. CTR = cardiothoracic ratio.



**Fig. 2** Electrocardiogram findings before and after cardiac resynchronization therapy

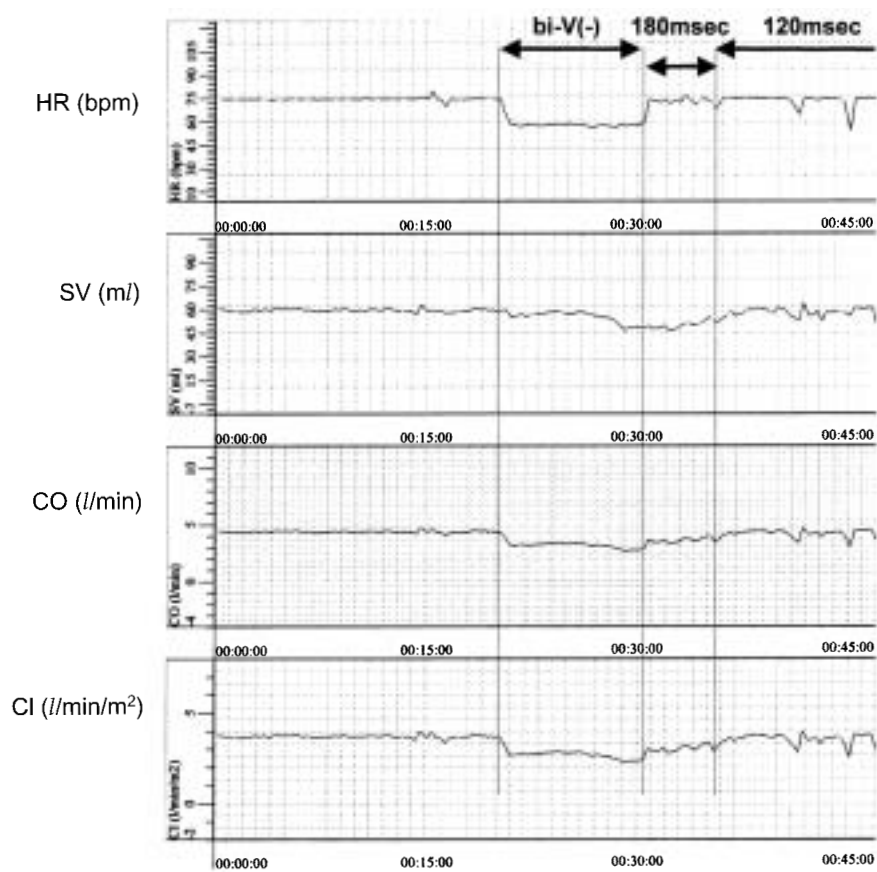
wall and ventricular septum was measured using the tissue tracking imaging method (Vivid Five, GE Medical Systems) as previously reported<sup>8</sup>). After acquiring the four-chamber view with a 2.5-MHz phase-array transducer, regions of interest were selected for the left ventricular free wall and ventricular septum for the evaluation of tissue movement. Myocardial tissue pulse-Doppler velocity profile signals were reconstituted offline from the tissue Doppler color images that provided regional myocardial velocity curves. The onset of myocardial contraction, *i.e.*, the point at which the tissue starts to displace toward the apex and the velocity curve exceeds 0.0 cm/sec was measured to evaluate

the time difference of the onset between the free wall and the ventricular septum.

Assessments of cardiac output and ventricular wall motion were performed under three pacing conditions: Without pacing; at an AV interval of 180 msec; and at an AV interval of 120 msec. Pacing was performed at 75/min. As shown in **Fig. 3**, cardiac output, stroke volume and cardiac index abruptly decreased soon after pacing was stopped, but all quickly improved after pacing at 75/min and an AV interval of 180 msec was started. There was further improvement when the AV interval was decreased to 120 msec. Cardiac output at an AV interval of 120 msec was 28% higher than that without resynchronization. The phase difference of ventricular wall motion was evaluated as the time difference between the onset of septal contraction and free-wall contraction (**Fig. 4**). The phase difference decreased from 190 to 170 msec when resynchronization therapy was performed at an AV interval of 180 msec, and improved further to 150 msec when the AV interval was decreased to 120 msec (**Fig. 5**).

## DISCUSSION

The present case demonstrates the usefulness of impedance cardiography and tissue Doppler echocardiography in the evaluation of the effect of cardiac resynchronization therapy on cardiac func-



**Fig. 3 Serial changes in heart rate, stroke volume, cardiac output and index during different atrioventricular delay intervals**

Cardiac output increased 29% during resynchronization with an atrioventricular interval of 120msec.

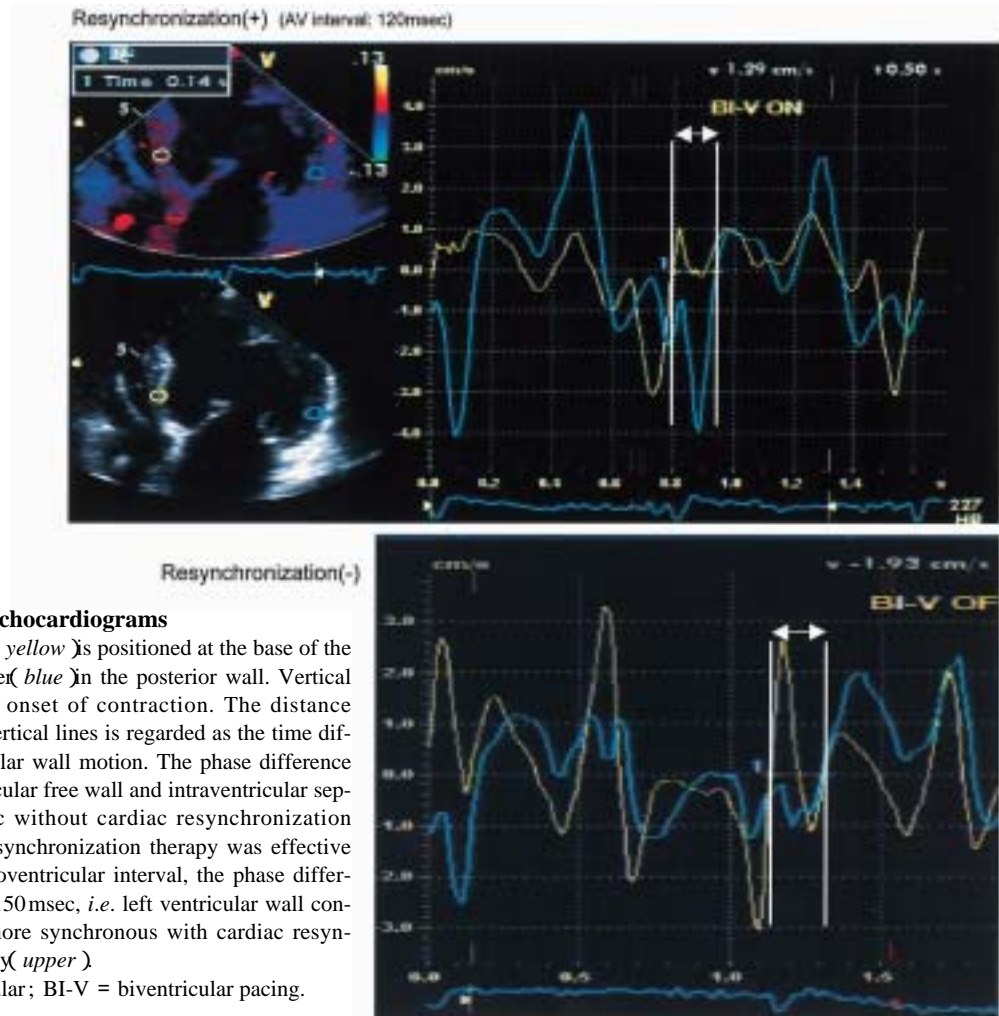
HR = heart rate; SV = stroke volume; CO = cardiac output; CI = cardiac index; bi-V = biventricular pacing.

tion. Using impedance cardiography, the cardiac output could be assessed easily and non-invasively. Furthermore, the use of tissue Doppler echocardiography could determine the optimum phase delay of the ventricular wall motion.

The main symptoms of heart failure are shortness of breath and fatigue. Diminished cardiac output induces fatigue by limiting increases in blood flow to the working skeletal muscle during exercise, which increases anaerobic metabolism. Impaired cardiac output also augments the ventilatory response during exercise because of increased ventilation-perfusion mismatching. Therefore, maintenance of cardiac output is critical in patients with heart failure, and so whether cardiac resynchronization therapy increases cardiac output when pacemaker implantation is performed is important to determine.

Cardiac output is often measured using the ther-

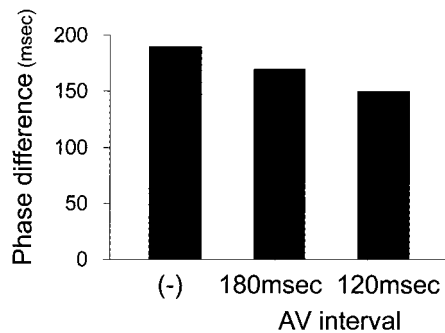
modulation technique with a pulmonary arterial catheter. However, this catheter sometimes interferes with the positioning of the pacing lead that is lodged in the coronary sinus. Also, repetitive use of 10-ml saline injections during the determination of cardiac output sometimes affects the blood volume. Therefore, other devices to measure cardiac output are needed. Impedance cardiography<sup>5,6</sup> can evaluate cardiac output non-invasively at the time of biventricular pacemaker implantation. Using this technique, the pacing lead can be reinserted into a different branch of the coronary sinus if the increase in the cardiac output is inadequate. Moreover, unlike conventional impedance methods, positioning of electrodes is not critical, and special electrodes or skin cleansing are not required. In addition, no estimation of the cylinder or truncated cone model is needed. Thus, impedance cardiography using Physio Flow enables easy and accurate non-



**Fig. 4 Tissue Doppler echocardiograms**

One Doppler point (yellow) is positioned at the base of the septum, and another (blue) in the posterior wall. Vertical line indicates the onset of contraction. The distance between the two vertical lines is regarded as the time difference of ventricular wall motion. The phase difference between the ventricular free wall and intraventricular septum was 190 msec without cardiac resynchronization (lower). When resynchronization therapy was effective with 120 msec atrioventricular interval, the phase difference improved to 150 msec, i.e. left ventricular wall contraction became more synchronous with cardiac resynchronization therapy (upper).

AV = atrioventricular; BI-V = biventricular pacing.



**Fig. 5 Serial changes in the intraventricular phase difference at different atrioventricular intervals**

Abbreviation as in Fig. 4.

invasive evaluation of cardiac output.

In this case, although the patient's heart rate decreased to 57 beats/min when pacing was stopped, this did not completely explain the decrease in cardiac output, because the patient's

stroke volume also decreased after pacing was stopped. Therefore, the decrease in cardiac output was partly due to increased asynchronous movement of ventricular wall. The left ventricular ejection fraction increased minimally after cardiac resynchronization therapy. The ejection fraction was evaluated using the Teichholz method. Based on this method, if the left ventricular diastolic and systolic dimensions are similar before and after resynchronization therapy, the ejection fraction is similar, although the timing of the contraction is altered. Therefore, the ejection fraction did not increase although our patient's symptoms improved.

The main mechanism responsible for the beneficial effect of biventricular pacing is attenuation of intraventricular asynchrony. Tissue Doppler echocardiography enabled us to evaluate how much the phase delay is improved by biventricular pacing. In our patient, the phase delay decreased by

30 msec after starting resynchronization therapy and cardiac output increased 28%. When the AV interval was set at 180 msec, the phase delay increased.

Impedance cardiography and tissue Doppler echocardiography are useful for evaluating the ben-

eficial effect of cardiac resynchronization therapy and determining the optimal AV delay interval.

#### Acknowledgment

The authors wish to thank Mr. Tomoyoshi Saito and Mr. Tsutomu Nakajima for their technical assistance.

### 要 約

拡張型心筋症に対して両心室ペーシング療法を施行し、  
インピーダンス心拍出量計と定量的組織ドップラーエコー法  
によって効果判定を行った1例

安達 仁 平辻 知也 櫻井 繁樹 多田 浩 外山 卓二  
内藤 滋人 星崎 洋 大島 茂 谷口 興一

両心室ペーシング療法の効果判定は重要だが、簡潔で非侵襲的な方法は確立されていない。組織ドップラーエコー図法とインピーダンス心拍出量計を用いて簡便かつ非侵襲的に両心室ペーシング療法の効果を判定したので報告する。

83歳、女性の拡張型心筋症に対して両心室ペーシング療法を施行した。2週間後、両心室ペーシング作動時および非作動時においてインピーダンス心拍出量計により心拍出量を、組織ドップラーエコー図法により心室中隔および左室自由壁運動の位相差を検討した。房室伝導時間を120 msecにした両心室ペーシング作動時、心拍出量は3.5から4.5 l/minに増加した。壁運動位相差は作動時には190から150 msecに減少した。房室伝導時間が180 msecでは、心拍出量と位相差はそれぞれ4.6 l/minと170 msecに変化した。これらの方法は簡潔に非侵襲的に行われ、両心室ペーシング療法の効果判定に有用であった。

*J Cardiol* 2003 Jul; 42(1): 37-42

#### References

- 1) Hochleitner M, Hortnagl H, Ng CK, Hortnagl H, Gschnitzer F, Zechmann W: Usefulness of physiologic dual-chamber pacing in drug-resistant idiopathic dilated cardiomyopathy. *Am J Cardiol* 1990; **66**: 198 - 202
- 2) Brecker SJ, Xiao HB, Sparrow J, Gibson DG: Effects of dual-chamber pacing with short atrioventricular delay in dilated cardiomyopathy. *Lancet* 1992; **340**: 1308 - 1312
- 3) Abraham WT, Fisher WG, Smith AL, Delurgio DB, Leon AR, Loh E, Kocovic DZ, Packer M, Clavell AL, Hayes DL, Ellestad M, Trupp RJ, Underwood J, Pickering F, Truex C, McAtee P, Messenger J, MIRACLE Study Group: Multicenter InSync Randomized Clinical Evaluation: Cardiac resynchronization in chronic heart failure. *N Engl J Med* 2002; **346**: 1845 - 1853
- 4) Gras D, Leclercq C, Tang AS, Bucknall C, Luttikhuis HO, Kirstein-Pedersen A: Cardiac resynchronization therapy in advanced heart failure the multicenter InSync clinical study. *Eur J Heart Fail* 2002; **4**: 311 - 320
- 5) Charloux A, Lonsdorfer-Wolf E, Richard R, Lampert E, Oswald-Mammosser M, Mettauer B, Geny B, Lonsdorfer J: A new impedance cardiograph device for the non-invasive evaluation of cardiac output at rest and during exercise: Comparison with the "direct" Fick method. *Eur J Appl Physiol* 2000; **82**: 313 - 320
- 6) Pianosi PT: Impedance cardiography accurately measures cardiac output during exercise in children with cystic fibrosis. *Chest* 1997; **111**: 333 - 337
- 7) Miyatake K, Yamagishi M, Tanaka N, Uematsu M, Yamazaki N, Mine Y, Sano A, Hirama M: New method for evaluating left ventricular wall motion by color-coded tissue Doppler imaging: In vitro and in vivo studies. *J Am Coll Cardiol* 1995; **25**: 717 - 724
- 8) Yu CM, Chau E, Sanderson JE, Fan K, Tang MO, Fung WH, Lin H, Kong SL, Lam YM, Hill MR, Lau CP: Tissue Doppler echocardiographic evidence of reverse remodeling and improved synchronicity by simultaneously delaying regional contraction after biventricular pacing therapy in heart failure. *Circulation* 2002; **105**: 438 - 445