

Three-Dimensional Analysis of Left Ventricular Geometry Using Magnetic Resonance Imaging : Feasibility and Comparison With Echocardiographic Analysis

Masahito MORIUCHI, MD, FJCC
 Satoshi SAITO, MD, FJCC
 Yuji KASAMAKI, MD
 Kouichi KOMAKI, MD, FJCC
 Katsuo KANMATSUSE, MD, FJCC
 Kazumasa HAYASAKA, MD*

Abstract

Objectives. Reliability of left ventricular geometry assessed by echocardiography (Echo) using an assumed left ventricular mass (LVM) and one-dimensional eccentricity (relative wall thickness: RWT), remains questionable. This study evaluated the feasibility of three-dimensional left ventricular geometric analysis using magnetic resonance imaging (MRI).

Methods. Echocardiography and MRI were performed on 55 patients with hypertension. LVM was calculated using 0.8 (American Society of Echocardiography-cube LVM) + 0.6 g for Echo and the slice summation method for MRI. Eccentricity was determined by RWT (septal wall thickness + posterior wall thickness/left ventricular inner diameter) for Echo and LVM/1.05/left ventricular end-diastolic volume (LVEDV) ratio [MRI-mass volume/cavity (M/C) ratio] for MRI. Left ventricular geometry was classified into four patterns according to the presence/absence of left ventricular hypertrophy and abnormal/normal eccentricity (partition value: RWT = 0.44, MRI; M/C ratio = 2.0), and the patient distribution was compared between the two methods.

Results. Although the mean values for LVM were similar, the mean value for LVEDV by echocardiography was significantly higher ($p < 0.0001$) and the mean M/C ratio was significantly lower ($r = 0.004$) than those by MRI. There were widely dispersed LVM values at higher underlying values of LVM and significant correlations between MRI-LVEDV and MRI-LVM ($r = 0.87$) and between Echo-LVEDV and Echo-LVM ($r = 0.75$). There was a significant difference in patient distribution according to left ventricular geometric pattern between the two methods ($p < 0.01$). Concentric ($n = 18$) and eccentric hypertrophy ($n = 12$) were dominant patterns in Echo analysis, and concentric hypertrophy ($n = 23$) and concentric remodeling ($n = 21$) were dominant in MRI analysis. The left ventricular geometric patterns were different in 32 patients (58.0%). Inadequate LVEDV values in Echo were the primary cause of this phenomenon.

Conclusions. Left ventricular geometric analysis by Echo results in inaccurate values. Three-dimensional left ventricular geometric analysis using MRI provides more accurate information about left ventricular geometry.

J Cardiol 2003 Dec; 42(6): 249 - 260

Key Words

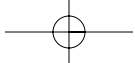
■Magnetic resonance imaging (three-dimensional) ■Echocardiography, transthoracic
 ■Hypertension ■Hypertrophy

日本大学医学部 内科学講座2, *放射線医学: 〒173-8610 東京都板橋区大谷口上町30-1

Division of Cardiology, Department of Internal Medicine, * Department of Radiology, Nihon University School of Medicine, Tokyo

Address for correspondence: MORIUCHI M, MD, FJCC, Division of Cardiology, Department of Internal Medicine, Nihon University School of Medicine, Oyaguchi Kami-cho 30-1, Itabashi-ku, Tokyo 173-8610

Manuscript received February 24, 2003; revised July 1 and August 8, 2003; accepted August 8, 2003



INTRODUCTION

Left ventricular hypertrophy has been recognized as important for the prognosis since the Framingham study showed an association between increased left ventricular mass (LVM) and significantly high cardiovascular mortality and morbidity^{1,2}). Echocardiographic assessment of left ventricular geometry is considered useful for improving risk stratification in hypertensive patients³). Numerous studies of the relationship between left ventricular geometry and clinical variables have found that concentric hypertrophy associated with increased LVM and abnormal left ventricular eccentricity is a strong predictor of cardiovascular death, myocardial infarction and stroke, compared to other geometric patterns such as eccentric hypertrophy, concentric remodeling and normal geometry⁴⁻¹³). However, echocardiography (Echo) has inherent limitations in assessing left ventricular geometry. For instance, M-mode echocardiography utilizes a complex analytic model of LVM that requires a number of assumptions and is validated only in the normal left ventricle¹⁴), although abnormal geometry is more common in hypertensive subjects³). Using relative wall thickness (RWT) as an index of eccentricity also introduces uncertainties because RWT is calculated from one-dimensional values (septal and posterior wall thickness and left ventricular internal diameter) in a single plane of the cardiac chamber³). Therefore, it is questionable whether this value can accurately represent the entire heart.

Magnetic resonance imaging (MRI) is currently the most accurate method for determining LVM¹⁵⁻¹⁷). MRI can include the entire heart in a set of parallel topographic images, so LVM can be measured three-dimensionally without any assumptions. In addition, simultaneous measurements of left ventricular cavity volume are also possible using the cine-MRI method, which can determine the relationship between LVM and left ventricular cavity volume^{18,19}).

The present study investigated the feasibility and effectiveness of three-dimensional analysis using MRI and clarified why echocardiography failed to adequately measure LVM and correctly assess left ventricular geometry.

METHODS AND SUBJECTS

Echocardiography

Two doctors unaware of the MRI results performed M-mode echocardiography using Secuoia, Acuson and Vivid 7 equipment (GE Yokokawa) with a 3.75-MHz transducer. Correct alignment of the cursor was performed under two-dimensional guidance in the parasternal long-axis view. Measurements of interventricular septal thickness (IVS), posterior wall thickness (PW) and left ventricular internal diameter (LVID) were made at end-diastole and end-systole as recommended by the American Society of Echocardiography²⁰). Left ventricular mass was calculated according to the following Devereux formula¹⁴):

$$LVM = 0.8 \{ 1.04 (IVS + LVID + PW)^3 - (LVID^3) \} + 0.6 \dots\dots\dots (1)$$

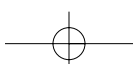
where 1.04 is the specific gravity of the myocardium in echocardiography.

LVM was then indexed to body surface area to determine the left ventricular mass index (LVMI).

Left ventricular hypertrophy was considered to be present if LVMI was > 116 g/m² in men or 104 g/m² in women²¹). RWT was calculated as 2 × the end diastolic PW/left ventricular radius³). Hypertrophy was considered concentric if RWT was > 0.44 and eccentric if RWT was normal. Patients with normal LVM were considered to have normal left ventricular geometry if RWT was ≤ 0.44 or concentric remodeling if RWT was > 0.44. Left ventricular end-diastolic volume (LVEDV) was calculated as 0.8 × LVID^{3 14}). Intra-observer variability in LVM measurements using the Devereux formula was assessed in a separate study comprised of 13 subjects. Two investigators unaware of the clinical status interpreted all echocardiograms. The mean coefficient of variation between the two observers was 5.9% at a 95% confidence interval of 0.8 - 11.0.

Magnetic resonance imaging

MRI was performed using a 1.5-Tesla superconductive magnet system (Siemens Magnetom Vision). Electrocardiographically-triggered gradient echo (white-blood) cine MRI images were obtained 0 and 40 msec after the R wave with an echo time of 4.8 msec. Slice thickness was 6mm. Five parallel short-axis image planes perpendicular to the long axis were identified on the horizontal long-axis view. The basal and apical planes were



first located. The basal plane passed just below the mitral valves and cut through the muscular septum, whereas the apical plane passed just above the apical myocardium. The remaining three midventricular image planes were then defined equidistant between the apical and the basal planes. The five short-axis and long-axis images were acquired at end-diastole. Endocardial and epicardial borders as well as the papillary muscles were traced manually in each slice. LVM area and cavity area were calculated in diastole using the MRI scanner. Total mass volume and LVEDV were calculated after the summation of slices and LVM was obtained by multiplying by the specific gravity (1.05 g/ml). Left ventricular hypertrophy was considered present if LVMI was > 114 g/m² in men or 96 g/m² in women²²).

Intra-observer variability in LVM measurements was assessed by two observers unaware of clinical status in a separate study comprised of 14 patients. One of the observers repeated LVM measurements for intra-observer variability. The mean coefficient of variation between the two observers was 2.0 ± 1.8% (95% confidence interval for limits of agreement at 7.1%). The hospital ethics committee approved this study, and informed consent was obtained from all patients.

Determination of three-dimensional eccentricity

Three-dimensional left ventricular geometric classification used LVM volume/cavity volume ratio (mass volume/cavity (M/C) ratio) as a determinant of three-dimensional eccentricity. With MRI, the M/C ratio is directly obtained by LVM/1.05/LVEDV (MRI-M/C ratio). To understand the relationship between RWT and the Echo-M/C ratio and to seek a partition value of the M/C ratio, we used Devereux's formula (1):

$$\begin{aligned} \text{Echo-M/C ratio} &= \text{LVM volume/cavity volume} \\ &= \text{LVM}/1.04/\text{cavity volume} \\ \text{LVM volume} &= [0.8 \{ 1.04 (\text{IVS} + \text{LVID} + \text{PW})^3 - (\text{LVID}^3) \}] + 0.6 \times 1.04 \\ &= 0.8 \{ (\text{IVS} + \text{LVID} + \text{PW})^3 - (\text{LVID}^3) \} + 0.58 \end{aligned}$$

$$\begin{aligned} \text{Because cavity volume} &= 0.8 \times \text{LVID}^3 \\ \text{Echo-M/C ratio} &= [0.8 \{ (\text{IVS} + \text{LVID} + \text{PW})^3 - (\text{LVID}^3) \}] + 0.58 \div 0.8 \times \text{LVID}^3 \\ &= [\{ (\text{IVS} + \text{LVID} + \text{PW})^3 - (\text{LVID}^3) \} + 0.725] \div \text{LVID}^3 \\ &= \{ (\text{IVS} + \text{LVID} + \text{PW})^3 - (\text{LVID}^3) \} \div \text{LVID}^3 + 0.725/\text{LVID}^3 \end{aligned}$$

M / C ratio

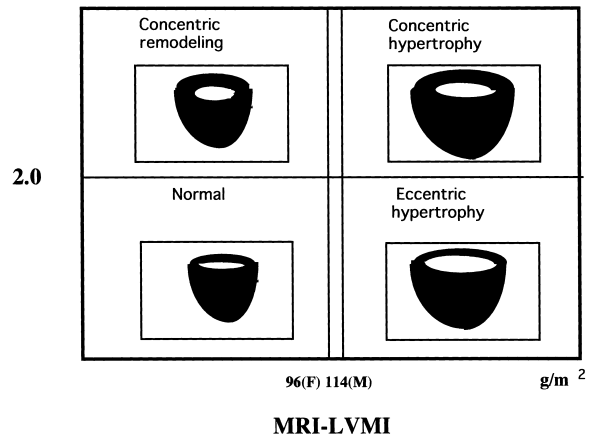


Fig. 1 Three-dimensional left ventricular geometric classification

Partition value of M/C ratio was 2.0. 96 (F) 114 (M): Cut-off values for left ventricular hypertrophy in females and males were 96 g/m² and 114 g/m², respectively. M/C ratio = left ventricular mass volume/left ventricular end-diastolic volume; MRI-LVMI = left ventricular mass index (left ventricular mass/body surface area) by magnetic resonance imaging.

where IVS is interventricular septal thickness, PW is posterior wall thickness, LVID is left ventricular internal diameter and 1.04 is the specific gravity of the myocardium in echocardiography.

Because 0.725/LVID³ is negligible,
 Echo-M/C ratio = { (IVS + LVID + PW)³ - LVID³ } / LVID³ (2)

Because RWT is defined as 2 × PW/LVID or (IVS + PW)/LVID,
 2 × PW / IVS + PW = RWT × LVID

then,
 IVS + LVID + PW = RWT × LVID + LVID = LVID × (RWT + 1)

Thus, if formula (2) is rewritten as
 { LVID³ × (RWT + 1)³ - LVID³ } / LVID³

then the following equation is obtained:
 Echo-M/C ratio = (RWT + 1)³ - 1
 If RWT is 0.44 (a partition value of RWT),
 Echo-M/C ratio = (0.44 + 1)³ - 1 = 1.99
 2.0

Thus, we defined the partition value of three-dimensional eccentricity as 2.0 (Fig. 1).

In our study, we used RWT calculated by (IVS + PW)/LVID because RWT calculated using (2 × PW/LVID²³).

Difference of LVM

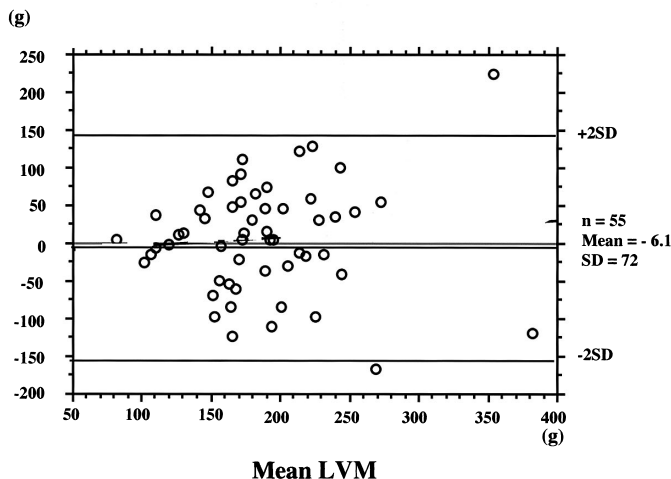


Fig. 2 Bland and Altman analysis

LVM estimates by MRI were mean 6.1 g smaller than those by echocardiography. The wide scatter within subjects for the two methods shows the poor comparability of MRI and echocardiography. LVM = left ventricular mass. Other abbreviation as in Fig. 1.

Statistical analysis

Values are expressed as the mean ± SEM. Linear regression analysis was used to determine the correlation between LVMI and LVEDV assessed with echocardiography and MRI, and to assess the relationship between RWT, the Echo-M/C ratio, and the MRI-M/C ratio. Comparisons between echocardiography and MRI were made using Student's *t*-test and chi-square test as appropriate. Comparisons between multiple groups was performed with Scheffe's post hoc test. In addition, a Bland and Altman analysis²⁴ was performed to determine the agreement between LVM by echocardiography and LVM by MRI. *p* < 0.05 was considered statistically significant.

RESULTS

Patient characteristics

This study included 55 patients with clinically stable hypertension treated with antihypertensive drugs and a salt-restricted diet. The 34 men and 21 women had a mean age of 62.2 ± 10.3 years. Treatment was conducted for a mean duration of 101 ± 93.1 months. Mean systolic/diastolic pressures were 140.3 ± 15.4/77.5 ± 14.2 mmHg, mean heart rate was 70.3 ± 10.9 beats/min, and mean ejection fraction was 78 ± 12%. Drugs administered to the patients included calcium antagonist (49%), beta blocker (31%), angiotensin-converting enzyme inhibitor (27%), angiotensin receptor-1 blocker (24%), alpha blocker (6%) and diuretic agents (20%). The mean interval between echocardiography and MRI was 20.7 ± 20.1 days.

Comparison of LVM, LVMI, LVM volume and LVEDV as determined by MRI and echocardiography

Mean values of LVM, LVMI, and LVM volume by echocardiography were slightly higher than those by MRI. However, the differences between the two methods were not statistically significant (191 ± 69 vs 186 ± 65 g, NS, 112 ± 34 vs 109 ± 35 g/m², NS, and 184 ± 66 vs 177 ± 62 ml, NS, for echocardiography and MRI, respectively). The LVMI correlation between the two methods was statistically significant but weak (*y* = 0.33*x* + 72, *r* = 0.33 by linear regression). Bland and Altman analysis showed a mean difference of -6.1 g in the value of LVM between the two methods. The mean differences, calculated as 1.96 × the standard deviation (SD) of the difference at a 95% confidence interval, were +65.9 g and -78.1 g (Fig. 2).

The LVEDV mean value by echocardiography was significantly higher than that by MRI (95.0 ± 33.0 vs 73.4 ± 23.0 ml, *p* < 0.0001; Fig. 3 - left), and the LVEDV correlation between the two methods was statistically significant (*y* = 0.31*x* + 44, *r* = 0.43; Fig. 3 - right). However, higher and lower values of LVEDV by echocardiography were observed in 38 patients (69.1%) and 17 patients (30.9%), respectively, compared to those by MRI.

RWT, Echo-M/C ratio, and MRI-M/C ratio

The mean RWT, Echo-M/C ratio and MRI-M/C ratio were 0.43 ± 0.09, 1.93 ± 0.56 and 2.41 ± 0.46, respectively. There was no correlation between RWT and the MRI-M/C ratio (*y* = 0.1*x* + 2.5, *r* = 0.004 by linear regression). The mean

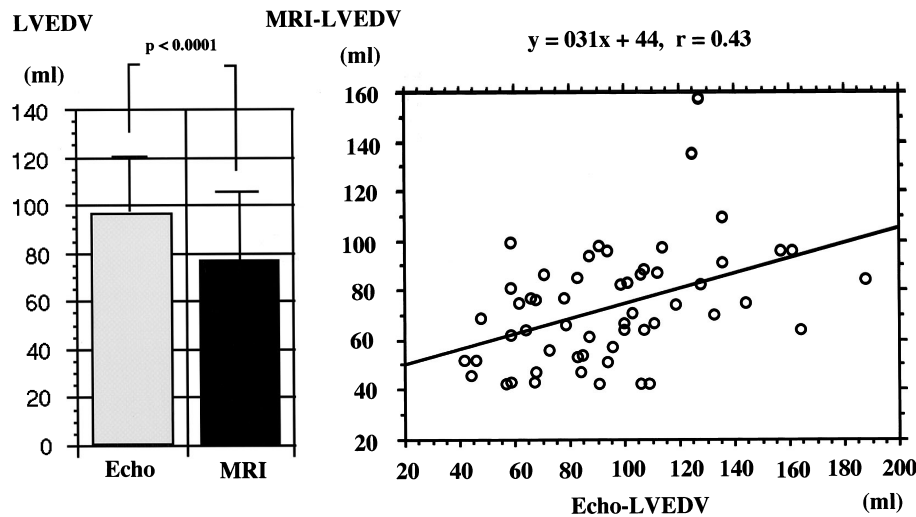


Fig. 3 Comparison of mean values of left ventricular end-diastolic volume between echocardiography and magnetic resonance imaging (left) and correlation of left ventricular end-diastolic volume by echocardiography and magnetic resonance imaging (right)
 LVEDV determined by echocardiography was significantly higher than that by MRI ($p < 0.0001$). Correlation of LVEDV between echocardiography and MRI was statistically significant ($y = 0.31x + 44$, $r = 0.43$ by linear regression).
 LVEDV = left ventricular end-diastolic volume; Echo = echocardiography. Other abbreviation as in Fig. 1.

MRI-M/C ratio was significantly higher than the Echo-M/C ratio ($p < 0.0001$; Fig. 4 - left). There was also no correlation between the Echo-M/C ratio and the MRI-M/C ratio ($r = 0.004$; Fig. 4 - right).

Correlation of LVEDV and LVM with MRI-mass/cavity and Echo-mass/cavity curves

Fig. 5 shows the relationships between LVEDV and LVM in MRI and echocardiography. The two cubic curves were constructed by calculating $1.05 \times$ the MRI-M/C ratio and $1.04 \times$ the Echo-M/C ratio. There were significant correlations between MRI-LVEDV and MRI-LVM ($r = 0.87$; Fig. 5 - left) as well as between Echo-LVEDV and Echo-LVM ($r = 0.75$; Fig. 5 - right). The two cubic curves were nearly identical until LVEDV reached 80 ml. After this point, LVM increased at a slower rate with echocardiography until LVEDV reached 140 ml, whereas LVM continued to increase at approximately the same rate in MRI.

Comparison of LVM measurements by MRI and echocardiography

LVM could be measured using the MRI-mass/cavity and Echo-mass/cavity curves (Fig. 5). MRI-LVM was calculated as MRI-LVEDV \times

$1.05 \times$ the MRI-M/C ratio, so the mean value for MRI-LVM (186 g) was obtained by taking 73.4 ml (mean value for MRI-LVEDV) multiplied by 2.53 g/ml ($1.05 \times$ mean MRI-M/C ratio). Echo-LVM (191 g) was also obtained from 95.0 ml (mean value for Echo-LVEDV) multiplied 2.01 g/ml ($1.04 \times$ mean Echo-M/C ratio). Based on this schema, the mean values for LVM appear to be quite similar, however, different mechanisms, i.e. different LVEDV values and different M/C ratios, were used for in calculating LVM in the two methods. In addition, both values for Echo-LVEDV and Echo-LVM were never the same for the two methods in the present study.

Comparison of left ventricular geometric patterns by MRI and echocardiography

Fig. 6 shows the patient distribution according to the left ventricular geometric classification obtained by echocardiography and MRI. There was a significant difference in patient distribution according to the left ventricular geometric pattern between the two methods ($p < 0.01$). The echocardiographic geometric classification showed 18 patients (32.7%) had concentric hypertrophy, 12 patients (21.8%) eccentric hypertrophy, 9 patients (16.4%) concentric remodeling, and 16 patients (29.1%) normal geome-

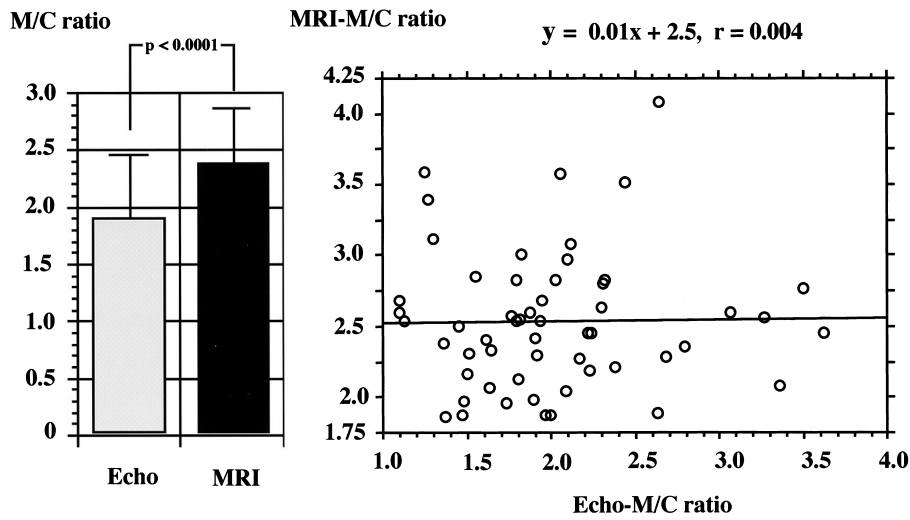


Fig. 4 Comparison of mean M/C ratios between echocardiography and magnetic resonance imaging (left) and correlation of M/C ratio by echocardiography and magnetic resonance imaging (right)
 M/C ratio determined by MRI was significantly higher than that by echocardiography ($p < 0.0001$). There was no correlation between the Echo-M/C ratio and MRI-M/C ratio ($y = 0.01x + 2.5$, $r = 0.004$ by linear regression).
 Abbreviations as Figs. 1, 3.

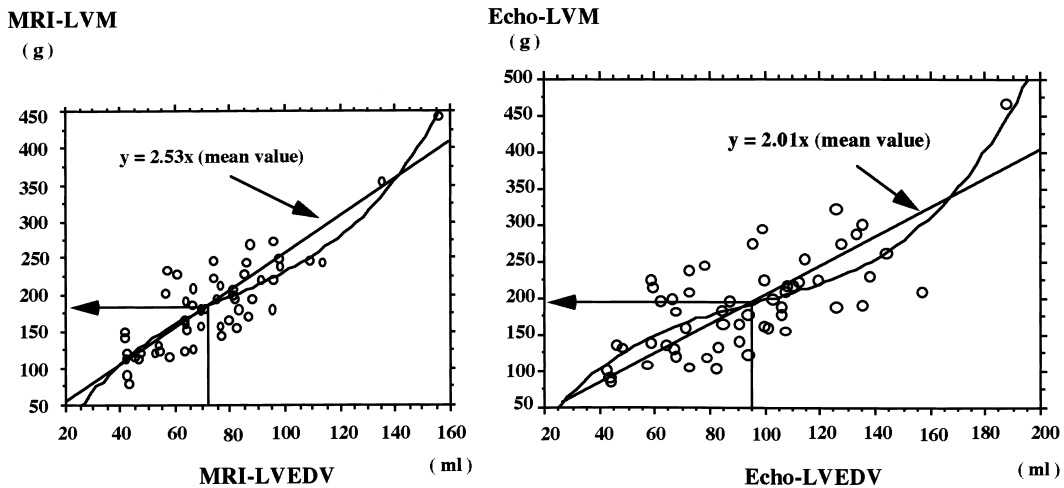


Fig. 5 Correlation of left ventricular end-diastolic volume and left ventricular mass by magnetic resonance imaging and echocardiography: MRI-mass/cavity curve (left) and Echo-mass/cavity curve (right)
 There were close correlations between LVEDV and LVM in MRI [$y = -113 + 0.1x - 0.78x^2 + (3.2E-4)x^3$, $r = 0.87$] (left) and in echocardiography [$y = -83 + 6.7x - 0.6x^2 + (2.6E-4)x^3$, $r = 0.75$] (right).
 Abbreviations as in Figs. 1-3.

try. In contrast, the MRI geometric classification showed 24 patients (43.6%) had concentric hypertrophy, 2 patients (3.6%) eccentric hypertrophy, 23 patients (41.8%) concentric remodeling, and 6 patients (10.9%) normal geometry. Thus, the number of patients with hypertrophy was higher with

the echocardiographic geometric classification compared to the MRI geometric classification (30 vs 26, 54.5% vs 47.3%). Furthermore, the number of patients with abnormal eccentricity (M/C ratio ≥ 2.0) was higher in the MRI geometric classification compared to the echocardiographic geometric clas-

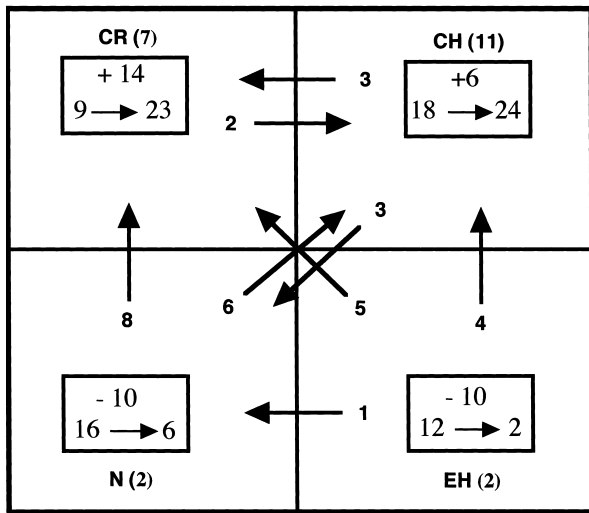


Fig. 6 Changes in patient distribution from the echocardiographic geometric classification to the magnetic resonance imaging geometric classification

Numbers in parentheses indicate patients who remained in the same geometric pattern.

Upper square box: Increased or decreased number of patients.

Lower square box: Number of the patients before and after changing the geometric classification from echocardiography to magnetic resonance imaging. Thick arrows indicate the directions of new geometric patterns.

CR = concentric remodeling; CH = concentric hypertrophy; N = normal geometry; EH = eccentric hypertrophy.

sification (47 vs 27, 85.5% vs 49.1%, $p < 0.01$).

The M/C ratio increased in 39 of 55 patients (70.9%) and decreased in 16 patients (29.1%) if the geometric classification was changed from echocardiography to MRI. The number of patients with abnormal eccentricity increased in 23 patients and decreased in only 3 patients. The LVMI values increased in 24 patients and decreased in 31 patients if the method of geometric classification was changed from echocardiography to MRI. The number of patients with hypertrophy decreased in 12 patients and increased in 8 patients.

Changes in M/C ratio and LVMI subsequently caused changes in the geometric patterns of 32 patients (58.2%): 3 patients from concentric hypertrophy to normal geometry, 3 patients from concentric hypertrophy to concentric remodeling, 4 patients from eccentric hypertrophy to concentric hypertrophy, 5 patients from eccentric hypertrophy to concentric remodeling, 1 patient from eccentric

hypertrophy to normal geometry, 6 patients from normal geometry to concentric hypertrophy, 8 patients from normal geometry to concentric remodeling and 2 patients from concentric remodeling to concentric hypertrophy. The left ventricular geometric pattern remained unchanged in only 23 of 55 patients (41.8%; Fig. 6)

Effect of changing geometric classification on variables

Table 1 shows the changes in the MRI-M/C ratio, Echo-M/C ratio, and LVM and LVEDV values that occurred if the geometric classification was changed from echocardiography to MRI. The echocardiographic geometric classification showed the Echo-M/C ratios were significantly higher in concentric hypertrophy and concentric remodeling, the LVM values were significantly higher in concentric hypertrophy and eccentric hypertrophy, and the value of LVEDV was highest in eccentric hypertrophy. There were no statistical differences in the M/C ratios of all geometric patterns. The MRI geometric classification showed the MRI-M/C ratios were significantly higher in concentric hypertrophy and concentric remodeling, and the LVM values were significantly higher in concentric hypertrophy and eccentric hypertrophy. The highest LVEDV value occurred with eccentric hypertrophy, although no statistical significance was noted because there was only a small number of patients with eccentric hypertrophy. All LVM and LVEDV values were approximately 5% to 30% lower with the MRI geometric classification compared to the echocardiographic geometric classification. To determine the reliability of the echocardiographic geometric classification, we re-examined the LVM and LVEDV values using MRI data from the same patients. We found that there were no statistical differences in the LVM and LVEDV values in any of the geometric patterns, although the LVM values were still highest in concentric hypertrophy.

DISCUSSION

Comparison between the LVM measurements by echocardiography and MRI

LVM measurements according to the American Society of Echocardiography-recommended (Deveurex) formula are universally accepted and widely described in the literature¹⁴. However, the accuracy of this method has recently been questioned. This formula assumes the ventricle is a trun-

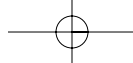


Table 1 Changes in variables according to the left ventricular geometric patterns calculated by three different methods

		CH	CR	EH	N
		n	n	n	n
		18	9	12	16
A	MRI-M/C ratio	2.49 ± 0.6	2.46 ± 0.2	2.30 ± 0.44	2.42 ± 0.38
	Echo-M/C ratio	2.36 ± 0.33 [‡]	2.07 ± 0.33	1.66 ± 0.21	1.57 ± 0.16
	LVM	248 ± 70 [†]	155 ± 33	202 ± 44	138 ± 35
	LVEDV	101 ± 35	72 ± 13	117 ± 31	85 ± 25
B	MRI-M/C ratio	2.49 ± 0.6	2.46 ± 0.2	2.30 ± 0.44	2.42 ± 0.38
	Echo-M/C ratio	2.36 ± 0.33 [‡]	2.07 ± 0.33	1.66 ± 0.21	1.57 ± 0.16
	LVM	214 ± 73	170 ± 31	179 ± 36	170 ± 75
	LVEDV	82 ± 26	66 ± 12	74 ± 16	67 ± 27
C	MRI-M/C ratio	2.62 ± 0.5 ^{§†}	2.41 ± 0.3 [†]	1.83 ± 0.07	1.82 ± 0.05
	Echo-M/C ratio	1.99 ± 0.33	2.05 ± 0.33	1.46 ± 0.00	1.92 ± 0.23
	LVM	231 ± 65 [†]	157 ± 36 [†]	175 ± 6	124 ± 26
	LVEDV	84 ± 26	62 ± 16	91 ± 7	65 ± 14

p < 0.0001 CH vs CR. *p* < 0.01 CH vs CR. [§]*p* < 0.001 CH vs EH. [†]*p* < 0.001 CH vs N. *p* < 0.01 CR vs EH. *p* < 0.001 CR vs N. *p* < 0.001 EH vs N. *p* < 0.05 EH vs N. □

A: Results obtained from geometric classification by echocardiography using echocardiographic data. □

B: Results obtained from geometric classification by echocardiography using MRI data. □

C: Results obtained from geometric classification by MRI using MRI data. □

Abbreviations as in Figs. 1 - 3, 6.

cated, ellipsoid cone with a long-axis/short-axis ratio of 2: 1. However, abnormal left ventricular geometry is more common in the human heart, especially in patients with hypertension³).

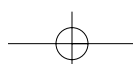
In fact, several studies comparing the accuracy of LVM measurements using echocardiography and MRI in humans¹⁵⁻¹⁷ reported that M-mode echocardiography overestimates LVM compared to MRI and that the difference in LVM between the two methods becomes greater with higher the underlying values of LVM¹⁵⁻¹⁷. Our results were consistent with these previous studies. Although there was no statistical significance, echocardiography slightly overestimated LVM compared to MRI, and Bland and Altman analysis showed that the distribution of LVM values became wider as values of LVM increased (Fig. 2).

The present study showed a significant correlation between Echo-LVEDV and Echo-LVM (Echo-mass/cavity curve, *r* = 0.75). In addition, simultaneous measurement of LVM and LVEDV using the cine MRI method could obtain the correct values for MRI-LVM and MRI-LVEDV, which led to a

significant correlation between MRI-LVEDV and MRI-LVM (MRI-mass/cavity curve, *r* = 0.87). Because LVM is calculated as the specific gravity × M/C ratio × LVEDV, the measurement of both LVEDV and M/C ratio appears to be absolutely necessary for determining the mechanisms of LVM measurements in both methods.

There was an approximately 30% overestimation of the mean value for LVEDV with echocardiography, although overestimated and underestimated LVEDV values were observed in 38 patients (69.1%) and 17 patients (30.9%), respectively. By evaluating the relationship between the difference of LVEDV and LVM values between the two methods, we found that the difference between Echo-LVEDV and MRI-LVEDV significantly influenced LVM measurements.

There was no statistical difference between the mean values of Echo-LVM and MRI-LVM in our study, possibly because the hearts were smaller compared to previous studies^{15,16}. The mean LVM values were less than 200 g in our patients and more than 200 g in patients from other studies. A



similar result was also reported showing quite similar mean values for LVM¹⁷).

RWT and M/C ratio

RWT is widely used as a determinant of eccentricity in echocardiographic geometric classification. The partition value of 0.44 was first used to represent approximately the 99th percentile value of normal subjects in order to maintain acceptable detection of abnormal left ventricular geometry³). In our study, by determining the relationship between RWT and the Echo-M/C ratio using the Devereux formula, we found that Echo-M/C ratio was a cubic function of RWT, Echo-M/C ratio = $(RWT + 1)^3 - 1$, and the partition value of the Echo-M/C ratio corresponding to the 0.44 RWT value was 2.0. This observation validated the use of the Echo-M/C ratio as an index of three-dimensional eccentricity. However, the mean value for the Echo-M/C ratio was significantly lower than that for the MRI-M/C ratio, which was directly obtained by MRI, and there was also no correlation between the Echo-M/C ratio and the MRI-M/C ratio. In our study, the mean values for LVM were similar between echocardiography and MRI, so the overestimation of Echo-LVEDV rather than MRI-LVEDV is attributable to lower M/C ratio in echocardiography. These results indicate the limited accuracy of echocardiography for measuring true eccentricity.

The MRI-mass/cavity curve had a better correlation than the Echo-mass/cavity curve ($r = 0.87$ vs 0.75 , respectively). The reasons for this result seem to be twofold: the difference in the number of variables that influence LVM calculation and LVEDV value, and also the difference in the measurement accuracy of these variables. MRI-M/C ratio is always calculated for MRI-LVM and MRI-LVEDV, which are known to be correct, whereas Echo-LVM can be influenced by IVS thickness, PW thickness, and LVID. In addition, the assumed Echo-LVEDV value ($0.8 \times LVID^3$) significantly influences the LVEDV value, and overestimation and underestimation of the Echo-LVEDV value can lead to widely dispersed LVM values. Thus, since these results support the validity of the cubic formula for LVM measurements, MRI provides a more accurate M/C ratio than echocardiography.

Currently, there are no reports evaluating the clinical usefulness of the M/C ratio, although the mass/cavity ratio is used as an index of left ventricular dysfunction¹⁸). Based on the present findings,

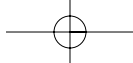
we assume that the MRI-M/C ratio can provide an important marker of the development of left ventricular hypertrophy.

Left ventricular geometric classifications: Echocardiography vs MRI

Patient distribution significantly differed between echocardiography and MRI classifications according to the left ventricular geometric pattern. Left ventricular geometry is defined by LVM, LVEDV and the M/C ratio, and the LVM, LVEDV values and M/C ratio differed for every patient according to the two methods in our study, so the left ventricular geometry will never be the same if comparing MRI and echocardiographic geometric classifications. Therefore, the significant differences seen in patient distribution between echocardiographic and MRI classification are not surprising. In fact, significant changes in both the M/C ratio values and the LVMI values occurred simultaneously in 14 patients when the method of geometric classification was changed from echocardiography to MRI. Accordingly, geometric changes from normal to concentric hypertrophy, and vice versa, occurred easily and most patients had abnormally increased eccentricity when the geometric classification changed from echocardiography to MRI (Fig. 6).

The inaccurate Echo-LVEDV values were the primary cause of the incorrect left ventricular geometry observed by echocardiography. Although $0.8 \times LVID^3$ for the LVEDV value is theoretically reasonable as long as Devereux's formula is used for LVM measurements, LVEDV values by M-mode echocardiography that were calculated using $0.8 \times LVID^3$ are known to be inaccurate²⁵). This may be the reason why many previous attempts to measure LVM have disregarded the LVEDV value¹⁵⁻¹⁷). However, our study demonstrated that an accurate LVEDV value is essential for accurate LVM measurement and the correct assessment of left ventricular geometry. These findings indicate that M-mode echocardiography is of limited value for the measurement of LVM and assessment of left ventricular geometry and may give rise to misunderstandings, so left ventricular geometric analysis by this method should be interpreted cautiously.

In spite of the inaccurate left ventricular geometric analysis by echocardiography, patients with concentric hypertrophy had more severe disease and poorer prognosis compared to other geometric pat-



terns^{2,4,6,12}). This is probably because the echocardiographic geometric classification provides partially correct information about LVM and LVEDV in patients with concentric hypertrophy. In our study, although re-examination using the values of MRI-LVM and MRI-LVEDV showed no statistical significance in relation to LVM and LVEDV values by the echocardiographic geometric classification, the LVM value in concentric hypertrophy was still higher than the values found in other geometric patterns (Table 1). This hypothesis is supported by the fact that 12 of 18 patients (66.7%) with concentric hypertrophy by the echocardiographic geometric classification still remained in the same category after changing from geometric to MRI classification.

In contrast to echocardiography, MRI can accurately measure LVM and LVEDV and detect three-dimensional eccentricity without any assumptions, so this method should be the gold standard for evaluating left ventricular geometry.

Study limitations

Only a few subjects were examined in this study and the LVM was relatively small compared to pre-

vious studies^{15,16}). Only 5 short-axis slices were used for the MRI measurement. Undoubtedly, more slices would increase the accuracy of this technique. Recent technological improvements now allow for 10 short-axis slices. Although we used a partition value of 2.0 as the MRI-M/C ratio, this value originated from the RWT value of 0.44 in the echocardiographic geometric classification. Therefore, we hope to find a more adequate partition value for three-dimensional geometric classification by MRI that represents approximately the 99th percentile value in normal subjects.

CONCLUSIONS

Accurate assessment of left ventricular geometry is assuming greater importance for determining the severity, prognosis and therapeutic efficacy of patients with hypertension. The present study clearly demonstrated that three-dimensional geometric analysis using MRI is feasible and that this method can provide a more accurate assessment of left ventricular geometry than the conventional left ventricular geometric classification by M-mode echocardiography. Further studies are needed to confirm the clinical usefulness of this method.

要 約

磁気共鳴画像による三次元的左室形態評価の意義: 心エコー図法との対比

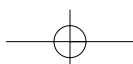
森内 正人 斎藤 穎 笠巻 祐二

小牧 宏一 上松瀬勝男 早坂 和正

目的: 心エコー図法による左室形態の評価法は, 推定された左室心筋重量(LVM)と一次元的な偏心性の指標である相対的左室肥厚度(RWT)を用いており, その信頼性には疑問がある. 本研究の目的は, 左室心筋重量測定のgold standardである磁気共鳴画像(MRI)により三次元的左室形態評価の可能性を検討し, その重要性を明らかにすることである.

方法: 高血圧患者55例で心エコー図法とMRIを施行し, それぞれの方法(心エコー図法: $0.8(\text{ASE-cube LVM}) + 0.6\text{g}$ の式, MRI: 左室の短軸スライス断面のSimpson法)により左室心筋重量を求めた. 偏心性の指標は心エコー図法ではRWT, MRIでは心筋重量/心筋比重(1.05)拡張末期容量(MRI-M/C ratio)を用いた. RWT[(左室中隔厚+左室後壁厚)/左室内腔径]は0.44, Echo-M/C ratioは2.0を境界値とし, 左室肥大の有無と併わせ左室形態を比較した.

結果: 平均左室重量には両者に差がないが, 心エコー図法ではMRIに比べ左室拡張末期容量が大きく($p < 0.0001$), M/C ratioは小さかった($r = 0.004$). 心筋重量の増大とともに両者の差は大きくなった. 拡張末期容量と心筋重量には両者に良好な相関が認められた(MRI: $r = 0.87$, 心エコー図法: $r = 0.75$). 左室形態は心エコー図法では, 求心性肥大(18例)と遠心性肥大(12例)が多く, MRIでは求心性肥大(24例)と求心性リモデリング(23例)の頻度が高かった. 心エコー図法における推定左室拡張末期容量の不正確さがこれらの原因と考えられた. 両者の左室形態は32例(58.2%)で異なっていた.

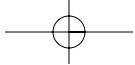


結論: 心エコー図法による左室形態評価は不正確である。MRIによる三次元的左室形態評価が可能であり、その臨床的有用性が示唆された。

J Cardiol 2003 Dec; 42(6): 249 - 260

References

- 1) Levy D, Garrison RJ, Savage DD, Kannel WB, Castelli WP: Prognostic implications of echocardiographically determined left ventricular mass in the Framingham Heart Study. *N Engl J Med* 1990; **322**: 1561 - 1566
- 2) Verdecchia P, Carini G, Circo A, Dovellini E, Giovannini E, Lombardo M, Solinas P, Gorini M, Maggioni AP, the MAVI (MASSA Ventricolare sinistra nell'Ipertensione) Study Group: Left ventricular mass and cardiovascular morbidity in essential hypertension: The MAVI study. *J Am Coll Cardiol* 2001; **38**: 1829 - 1835
- 3) Ganau A, Devereux RB, Roman MJ, de Simone G, Pickering TG, Saba PS, Vargiu P, Simongini I, Laragh JH: Patterns of left ventricular hypertrophy and geometric remodeling in essential hypertension. *J Am Coll Cardiol* 1992; **19**: 1550 - 1558
- 4) Koren MJ, Devereux RB, Casale PN, Savage DD, Laragh JH: Relation of left ventricular mass and geometry to morbidity and mortality in uncomplicated essential hypertension. *Ann Intern Med* 1991; **114**: 345 - 352
- 5) Verdecchia P, Schillaci G, Borgioni C, Ciucci A, Battistelli M, Bartoccini C, Santucci A, Santucci C, Reboldi G, Porcellati C: Adverse prognostic significance of concentric remodeling of the left ventricle in hypertensive patients with normal left ventricular mass. *J Am Coll Cardiol* 1995; **25**: 871 - 878
- 6) Verdecchia P, Schillaci G, Borgioni C, Ciucci A, Gattobigio R, Zampi I, Santucci A, Santucci C, Reboldi G, Porcellati C: Prognostic value of left ventricular mass and geometry in systemic hypertension with left ventricular hypertrophy. *Am J Cardiol* 1996; **78**: 197 - 202
- 7) Roman MJ, Pickering TG, Schwartz JE, Pini R, Devereux RB: Relation of arterial structure and function to left ventricular geometric patterns in hypertensive adults. *J Am Coll Cardiol* 1996; **28**: 751 - 756
- 8) Nishikimi T, Yoshihara F, Morimoto A, Ishikawa K, Ishimitsu T, Saito Y, Kangawa K, Matsuo H, Omae T, Matsuoka H: Relationship between left ventricular geometry and natriuretic peptide levels in essential hypertension. *Hypertension* 1996; **28**: 22 - 30
- 9) Ghali JK, Liao Y, Cooper RS: Influence of left ventricular geometric patterns on prognosis in patients with or without coronary artery disease. *J Am Coll Cardiol* 1998; **31**: 1635 - 1640
- 10) Kohara K, Zhao B, Jiang Y, Takata Y, Fukuoka T, Igase M, Miki T, Hiwada K: Relation of left ventricular hypertrophy and geometry to asymptomatic cerebrovascular damage in essential hypertension. *Am J Cardiol* 1999; **83**: 367 - 370
- 11) Bella JN, Wachtell K, Palmieri V, Liebson PR, Gerds E, Ylitalo A, Koren MJ, Pederson OL, Rokkedal J, Dahlöf B, Roman MJ, Devereux RB: Relation of left ventricular geometry and function to systemic hemodynamics in hypertension: The LIFE study: Losartan Intervention For Endpoint Reduction in Hypertension Study. *J Hypertens* 2001; **19**: 127 - 134
- 12) Oikarinen L, Nieminen MS, Viitasalo M, Toivonen L, Wachtell K, Papademetriou V, Jern S, Dahlöf B, Devereux RB, Okin PM: Relation of QT interval and QT dispersion to echocardiographic left ventricular hypertrophy and geometric pattern in hypertensive patients: The LIFE study: The Losartan Intervention For Endpoint Reduction. *J Hypertens* 2001; **19**: 1883 - 1891
- 13) Cioffi G, Stefenelli C: Comparison of left ventricular geometry and left atrial size and function in patients with aortic stenosis versus those with pure aortic regurgitation. *Am J Cardiol* 2002; **90**: 601 - 606
- 14) Devereux RB, Alonso DR, Lutas EM, Gottlieb, Campo E, Sachs I, Reichek N: Echocardiographic assessment of left ventricular hypertrophy: Comparison to necropsy findings. *Am J Cardiol* 1986; **57**: 450 - 458
- 15) Bottini PB, Carr AA, Prisant LM, Flickinger FM, Allison JD, Gottdiener JS: Magnetic resonance imaging compared to echocardiography to assess left ventricular mass in the hypertensive patient. *Am J Hypertens* 1995; **8**: 221 - 228
- 16) Missouriis CG, Forbat SM, Singer DRJ, Markandu ND, Underwood R, MacGregor GA: Echocardiography overestimates left ventricular mass: A comparative study with magnetic resonance imaging in patients with hypertension. *J Hypertens* 1996; **14**: 1005 - 1010
- 17) Myerson SG, Montgomery HE, World MJ, Pennell DJ: Left ventricular mass: Reliability of M-mode and 2-dimensional echocardiographic formulas. *Hypertension* 2002; **40**: 673 - 678
- 18) Foster RE, Johnson DB, Barilla F, Blackwell GG, Orr R, Roney M, Stanley AWH Jr, Pohost GM, Del'Italia LJ: Changes in left ventricular mass and volumes in patients receiving angiotensin-converting enzyme inhibitor therapy for left ventricular dysfunction after Q-wave myocardial infarction. *Am Heart J* 1998; **136**: 269 - 275
- 19) Kaji S, Yang PC, Kerr AB, Tang WH, Meyer CH, Macovski A, Pauly JM, Nishimura DG, Hu BS: Rapid evaluation of left ventricular volume and mass without breath-holding using real-time interactive cardiac magnetic resonance imaging system. *J Am Coll Cardiol* 2001; **38**: 527 - 533
- 20) Sahn DJ, DeMaria A, Kisslo J, Weyman A: Recommendations regarding quantitation in M-mode echocardiography: Results of a survey of echocardiographic measurements. *Circulation* 1978; **58**: 1072 - 1083
- 21) Okin PM, Devereux RB, Nieminen MS, Jern S, Oikarinen L, Viitasalo M, Toivonen L, Kjeldsen SE, Julius S, Dahlöf B: Relationship of the electrocardiographic strain pattern to left ventricular structure and function in hypertensive patients: The LIFE study: Losartan Intervention For Endpoint. *J Am Coll Cardiol* 2001; **38**: 514 - 520
- 22) Manning MJ, Pennel DJ: Cardiovascular Magnetic



- Resonance. Churchill Livingstone, Philadelphia, 2002; pp 75 - 96
- 23) Wachell K, Bella JN, Liebson PR, Gerds E, Dahlöf B, Aalto T, Roman MJ, Papademetriou V, Ibsen H, Rokkedal J, Devereux RB : Impact of different partition values on prevalences of left ventricular hypertrophy and concentric geometry in a large hypertensive population : The LIFE study. *Hypertension* 2000; **35**: 6 - 12
- 24) Brand JM, Altman DG : Statistical methods for assessing agreement between two methods of clinical measurement. *Lancet* 1986; : 307 - 310
- 25) Kronik G, Slany J, Mossbacher H : Comparative value of eight M-mode echocardiographic formulas for determining left ventricular stroke volume : A correlative study with thermodilution and left ventricular single-plane cineangiography. *Circulation* 1979; **60**: 1308 - 1316

