

Experimental Study of Quantitative Assessment of Left Ventricular Mass With Contrast Enhanced Real-Time Three-Dimensional Echocardiography

Lei ZHUANG,
MD

Xin-Fang WANG, MD
Ming-Xing XIE, MD
Li-Xin CHEN, MD
Hong-Wen FEI, MD
Ying YANG, MD
Jing WANG, MD
Run-Qing HUANG, MD
Ou-Di CHEN, MD

Abstract

Objectives. To evaluate the feasibility and accuracy of measurement of left ventricular mass with intravenous contrast enhanced real-time three-dimensional (RT3D) echocardiography in the experimental setting.

Methods. RT3D echocardiography was performed in 13 open-chest mongrel dogs before and after intravenous infusion of a perfluorocarbon contrast agent. Left ventricular myocardium volume was measured according to the apical four-plane method provided by TomTec 4D cardio-View RT1.0 software, then the left ventricular mass was calculated as the myocardial volume multiplied by the relative density of myocardium. Correlative analysis and paired *t*-test were performed between left ventricular mass obtained from RT3D echocardiography and the anatomic measurements.

Results. Anatomic measurement of total left ventricular mass was 55.6 ± 9.3 g, whereas RT3D echocardiographic calculation of left ventricular mass before and after intravenous perfluorocarbon contrast agent was 57.5 ± 11.4 and 55.5 ± 9.3 g, respectively. A significant correlation was observed between the RT3D echocardiographic estimates of total left ventricular mass and the corresponding anatomic measurements ($r = 0.95$). A strong correlation was found between RT3D echocardiographic estimates of left ventricular mass with perfluorocarbon contrast and the anatomic results ($r = 0.99$). Analysis of intraobserver and interobserver variability showed strong indexes of agreement in the measurement of left ventricular mass with pre and post-contrast RT3D echocardiography.

Conclusions. Measurements of left ventricular mass derived from RT3D echocardiography with and without intravenous contrast showed a significant correlation with the anatomic results. Contrast enhanced RT3D echocardiography permitted better visualization of the endocardial border, which would provide a more accurate and reliable means of determining left ventricular myocardial mass in the experimental setting.

J Cardiol 2004 Jan; 43(1): 23 - 29

Key Words

■ Contrast echocardiography (three-dimensional) ■ Cardiac volume (left ventricular mass)
■ Experimental medicine

Department of Echocardiography, Union Hospital, Tongji Medical College, Huazhong University of Science and Technology, Wuhan, China

Address for correspondence: WANG X-F, MD, Department of Echocardiography, Union Hospital, Tongji Medical College, Huazhong University of Science and Technology, 1277 Jiefang Avenue, Wuhan, 430022, PR China

Manuscript received March 24, 2003; revised July 24 and September 24, 2003; accepted September 24, 2003

INTRODUCTION

Accurate measurement of left ventricular mass is important to assess left ventricular remodeling during the progress of cardiovascular disease¹). Up to now, two-dimensional (2D) echocardiography has been essential for assessment of left ventricular mass, but the usefulness of routine echocardiography is limited by many factors such as poor acoustic windows in 10 - 15% of patients, and endocardial dropout caused by body habitus and lung diseases, with the anterior wall and apex most frequently affected²). Dynamic three-dimensional (3D) echocardiography may provide more accurate and repeatable estimations of cardiac structure size and function than conventional 2D echocardiography imaging does³). However, off-line dynamic 3D echocardiography is not regarded as feasible in every clinical practice because these techniques are limited by lengthy data acquisition times, computer processing times, and extensive operator interaction that precludes the imaging of dynamic structures even with gating techniques. Recently, real-time three-dimensional (RT3D) echocardiography has been developed to acquire more stereotype anatomic information⁴). The advantage over 2D echocardiography is the effective and accurate way to assess left ventricular mass. This study assessed the accuracy of measurement of left ventricular mass with RT3D echocardiography before and after intravenous administration of the perfluorocarbon contrast agent in the experimental setting.

SUBJECTS AND METHODS

Animal preparation

Thirteen mongrel dogs were studied, weight 11 to 15 kg. All operative and animal management procedures were approved by the Animal Care and Use Committee of the National Heart Institute. The dogs underwent intravenous sedation with sodium pentobarbital (25 mg/kg) and subsequent endotracheal intubation and ventilation with a volume-cycled ventilator. A Swan-Ganz catheter was positioned in the pulmonary artery via the femoral vein, and another catheter was positioned in the right common femoral artery for monitoring systemic arterial pressure and blood gases. Arterial blood gases and pH were maintained within physiologic ranges. Then a lateral thoracotomy was performed and the heart was suspended in an epicardial cradle. A warm water bath was placed over the anterior

surface of the heart for ultrasound scanning.

Real-time three-dimensional echocardiography

RT3D echocardiography was performed with a Philips Sonos 7500 ultrasonographic machine (Philips Co.). This unit uses a 2 - 4 MHz matrix-array transducer for rapid beam forming to scan a pyramidal volume. Real-time volumetric scanning requires no off-line reconstruction techniques, enabling dynamic three-dimensional visualization and quantification of the heart in real time using a transthoracic approach. Images can be viewed in a "live 3D" or "full volume" mode. Usually we perform a two-dimensional study first and select the region of interest on the middle line, then press the "full volume" button, try to include all targets and then touch the "acquire" button. Triggered by electrocardiography, the four 0 - 15°, 15 - 30°, 30 - 45° and 45 - 60° adjacent 15 × 60° narrow-angle display stereo datasets are acquired in order in the first, third, fifth and seventh cardiac cycles. These images are combined to produce the 60 × 60° "pyramidal image". One full volume acquisition will take 5 - 8 sec. The pyramidal dataset obtained from the apical four-chamber view can contain the whole heart structure. During the procedure ventilation to the dog should be paused to avoid image distortion due to respiration and motion. Data post-process was performed by a workstation TomTec 4D cardio-View RT1.0 (TomTec, Inc.).

Preparation of perfluorocarbon contrast agent

Perfluorocarbon-exposed sonicated dextrose-albumin was manufactured according to the approach described previously⁵). One part 5% human serum albumin and three parts 5% dextrose were drawn into a 10 ml syringe. The 10 ml syringe was attached to a three-way stopcock that was also attached to a syringe containing 2 ml of perfluorocarbon gas. Then the dextrose-albumin solutions were sterile sonicated (Sonicator, Heat Systems Inc.) at a frequency of 20 kHz lasting for 60 sec. During sonication, the 2 ml of perfluorocarbon in syringe was slowly introduced into the dextrose-albumin by means of the stopcock. After sonication, the microbubble solution was placed in a vertical position in a 10 ml syringe until a distinct upper white layer and a lower clear layer formed. The lower clear layer was decanted, and the upper white layer was used for intravenous injections. The concentra-

tion of microbubbles measured by Coulter counter was $1.8 \times 10^9/\text{ml}$, the mean size of microbubbles was $3.4 \pm 1.3 \mu\text{m}$, and the volume of one bolus injection was 3 - 4 ml. RT3D echocardiography examination was performed before and after intravenous infusion of perfluorocarbon contrast agent.

Measurements of left ventricular mass with real-time three-dimensional echocardiography

The pyramidal dataset derived from the "full volume" mode permits simultaneous, multiple plane display of two sector arcs (B-scans) and C scan by a TomTec workstation with 4D cardio-View RT 1.0 software. Calculation of the left ventricular mass from the RT3D echocardiographic images was performed by an interactive-aided manual tracing technique to outline left ventricular myocardium volume between the epicardial and endocardial borders according to the four-plane method (Fig. 1). Left ventricular mass was calculated as the myocardial volume multiplied by the relative density of myocardium (1.05). Usually image acquisition under "full volume" mode took less than 5 min and the procedure to calculate left ventricular mass with 4D cardio-View RT 1.0 software needed no more than 10 min, so the whole process takes 15 min. RT3D echocardiographic images (10 dogs) pre and post contrast enhancement were analyzed by two independent observers unaware of the anatomic measurements. In addition, all left ventricular mass measurements were repeated at least 1 week apart by the same observer to allow subsequent assessment of intraobserver variability.

Measurements of anatomic left ventricular mass

After the RT3D echocardiographic examination was completed, the dogs were euthanized with an overdose of pentobarbital and potassium chloride and the heart was excised. Then the left ventricle was isolated and cut off and weighed.

Statistical methods

All data are expressed as mean \pm SD. To determine whether the difference in the values between RT3D echocardiographic imaging and anatomic measurements was statistically significant, a paired *t*-test was performed; the level of significance was set to $p < 0.05$. Linear regression analysis was used to determine the correlation between left ventricular mass from excised heart and the results derived

from RT3D echocardiographic images before and after injection of ultrasonic contrast medium. Bland and Altman analysis was used to assess agreement between two measurements.

RESULTS

Immediately after intravenous injection, perfluorocarbon contrast microbubbles were observed in the left ventricular cavity, and the visualization of the left ventricular endocardial border was perfect (Fig. 2). Anatomic measurements of total left ventricular mass ranged from 38.9 to 71.1 g (mean \pm SD: 55.6 ± 9.3 g), whereas the RT3D echocardiographic calculation of left ventricular mass ranged from 39.3 to 82.3 g (mean \pm SD: 57.5 ± 11.4 g; $p = 0.10$ vs anatomic measurements). RT3D echocardiographic calculation of the left ventricular mass after intravenous perfluorocarbon contrast agent ranged from 37.7 to 70.5 g (mean \pm SD: 55.5 ± 9.3 g; $p = 0.57$ vs anatomic measurements). There was a significant correlation between the RT3D echocardiographic estimates of total left ventricular mass and the corresponding anatomic measurements ($r = 0.95$, mean difference 1.9 ± 3.8 g; Fig. 3). A strong correlation was found between the RT3D echocardiographic calculation of left ventricular mass with perfluorocarbon contrast and the anatomic measurements ($r = 0.99$, mean difference 0.1 ± 0.9 g; Fig. 4).

There was a high index of interobserver ($r = 0.88$, mean difference 1.6 ± 3.7 g) as well as intraobserver ($r = 0.92$, mean difference 1.4 ± 3.2 g) agreement for the RT3D echocardiographic measurements of left ventricular mass. There was a higher index of interobserver ($r = 0.96$, mean difference -0.5 ± 1.9 g) as well as intraobserver ($r = 0.98$, mean difference 0.4 ± 1.5 g) agreement for the contrast enhanced RT3D echocardiographic measurements of left ventricular mass.

DISCUSSION

Left ventricular remodeling determined by echocardiography is recognized as one of the most powerful predictors of morbidity and mortality in patients with severe cardiovascular diseases. Up to now conventional 2D echocardiography has remained the main method for calculation of left ventricular mass, but 2D echocardiography provides only tomographic images of the object. In order to appreciate the three-dimensional structural relationships, mental reconstruction of these views

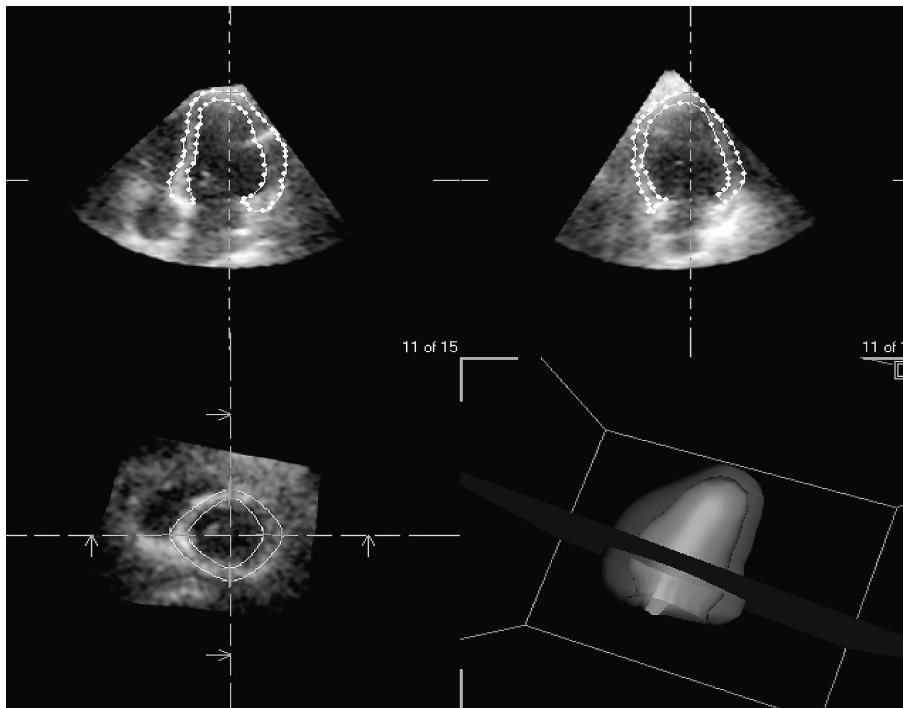


Fig. 1 Measurement of left ventricular myocardium volume from real-time three-dimensional echocardiographic images

Myocardium volume was manually outlined along the endocardial and epicardial border on two long-axis and one short-axis views extracted from the pyramidal dataset according to the apical four-plane method provided by TomTec 4D cardio-View RT 1.0 software package.

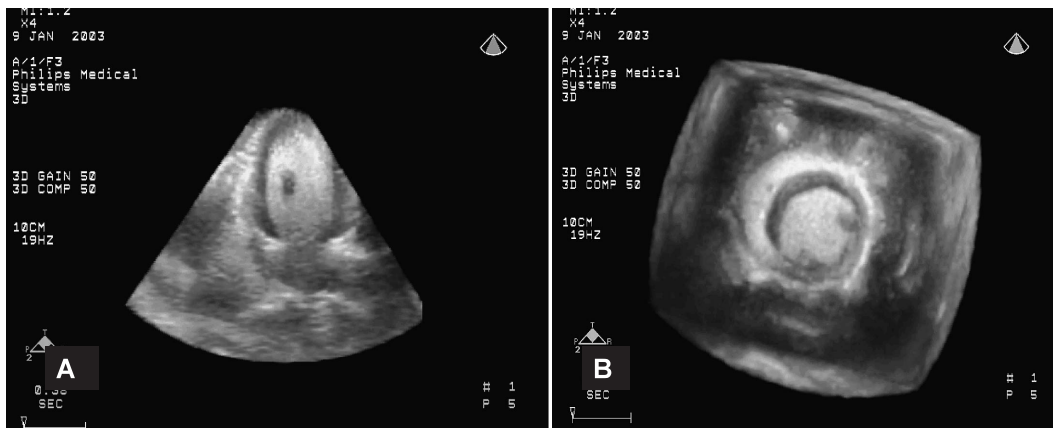

Fig. 2 Measurement of left ventricular myocardium volume by real-time three-dimensional echocardiography

After intravenous infusion of perfluorocarbon contrast, the endocardial border was visualized clearly.

A: Real-time three-dimensional echocardiographic data in the apical four-chamber view.

B: Short-axis view of ventricles.

is required by an experienced observer which limits the ability to analyze structures of unknown or complex shapes. Various computer based three-dimensional reconstruction techniques have been developed to replace the subjective mental

reassembly of complex cardiac geometry⁶). Dynamic 3D echocardiography could produce more accurate and repeatable left ventricular volume estimations without the geometric assumptions required by conventional two-dimensional

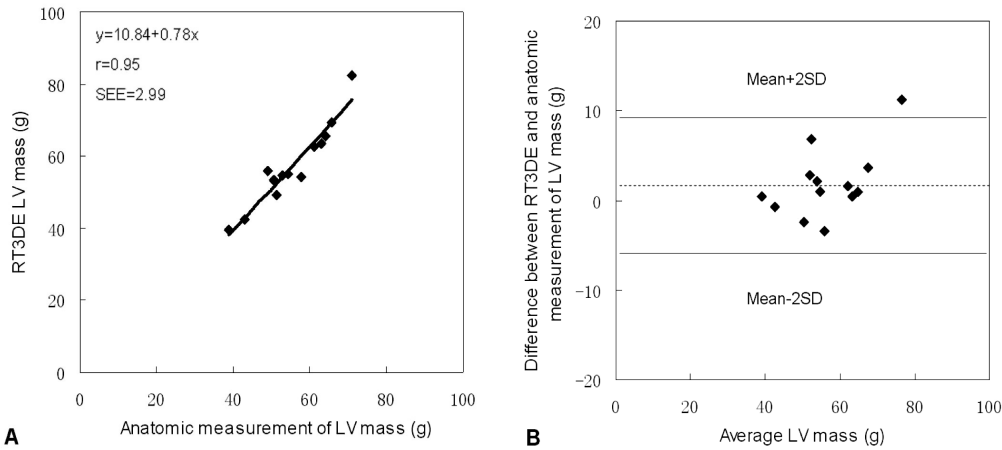


Fig. 3 Relationships between real-time three-dimensional echocardiographic and anatomic measurements of left ventricular mass measured in 13 dogs

Correlation between measurements obtained by the two methods (A). Bland and Altman plot of the difference between real-time three-dimensional echocardiographic and anatomic measurements of left ventricular mass (B). The dashed and solid lines indicate the mean \pm 2SD.

RT3DE = real-time three-dimensional echocardiography; LV = left ventricular.

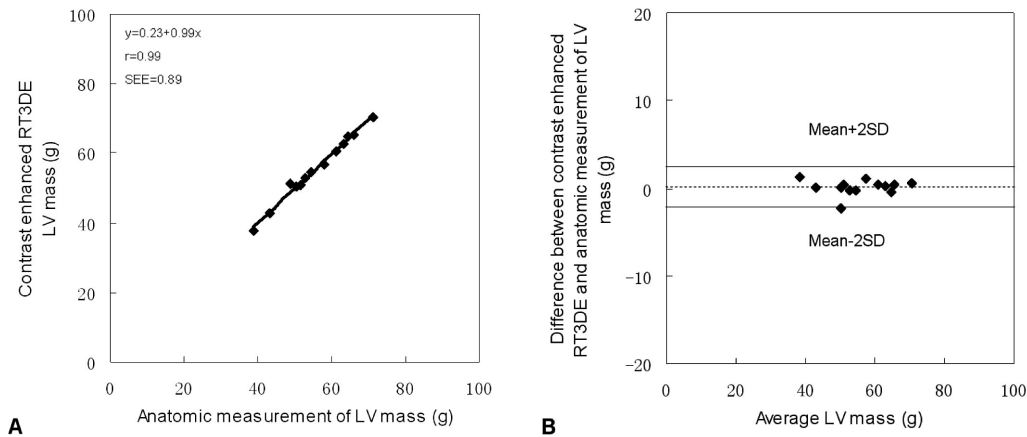


Fig. 4 Relationships between contrast enhanced real-time three-dimensional echocardiographic and anatomic measurements of left ventricular mass measured in 13 dogs

Correlation between measurements obtained with the two methods (A). Bland and Altman plot of the difference between contrast enhanced real-time three-dimensional echocardiographic and anatomic measurements of left ventricular mass (B). The dashed and solid lines indicate the mean \pm 2SD.

Abbreviations as in Fig. 3.

imaging⁷⁾, but the early reconstruction of three-dimensional imaging requires a method for registering the spatial location of multiple two-dimensional images and combination in three dimensions with electrocardiography and respiratory gating during the different cardiac cycles⁸⁾, so clinical application is greatly hampered by the complicated procedure, slow frame rate and artifacts due to respiratory and cardiac motion.

The matrix array transducer used in real-time

three-dimensional imaging was proposed by Duke University in the United States and made available commercially by Philips Corporation recently⁹⁾. The transducer crystal is equally divided into minute square elements by many longitudinal and horizontal lines. The elements are arrayed in a matrix of $60 \times 60 = 3,600$ elements (or $80 \times 80 = 6,400$). By delaying the firing time to each element controlled by computer, the ultrasonic wave beams have different phases, and the direction of the wave

front can be altered. The Philips Sonos 7500 ultrasonographic machine uses a dedicated three-dimensional echo probe for rapid beam forming to scan a pyramidal volume. Real-time volumetric scanning requires no off-line reconstruction techniques, enabling live three-dimensional visualization and quantification of the heart. RT3D echocardiography was used to measure phantoms of different size and shape, and demonstrated the validation of this system to assess left ventricular volume¹⁰). RT3D echocardiography and 2D echocardiography of seven aneurysmal balloons, 15 sheep (5 with chronic left ventricular aneurysms and 10 without left ventricular aneurysms) during 60 different hemodynamic conditions and 29 patients (13 with chronic left ventricular aneurysms and 16 with normal left ventricle) and demonstrated that RT3D echocardiography could accurately quantify left ventricular volumes for geometrically asymmetric left ventricles associated with ventricular aneurysms¹¹).

One of the main limitations of RT3D echocardiography is the diminished image resolution compared to state-of-the-art 2D echocardiography. On the other hand, irregular respiration rate, arrhythmia and body motion may affect the combination of "full volume" imaging during several cardiac cycles leading to artifacts. Contrast agents may facilitate endocardial definition and increase the accuracy of volume measurements obtained from three-dimensional images¹²).

Recently, numerous advances have been made in contrast echocardiography, particularly in the formulation of agents that cross the pulmonary circulation to opacify the left cardiac chambers and myocardium. The new type of ultrasound contrast agent is usually composed of albumin or phospholipid shell containing perfluorocarbon or hexafluoride gas, with an average bubble diameter of 4 to 6 μm ¹³). These microbubbles behave as intravenous tracers with rheological properties similar to red blood cells and can resonate in an ultrasound field and give particularly bright signals at frequencies at

or above their natural frequencies¹⁴). Contrast enhancement in a group of patients with poor images resulted in a significantly higher segmental salvage rate compared to harmonic image alone¹⁵). Measurement of left ventricular volumes and ejection fraction before and after intravenous contrast echocardiography and comparison of these measurements obtained by magnetic resonance imaging showed the use of contrast improved the accuracy of echocardiographic assessment of left ventricular volumes and ejection fraction¹⁶). Evidence suggests that harmonic contrast echocardiography gives the best signal to noise ratio for left ventricular opacification.

The present study found that left ventricular mass derived from RT3D echocardiography correlated well with the anatomic measurements and improved after injection of intravenous contrast agent. Contrast enhanced RT3D echocardiography also seemed to have a higher index of intraobserver and interobserver agreement. RT3D echocardiography with perfluorocarbon microbubbles contrast medium provides better visualization of the endocardial border and a more accurate and repeatable measurement of total left ventricular mass, especially if the technician has less experience of imaging analysis or in patients with poor acoustic windows.

CONCLUSIONS

This study describes a novel methodology for the quantitative assessment of left ventricular mass using RT3D echocardiographic images. Left ventricular mass measurement derived from RT3D echocardiography with and without contrast medium injection were correlated well with anatomic measurements in an animal study, but contrast enhanced RT3D echocardiography permitted immediate excellent visualization of endocardial border in any plane, which would provide a more accurate and reliable means of determining left ventricular mass.

References

- 1) Levy D, Garrison RJ, Savage DD, Kannel WB, Castelli WP: Prognostic implications of echocardiographically determined left ventricular mass in the Framingham Heart Study. *N Engl J Med* 1990; **322**: 1561 - 1566
- 2) Waytt HL, Heerbaum S, Heng MK, Gueret P, Corday E: Cross-sectional echocardiography: . Analysis of mathematic models for quantifying volume of symmetric and asymmetric left ventricles. *Am Heart J* 1980; **100**: 821 - 828
- 3) Pini R, Giannazzo G, Di Bari M, Innocenti F, Rega L, Casolo G, Devereux RB: Transthoracic three-dimensional echocardiographic reconstruction of left and right ventricles: In vitro validation and comparison with magnetic resonance imaging. *Am Heart J* 1997; **133**: 221 - 229
- 4) von Ramm OT, Smith SW: Real time volumetric ultrasound imaging system. *J Digit Imaging* 1990; **3**: 261 - 266
- 5) Porter TR, Xie F, Kricsfeld A, Kilzer K: Noninvasive identification of acute myocardial ischemia and reperfusion with contrast ultrasound using intravenous perfluoropropane-exposed sonicated dextrose albumin. *J Am Coll Cardiol* 1995; **26**: 33 - 40
- 6) Wang XF: New trend in new century and new year: Prospect of ultrasound in medicine. *Chin J Ultrason* 2001; **10**: 5 - 7 (in Chinese)
- 7) Belohlavek M, Foster SM, Kinnick RR, Greenleaf JF, Seward JB: Reference techniques for left ventricular volume measurement by three-dimensional echocardiography: Determination of precision, accuracy, and feasibility. *Echocardiography* 1997; **14**: 329 - 336
- 8) Mori Y, Shiota T, Jones M, Wanitkun S, Irvine T, Li X, Delabays A, Pandian NG, Sahn DJ: Three-dimensional reconstruction of the color Doppler-imaged vena contracta for quantifying aortic regurgitation: Studies in a chronic animal model. *Circulation* 1999; **99**: 1611 - 1617
- 9) Ota T, Kisslo J, von Ramm OT, Yoshikawa J: Real-time, volumetric echocardiography: Usefulness of volumetric scanning for the assessment of cardiac volume and function. *J Cardiol* 2001; **37** (Suppl): 93 - 101
- 10) Fei HW, Wang XF, Xie MX, Zhuang L, Wang J, Huang RQ, Yang Y: Validation of real-time three-dimensional echocardiography for quantifying left ventricular volume in experimental study. *Chin J Ultrason* 2003; **19**: 532 - 534 (in Chinese)
- 11) Qin JX, Jones M, Shiota T, Greenberg NL, Tsujino H, Firstenberg MS, Gupta PC, Zetts AD, Xu Y, Ping Sun J, Cardon LA, Odabashian JA, Flamm SD, White RD, Panza JA, Thomas JD: Validation of real-time three-dimensional echocardiography for quantifying left ventricular volumes in the presence of a left ventricular aneurysm: In vitro and in vivo studies. *J Am Coll Cardiol* 2000; **36**: 900 - 907
- 12) Ota T, Fleishman CE, Strub M, Stetten G, Ohazama CJ, von Ramm OT, Kisslo J: Real-time, three-dimensional echocardiography: Feasibility of dynamic right ventricular volume measurement with saline contrast. *Am Heart J* 1999; **137**: 958 - 966
- 13) de Jong N, Ten Cate FJ, Lancee CT, Roelandt JR, Bom N: Principles and recent developments in ultrasound contrast agents. *Ultrasonics* 1991; **29**: 324 - 330
- 14) Ismail S, Jayaweera AR, Camarano G, Gimple LW, Powers ER, Kaul S: Relation between air-filled albumin microbubble and red blood cell rheology in the human myocardium: Influence of echocardiographic systems and chest wall attenuation. *Circulation* 1996; **94**: 445 - 451
- 15) Spencer KT, Grayburn PA, Mor-Avi V, Bednarz J, Grimm RA, Furlong K, Farnum RF, Floer SD, Widner PJ, Lang RM: Myocardial contrast echocardiography with power Doppler imaging. *Am J Cardiol* 2000; **86**: 479 - 481
- 16) Hundley WG, Kizilbash AM, Afridi I, Franco F, Peshock RM, Grayburn: Administration of an intravenous contrast agent improves echocardiographic determination of left ventricular volumes and ejection fraction: A comparison with cine magnetic resonance imaging. *J Am Coll Cardiol* 1998; **32**: 1426 - 1432