

Highly Concentrated Vascular Endothelial Growth Factor in Crow-Fukase Syndrome With High Output Heart Failure : A Case Report

Teruo SHIRAKI, MD

Shinji SATOH, MD

Hiroki SUGIYAMA, MD

Makoto KOBAYASHI, MD

Toshiyuki TAKAMURA, MD

Akio KAJIYAMA, MD

Abstract

Crow-Fukase syndrome is a disease of plasma cell dyscrasia. Congestive heart failure is the biggest complication affecting the prognosis. A 57-year-old male was admitted with edema and low grade fever. Globe and stocking type polyneuropathy, increased levels of adrenocorticotrophic hormone and thyroid-stimulating hormone, serum M-protein component of the immunoglobulin A- type, skin polypoid lesion, and organomegaly including cardiomegaly were observed. The diagnosis was Crow-Fukase syndrome based on these clinical features. High output heart failure and pulmonary hypertension were determined with a cardiac catheter. Diuretics and angiotensin converting enzyme inhibitor were effective to control his overhydration. The level of serum vascular endothelial growth factor was markedly increased and might be responsible for the manifestation of this syndrome with cardiac involvement.

J Cardiol 2005 Feb; 45(2): 75 - 80

Key Words

■Heart failure (high cardiac output)

■Hypertension, pulmonary

■Complications

■Endothelium (vascular endothelial growth factor)

INTRODUCTION

Crow-Fukase syndrome is a disease of plasma cell dyscrasia which is associated with polyneuropathy, endocrinopathy, M-protein, skin lesions and organomegaly¹). Congestive heart failure is the most important factor affecting the prognosis²). Although the etiology of Crow-Fukase syndrome is not known, recent reports have suggested that serum vascular endothelial growth factor (VEGF) plays an important role³⁻⁶). We report a case of Crow-Fukase syndrome with high output heart failure and pulmonary hypertension associated with

serum VEGF elevation.

CASE REPORT

A 57-year-old male was admitted to our hospital for further examination of cardiomegaly on February 26, 1996. He had suffered foot edema, numbness of lower extremities and low grade fever for 6 months before admission. The following physical factors were recorded at the time of admission: height, 160 cm; body weight, 62.4kg; body temperature, 37.2 °C; blood pressure, 160/74mmHg; and pulse rate, regular at 92 beats/min. Physical examination revealed diffuse skin pigmentation

独立行政法人国立病院機構岩国医療センター 内科: 〒740-8510 山口県岩国市黒磯町2-5-1

Department of Internal Medicine, National Hospital Organization, Iwakuni Medical Center, Yamaguchi

Address for correspondence: SHIRAKI T, MD, Department of Internal Medicine, National Hospital Organization, Iwakuni Medical Center, Kuroiso-cho 2-5-1, Iwakuni, Yamaguchi 740-8510

Manuscript received May 10, 2004; revised August 3, 2004; accepted August 4, 2004

with polypoid skin tumor and pitting edema of the lower extremities. Clubbing was not detected. The jugular vein was dilated. A systolic murmur was audible at the third intercostal space near the left sternal border (Levine /). No lung rales were detected. The abdomen was distended and hepatosplenomegaly was detected. Neurological examination revealed diminished bilateral patella and Achilles tendon reflex. Complete blood cell count showed normocytic normochromic anemia (erythrocyte count = $332 \times 10^4/\mu\text{l}$, hemoglobin value = 10.1 g/dl, hematocrit value = 30.5%) with normal white cell and platelet count. Blood chemistry revealed mild hypocholesterolemia (total cholesterol = 121 mg/dl), slightly decreased cholinesterase (125 IU/l) and mild elevation of blood urea nitrogen (25.1 mg/dl). C-reactive protein level was 1.0 mg/dl. Serum immunoglobulin A level was elevated (735 mg/dl) and serum immunoelectrophoresis revealed an M-protein component of the immunoglobulin A- type without urine Bence Jones protein. Adrenocorticotrophic hormone was elevated (82 pg/ml) with normal cortisol level and free T_3 level was slightly decreased (1.75 pg/dl) with mild thyroid-stimulating hormone elevation (4.0 $\mu\text{IU/ml}$). Serum thiamine level was slightly low (17 ng/ml) and mild elevation of serum interleukin-6 was observed (4.3 pg/ml). Renin activity, aldosterone and catecholamines (adrenaline, noradrenaline and dopamine) in the plasma were all normal.

Chest radiography revealed cardiomegaly (cardiothoracic ratio = 56%) with mild pulmonary congestion (Fig. 1). Electrocardiography showed R wave retraction in leads $V_3 - V_4$, biphasic T wave in leads $V_2 - V_5$ and ST segment depression in leads V_1 and $V_5 - V_6$ (Fig. 2). Abdominal computed tomography showed hepatosplenomegaly with mild ascites. The conduction velocities of the median nerve and tibian nerve were decreased. Bone scintigraphy showed no osteolytic or osteoclastic lesion. Bone marrow puncture showed mild plasmacytosis without plasmacytoma. Lumbar puncture was not performed. Echocardiography showed left ventricular hypertrophy and dilation with normal contractility (interventricular septal thickness, left ventricular posterior wall thickness, left ventricular end-diastolic diameter, left ventricular end-systolic diameter and ejection fraction were 14, 12, 65, 40 mm and 68% respectively). The left atrium and aortic root were slightly dilated and mild pericar-

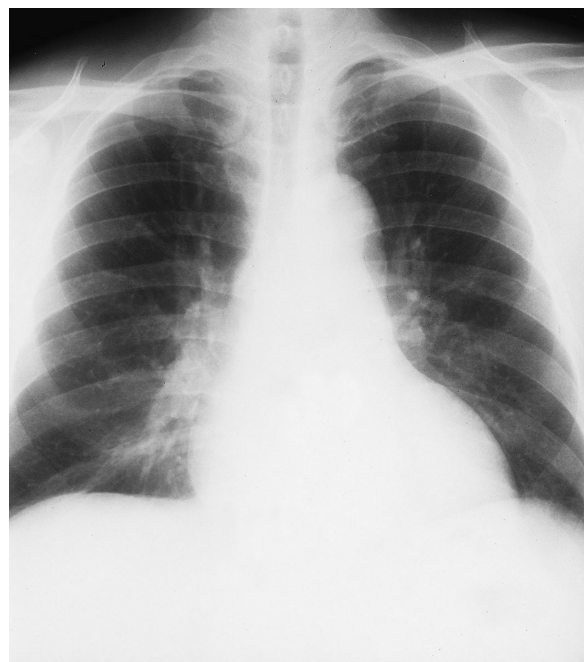

Fig. 1 Chest radiograph on admission

dial effusion was detected (left atrial diameter and aortic diameter were 38 and 40 mm; Fig. 3). Doppler echocardiography showed mild aortic valve stenosis (pressure gradient = 20 mmHg) and moderate tricuspid regurgitation (estimated right ventricular pressure = 52 mmHg). Based on these signs and laboratory data, the diagnosis was Crow-Fukase syndrome.

Diuretic administration (furosemide, 40 mg/day) was started for the treatment of edema and ascites. Stress thallium myocardial scintigraphy showed no perfusion defect. Right heart catheterization performed on 26th day under no medication revealed pulmonary hypertension and high cardiac output with low systemic and pulmonary vascular resistance (Table 1). Oxygen saturation evaluated at the cardiac catheterization did not show any significant shunt between the right and left heart (Table 2). Selective coronary angiography was normal and left ventriculography showed left ventricular dilation with normal contractility. Histological examination of the biopsy specimen obtained from the left ventricle showed mild myocardial hypertrophy with disarray. The diagnosis was high output heart failure with pulmonary hypertension.

In addition to the treatment with diuretics for overhydration, hypertension with left ventricular hypertrophy was treated with calcium antagonist

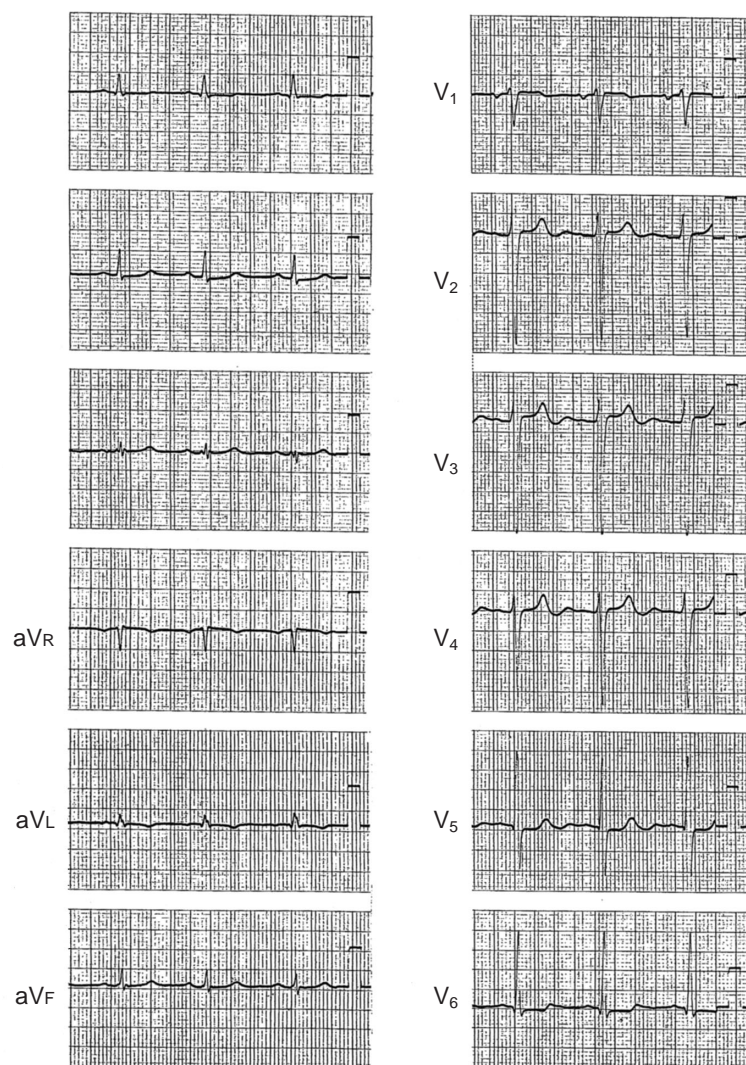


Fig. 2 Electrocardiogram on admission

(amlodipine, 5 mg/day) and angiotensin converting enzyme inhibitor (derapril, 30 mg/day). In the absence of severe neurological deficit, no steroid hormone was used. He was discharged after the improvement of pulmonary congestion, ascites and pitting edema. Blood urea nitrogen, creatinine and serum potassium ion levels increased, furosemide level was decreased (40–20 mg/day) and derapril medication was stopped.

His clinical signs and laboratory data have not changed for 7 years during follow up in the outpatient clinic. Organomegaly has persisted as determined by abdominal computed tomography and echocardiography. However, serial echocardiography showed diminished left ventricular volume and right ventricular systolic pressure (left ventricular

end-diastolic diameter, end-systolic diameter and estimated right ventricular systolic pressures were 58 mm, 38 mm and 45 mmHg on May 19, 1999; 52 mm, 35 mm and 26 mmHg on June 11, 2003). Marked elevation of vascular endothelial growth factor (1,280 pg/ml) and slight elevation of hepatocyte growth factor (0.42 pg/ml) were observed during follow up at the outpatient clinic on June 11, 2003. He was readmitted to our hospital for the increase of ascites despite treatment with diuretics on January 16, 2004. Osteosclerotic lesion was found in his left iliac bone for the first time. He was referred to the division of hematology of another hospital for treatment with melphalan and prednisolone.

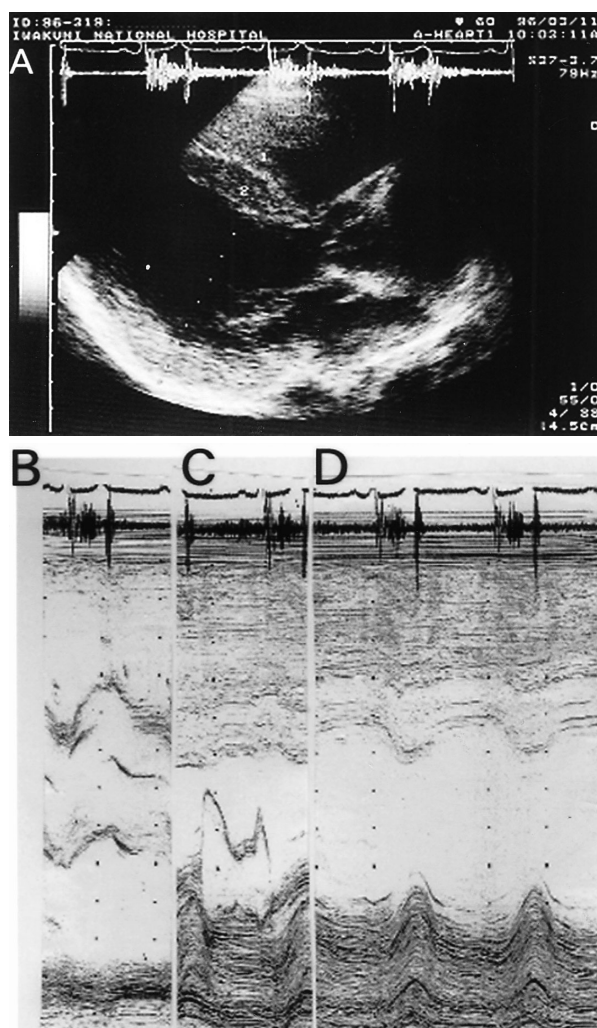


Fig. 3 Echocardiograms on admission

- A: Parasternal long-axis B-mode view in enddiastole.
 B: M-mode view of the right ventricle, aorta and left atrium.
 C: M-mode view of the mitral valve.
 D: M-mode view of the left ventricle at the level of the chordae tendineae.

DISCUSSION

We did not follow the recommended strategy using alkylators with or without steroid hormone in the present patient because: clubbing, a sign associated with shorter survival, was not detected and extra vascular volume overload was controllable with diuretics⁷⁾; neurological deficit was mild and gait disturbance was not detected; the prognosis was reported to be better in a recent review⁷⁾ than in former cases²⁾ (median survival 165 months vs 33 months); and VEGF, a useful marker associated with the effect of treatment³⁻⁶⁾, could not be mea-

Table 1 Hemodynamic findings

Pulmonary capillary wedge pressure	14 mmHg
Pulmonary artery pressure	43/17 mmHg
Right ventricular pressure(EDP)	42/5(7)mmHg
Right atrial pressure	5 mmHg
Left ventricular pressure(EDP)	182/0(13)mmHg
Aortic pressure	160/74 mmHg
Cardiac output	11.2 l/min
Cardiac index	6.63 l/min/m ²
Stroke volume	183.0 ml/beat
Stroke index	108.3 ml/beat/m ²
Total vascular resistance	727.8 dyn·sec·cm ⁻⁵
Total pulmonary resistance	192.5 dyn·sec·cm ⁻⁵
Heart rate	62 beats/min
Body surface area	1.69 m ²

EDP = end-diastolic pressure.

Table 2 Oxygen saturation at cardiac catheterization

Site	Saturation(%)
Superior vena cava	88.0
Inferior vena cava	88.6
Right atrium	80.0
Right ventricle	85.5
Proximal pulmonary artery	85.0
Distal pulmonary artery	84.4
Left ventricle	98.2
Aorta	98.2

Samples were obtained from the patient breathing room air.

sured at the first admission without a commercially available kit. The use of vasodilating agents for the lowering of the blood pressure may have increased cardiac output. However, loop diuretics may have canceled the adverse effect of the vasodilating agents and controlled the signs of overhydration without additional use of thiazide or spironolactone. However, we planned chemotherapy for the osteosclerotic lesion and refractory ascites despite reduced cardiac output and improved cardiomegaly with diuretic treatment after 7 years follow-up.

The cause of one third of deaths in patients with this syndrome is congestive heart failure²⁾. On the other hand, the elevation of serum VEGF probably causes the symptoms of this syndrome³⁻⁶⁾. Only a few reports have evaluated the relationship between VEGF and hemodynamic disorder of this syndrome. A case with serum VEGF elevation and

high output heart failure showed decrease in both pulmonary and systemic vascular resistance⁶). The removal of plasmacytoma decreased the serum VEGF level and improved clinical symptoms. Therefore, elevated serum VEGF can explain many of the clinical features containing cardiac manifestations in this syndrome. Although the hemodynamic disorder in our case was similar to theirs, we could not measure VEGF at the first admission. The time interval from the first admission till the measurement of VEGF was long. Therefore, elevated serum VEGF could not be proved as the cause of the high output heart failure in our case. However, low grade fever under 38 °C, mild anemia and slightly decreased serum thiamine level could not explain the marked increase in cardiac output and decrease in vascular resistance. Furthermore, we used neither steroid hormone nor alkylating agents that influence serum VEGF level. Therefore, the serum VEGF level may have been high from the beginning of heart failure and caused the clinical features in our case.

Steroid treatment improved the pulmonary hypertension and high VEGF level in another case⁸). The pulmonary hypertension may have been caused by the increase in vascular resistance. Presumably a vicious cycle was established in which interstitial/perivascular edema due to hyperpermeability caused by VEGF reduced gas diffusion and up-regulated the expression of VEGF. However, hypoxia was not documented and pulmonary vascular resistance fell in our case. VEGF stimulates vasodilation and endothelial nitric oxide production except for vascular hyperpermeability and angiogenesis⁹). Therefore, the main cause of pulmonary hypertension may be the high output

secondary to vasodilation with VEGF elevation rather than the increase in vascular resistance.

In contrast, a young female presented with ischemic cardiomyopathy with severe coronary stenoses and reduced ejection fraction⁵). An abnormal immune reaction containing VEGF elevation may have caused coronary arteritis. Although the treatment improved the ejection fraction as VEGF decreased, the hemodynamic data containing cardiac output and vascular resistance were not reported. There was no coronary artery stenosis and ejection fraction was normal in our case.

Other types of cardiac manifestations with this syndrome have also been reported: A case of left ventricular hypertrophy similar to hypertrophic cardiomyopathy with normal coronary artery¹⁰ (cardiac output was unknown), a case of moderate left ventricular hypertrophy and pulmonary hypertension¹¹ with marked elevation of both pulmonary and systemic vascular resistance, a case with normal systemic vascular resistance and markedly elevated pulmonary vascular resistance¹², and a case resembling dilated cardiomyopathy with normal coronary artery¹³ (cardiac output and vascular resistance were unknown).

These cardiac manifestations were different to those of our case. Therefore, cardiac involvement of this syndrome can vary widely. It is not clear whether only VEGF can explain all these various patterns of cardiac complications systematically because serum VEGF was not measured in those four cases. Further examination is required to determine the uniform mechanism including any other bioactive products in addition to VEGF which may be important in the wide spectrum of cardiac involvement of this syndrome.

要 約

血管内皮増殖因子の上昇を伴い高心拍出量性心不全を呈した

Crow-Fukase 症候群の 1 例

白木 照夫 佐藤 慎二 杉山 洋樹 小林 誠
高村 俊行 梶山 晃雄 斎藤 大治

Crow-Fukase 症候群は、形質細胞の傷害に基づく疾患で、うっ血性心不全はその生命予後を左右する最大の合併症である。57歳の男性が、浮腫と発熱を主訴に当院へ入院した。神経所見では手袋と靴下型の末梢神経障害が認められ、血液検査で副腎皮質刺激ホルモン、甲状腺刺激ホルモンおよび免疫グロブリン A 型の M 成分が上昇していた。全身の皮膚にはポリープ様病変がみられ、心臓を含む内臓の腫大があった。これらの臨床所見から、本症例は Crow-Fukase 症候群と診断された。

心臓カテーテル検査では，高心拍出性心不全と肺高血圧が認められた．利尿薬が水分過剰状態の改善に有効で，Ca拮抗薬とアンジオテンシン変換酵素阻害薬の併用が体血圧の低下に有効であった．血清中の血管内皮増殖因子は著明に上昇しており，本症候群の心症状への関与が疑われた．

J Cardiol 2005 Feb; 45(2): 75 - 80

References

- 1) Bardwick PA, Zvaifler NJ, Gill GN, Newman D, Greenway GD, Resnick DL: Plasma cell dyscrasia with polyneuropathy, organomegaly, endocrinopathy, M-protein, skin changes: The POEMS syndrome: Report on two cases and a review of the literature. *Medicine* 1980; **59**: 311 - 322
- 2) Nakanishi T, Sobue I, Toyokura Y, Nishitani H, Kuroiwa Y, Satoyoshi E, Tsubaki T, Igata A, Ozaki Y: The Crow-Fukase syndrome: A study of 102 cases in Japan. *Neurology* 1984; **34**: 712 - 720
- 3) Hashiguchi T, Arimura K, Matsumuro K, Otsuka R, Watanabe O, Jonosono M, Maruyama Y, Maruyama I, Osame M: Highly concentrated vascular endothelial growth factor in platelets in Crow-Fukase syndrome. *Muscle Nerve* 2000; **23**: 1051 - 1056
- 4) Soubrier M, Dubost JJ, Serre AF, Ristori JM, Sauvezie B, Cathebras P, Piette JC, Chapman A, Authier FJ, Gherardi RK: Growth factors in POEMS syndrome: Evidence for a marked increase in circulating vascular endothelial growth factor. *Arthritis Rheum* 1997; **40**: 786 - 787
- 5) Ichikawa Y, Nakata T, Ohhata J, Wakabayashi T, Sasao H, Tsuchihashi K, Shimamoto K, Chiba S, Matsumoto H: Crow-Fukase syndrome with ischemic cardiomyopathy. *Intern Med* 2001; **40**: 726 - 730
- 6) Araki T, Konno R, Soma R, Nakashima A, Takimoto H, Tofuku Y, Shimizu M: Crow-Fukase syndrome associated with high-output heart failure. *Intern Med* 2002; **41**: 638 - 641
- 7) Dispenzieri A, Kyle RA, Lacy MQ, Rajkumar V, Therneau TM, Larson DR, Greipp PR, Witzig TE, Basu R, Suarez GA, Fonseca R, Lust JA, Gertz MA: POEMS syndrome: Definitions and long-term outcome. *Blood* 2003; **101**: 2496 - 2506
- 8) Niimi H, Arimura K, Jonosono M, Hashiguchi T, Kawabata M, Osabe M, Kitajima I: VEGF is causative for pulmonary hypertension in a patient with Crow-Fukase (POEMS) syndrome. *Intern Med* 2000; **39**: 1101 - 1104
- 9) Hood JD, Meininger CJ, Ziche M, Granger HJ: VEGF upregulates eNOS message, protein, and NO production in human endothelial cells. *Am J Physiol* 1998; **274**: H1054 - H1058
- 10) Shimizu N, Goya M, Akimoto H, Koike A, Nogami A, Ito H, Marumo F, Hiroe M: Cardiomyopathy in a case of Crow-Fukase syndrome. *Jpn Heart J* 1997; **38**: 877 - 880
- 11) Iwasaki H, Ogawa K, Yoshida H, Takashima F, Shimizu K, Lee JD, Ueda T, Nakamura T: Crow-Fukase syndrome associated with pulmonary hypertension. *Intern Med* 1993; **32**: 556 - 560
- 12) Feinberg L, Temple D, de Marchena E, Patarca R, Mitrani A: Soluble immune mediators in POEMS syndrome with pulmonary hypertension: Case report and review of literature. *Crit Rev Oncog* 1999; **10**: 293 - 302
- 13) Tanus T, Miller HJ: POEMS syndrome presenting with cardiomegaly and cardiomyopathy. *J Intern Med* 1992; **231**: 445 - 448