

Combined Treatment With Statin and Angiotensin-Receptor Blocker After Stenting as a Useful Strategy for Prevention of Coronary Restenosis

Hiroaki NISHIKAWA, MD
Shin-ichiro MIURA, MD
Hideki SHIMOMURA, MD*
Kenichi TSUJITA, MD*
Keisuke OKAMURA, MD
Bo ZHANG, PhD
Atsushi IWATA, MD
Kazuyuki SHIRAI, MD
Kunihiro MATSUO, MD
Hidekazu ARAI, MD*
Keijiro SAKU, MD, FJCC

Abstract

Objectives. 3-Hydroxy-3-methylglutaryl coenzyme A reductase inhibitor (statin) enhances the inhibitory effects of angiotensin-receptor blocker (ARB) on vascular neointimal formation in mice. The present case-control study investigated the efficacy of combined treatment with statin and ARB for preventing restenosis in patients with coronary artery disease.

Methods. We examined 210 patients with angina pectoris undergoing elective coronary stenting for de novo lesions of native coronary arteries. All enrolled patients received aspirin and ticlopidine. The subjects included patients who received no statin (control group, $n = 137$) or started statin treatment (statin group, $n = 73$) with or without ARB treatment after stenting.

Results. The rate of restenosis at 6 months after stent implantation in the statin group (19%) was significantly lower than that in the control group (32%). The restenosis rate in self-expanding Radius stents (23%) was significantly lower than that in balloon-expandable Velocity stents (42%) independent of statin treatment. Patients treated with statins and ARBs were least likely [odds ratio (95% confidence interval): 0.30 (0.12 - 0.74)] to develop coronary restenosis, as assessed by multiple logistic regression analysis.

Conclusions. These findings indicate that combined treatment with statin and ARB after stenting is a useful strategy for the prevention of coronary restenosis.

J Cardiol 2005 Mar; 45(3): 107-113

Key Words

■ Angiotensin (angiotensin receptor blocker) ■ Cardiovascular disease
■ Cholesterol-lowering drugs (statin) ■ Restenosis ■ Stent

福岡大学病院 循環器科: 〒814-0180 福岡市城南区七隈7-45-1; *福岡徳州会病院 循環器科, 福岡
Department of Cardiology, Fukuoka University School of Medicine, Fukuoka; *Division of Cardiology, Fukuoka Tokushukai Hospital, Fukuoka

Address for correspondence: MIURA S, MD, Department of Cardiology, Fukuoka University School of Medicine, Nanakuma 7-45-1, Jonan-ku, Fukuoka 814-0180; E-mail: miuras@cis.fukuoka-u.ac.jp

Manuscript received November 8, 2004; revised December 22, 2004; accepted December 22, 2004

INTRODUCTION

Atherosclerosis is the underlying disorder in most patients with coronary artery disease¹). Statins, which are potent inhibitors of 3-hydroxy-3-methylglutaryl coenzyme A reductase, inhibit cholesterol biosynthesis and have several pleiotropic effects²). Major studies on statins have demonstrated that the reduction of cholesterol levels diminishes the risk of coronary events in patients without known coronary artery disease and reduces both coronary events and total mortality in patients with stable coronary artery disease^{3,4}). In addition, statin therapy is associated with reduced restenosis rates after successful percutaneous transluminal coronary angioplasty^{5,6}) and coronary stent implantation⁷). Stent implantation provides a useful model for assessing the potential relationships between serum markers of inflammation, statin therapy, and atherosclerotic disease progression, which is primarily determined by neointima formation.

Selective angiotensin type 1 (AT₁) receptor inhibition by angiotensin-receptor blocker (ARB) may also be beneficial by inhibiting the deleterious effects of AT₁ receptor activation that lead to inflammation, cell migration, cell proliferation, and oxidative events involved in restenosis, although such effects have not been directly shown in animal models^{8,9}). The first clinical trial to test the potential of ARB administration to prevent restenosis in humans suggested that valsartan may be effective in the prevention of restenosis¹⁰). Interestingly, statin administration enhances the inhibitory effects of ARB on vascular neointimal formation in mice¹¹). Although statins and ARBs may both be useful for preventing restenosis, the efficacy of combined treatment with statin and ARB has not been assessed for preventing restenosis in patients with coronary artery disease.

The present study investigated the rate of restenosis after stent implantation as assessed by coronary angiography in patients with coronary artery disease who received statin and/or ARB therapy in a case-control study. The outcomes were compared using a self-expanding Radius stent¹²) (Boston Scientific) and a balloon-expandable Velocity stent serially.

SUBJECTS AND METHODS

Subjects and design

This study included patients who had significant

coronary stenosis (> 50% luminal narrowing) as defined by coronary angiography and underwent implantation of a Radius or Velocity stent. All patients were selected from among patients who underwent diagnostic coronary angiography for suspected or known coronary atherosclerosis or for other reasons (mostly atypical chest pain) from 2001 to 2003. The ethics committee of Fukuoka University Hospital approved this study and informed consent was obtained from each patient. Patients with heart failure, vascular disease (aortitis treated by prednisolone) or hepatic dysfunction (viral and nonviral, transaminases more than three times the normal value) were excluded. Serum total cholesterol (TC), triglyceride (TG) and high-density lipoprotein cholesterol (HDL-C) levels were determined enzymatically. Patients with TC > 220 mg/dl or TG > 150 mg/dl were considered to have hyperlipidemia, and statin was administered to patients with serum TC over 220 mg/dl. Patients with systolic or diastolic blood pressure > 140 mmHg or 90 mmHg or who were under antihypertensive treatment were considered to have hypertension. Patients who were being treated for diabetes mellitus or who had symptoms of diabetes mellitus and a fasting glucose concentration \geq 126 mg/dl were considered to have diabetes mellitus. Otherwise, the results of a 75-g oral glucose tolerance test were used to identify diabetes mellitus. None of the patients was receiving hormone replacement therapy.

Patients who started to receive or did not receive statin after stenting were defined as the statin group ($n = 73$; 16 females, 57 males, mean age 64 ± 9 years) and control group ($n = 137$; 29 females, 108 males, mean age 67 ± 11 years), respectively. Forty-six patients (63%) received atorvastatin at 10 mg/day, whereas 27 (37%) received pravastatin at 10 mg/day. Patients who were receiving ARB at the time of the initial coronary angiography were excluded. The remaining patients were randomly divided into two groups, and were treated or not with ARB after stenting ($n = 119$ or $n = 91$), respectively. Twenty patients (14%) received 7 ± 2 mg/day of candesartan, 45 (38%) received 59 ± 20 mg/day of valsartan and 54 (45%) received 32 ± 11 mg/day of losartan. All enrolled patients received aspirin and ticlopidine.

Follow-up coronary angiography was performed at 6 months. The rates of restenosis and target lesion revascularization (TLR) were measured.

Table 1 Baseline characteristics

	Control group (n = 137; 65%)	Statin group (n = 73; 35%)	p value
Age(yr)	67 ± 11	64 ± 9	NS
Male	108(79)	57(78)	NS
Body mass index(kg/m ²)	23 ± 3	25 ± 4	<0.01
Hypertension	101(74)	50(68)	NS
Diabetes mellitus	49(36)	21(29)	NS
Hyperlipidemia	19(14)	10(14)	NS
Smoking	73(53)	43(59)	NS
Acute coronary syndrome	68(50)	39(53)	NS
Medication			
Angiotensin converting enzyme inhibitor	18(13)	12(16)	NS
Angiotensin-receptor blocker	77(56)	46(63)	NS
Calcium channel blocker	70(51)	28(38)	NS
Beta-blockers	11(8)	4(5)	NS
Long-acting nitrates	29(21)	12(16)	NS
Number of coronary arteries			
Narrowing > 50%			
1	49(36)	21(29)	NS
2	51(37)	33(45)	NS
3	37(27)	19(26)	NS
Serum total cholesterol(mg/dl)	194 ± 35	237 ± 47	<0.01
Serum triglycerides(mg/dl)	149 ± 96	206 ± 146	<0.01
Serum HDL-C(mg/dl)	47 ± 13	48 ± 10	NS
Serum LDL-C(mg/dl)	117 ± 31	147 ± 47	<0.01

Values are mean ± SD.() %.

HDL-C = high-density lipoprotein cholesterol ; LDL-C = low-density lipoprotein cholesterol.

Statin therapy is an independent predictor for survival at 6 months after coronary intervention¹³), so the internal control in our study was assumed to be adequate.

Coronary angiography

Coronary angiograms were divided into 15 segments according to the classification of the American Heart Association Grading Committee. The presence of stenosis was determined using a computer-assisted coronary angiography analysis system after direct intracoronary injection of isosorbide dinitrate, as described previously¹⁴). Arterial stenosis that caused more than 50% luminal narrowing was considered significant.

Statistical analysis

Statistical analysis was performed using the SAS software package(version 6.12, Statistical Analysis System, SAS Institute Inc.)at Fukuoka University.

Data are shown as the mean ± standard deviation. Categorical and continuous variables were compared between cases and controls by chi-square analysis and analysis of variance, respectively. A value of *p* < 0.05 was considered significant. Associations between the treatment and reduction of restenosis rate were examined by logistic regression analysis. 95% confidence intervals were calculated for the odds ratios.

RESULTS

Patient demographics

The baseline clinical characteristics of the statin and control groups are shown in **Tables 1, 2**. There were no differences between the two groups with respect to age, sex, prevalence of hypertension, diabetes mellitus, hyperuricemia or acute coronary syndrome, medication, or number of coronary arteries(**Table 1**). There was a significant difference in the body mass index. Baseline levels of

Table 2 Lesion and procedural characteristics

Characteristics	Control group (n = 137; 65%)	Statin group (n = 73; 35%)	p value
ACC/AHA lesion classification			
A	7(5)	1(1)	NS
B1	54(39)	25(34)	NS
B2	65(47)	40(55)	NS
C	11(8)	7(10)	NS
Coronary artery			
Left anterior descending	57(42)	25(34)	NS
Left circumflex	49(36)	36(49)	NS
Right	28(20)	12(16)	NS
De novo lesion	131(96)	69(95)	NS
Maximal inflation pressure(atm)	9 ± 3	9 ± 3	NS
Percent stenosis			
Pre-stent(%)	93 ± 6	94 ± 8	NS
Post-stent(%)	4 ± 10	3 ± 8	NS
Stent type			
Radius	105(77)	57(78)	NS
Velocity	32(23)	16(22)	NS
Stent size			
Length(mm)	18 ± 5	18 ± 5	NS
Diameter(mm)	3.6 ± 0.6	3.7 ± 0.5	NS

Continuous values are mean ± SD.() %.

ACC/AHA = American College of Cardiology/American Heart Association.

serum TC, TG and low-density lipoprotein cholesterol(LDL-C) in the control group were significantly higher than those in the statin group, but plasma HDL-C levels were similar in the statin and control groups. There were no significant differences in the systolic blood pressure/diastolic blood pressure (SBP/DBP) between the groups with(+) and without(-) ARBs[pre-SBP/DBP, ARBs(-) group 139 ± 4/75 ± 3 mmHg vs ARBs(+) group 138 ± 4/81 ± 3 mmHg; post-SBP/DBP, ARBs(-) group 139 ± 3/75 ± 2 mmHg vs ARBs(+) group 131 ± 4/76 ± 2 mmHg] In addition, the type and size of stents used did not differ between the two groups, and there were no differences in lesions or other parameters(**Table 2**)

Angiographic analysis and lipid profile

At the 6-month follow-up, there was no significant difference in the serum lipid profiles between the statin and control groups(TC, control group 191 ± 35 vs statin group 185 ± 34 mg/dl; TG, 150 ± 74 vs 162 ± 75 mg/dl; HDL-C, 48 ± 15 vs 49 ± 10 mg/dl; LDL-C, 113 ± 29 vs 109 ±

31 mg/dl). However, the statin group had a significantly lower restenosis rate than the control group (19% vs 32%). The rate of TLR in the statin group (17%) was lower than that in the control group (24%), but this difference was not significant. In addition, the rates of restenosis (23%) and TLR (19%) with a Radius stent were significantly lower than those with a Velocity stent(restenosis 42% and TLR 35%). The statin group had a significantly lower incidence of restenosis than the control group. **Fig. 1** shows the odds ratio for each combination of statin treatment[without(-) or with(+) statin treatment] and the ARB treatment[without (-) or with(+) ARB treatment] Patients treated with statin and ARB showed a significantly higher reduction of restenosis rate[odds ratio(95% confidence interval): 0.30(0.12 - 0.74, p = 0.01 vs no treatment)] These results suggest that combination therapy is useful for reduction of the restenosis rate.

DISCUSSION

The present study demonstrated that combined treatment with statin and ARB is associated with a

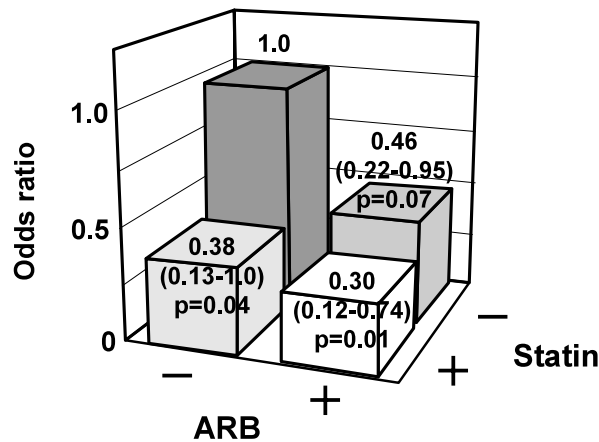


Fig. 1 Odds ratios for the association of combinations of ARB (- or +) and statin (- or +) with the reduction of restenosis rate as assessed by the multiple logistic regression analysis

Odds ratios and 95% confidence intervals are shown. *p* values vs no treatment [ARB (-) and statin (-) group]
ARB = angiotensin-receptor blocker.

significant reduction in the development of restenosis after stent implantation. These findings extend the well-established clinical benefit of statin therapy for reducing morbidity and mortality due to coronary artery disease in patients with stent implantation.

In this study, the self-expanding Radius stent progressively enlarged after implantation without increasing restenosis rates compared to the balloon-expandable Velocity stent, which is consistent with the previous results¹⁵). Although the slow chronic expansion associated with self-expanding stents may cause some neointimal growth, the beneficial and disadvantageous effects of late stent expansion appear to be balanced¹⁶). Since statins have several pleiotropic effects²), including the inhibition of smooth muscle cell migration and proliferation, the promotion of endothelial angiogenesis, anti-thrombotic effects and anti-inflammatory effects, the disadvantageous effects may be prevented by statin therapy and the rate of restenosis may be decreased by the combination of a Radius stent with statin administration. In addition, a Radius stent combined with both statin and ARB administration may

be the most effective method for preventing restenosis, since ARB inhibited neointima formation¹⁷) and blocked the production of fibronectin and/or collagen¹⁸) after percutaneous transluminal coronary angioplasty in animal models. Moreover, recent studies have demonstrated that statin administration prevents angiotensin -induced cellular and organ damage^{19,20}). Statins may enhance the effects of ARBs to prevent vascular neointimal formation through the attenuation of phosphorylation of extracellular signal-regulated kinase activation and phosphorylation of signal transducer and activator of transcription (STAT)1 and STAT3 in mice¹¹). Since statin administration enhanced ARB-induced extracellular signal-regulated kinase activation, STAT1 and STAT3 inhibition, combined treatment with statin and ARB may be more effective than monotherapy for preventing restenosis in patients with coronary artery disease.

Although there was no difference in the serum lipid profiles in the statin and control groups at 6 months, the statin group had a significantly lower restenosis rate than the control group, suggesting that the statin-induced reduction in the rate of restenosis may be due to pleiotropic effects²) independent of cholesterol reduction by statins.

Study limitations

This study has two important limitations. First, rates of restenosis were only assessed by coronary angiography and we did not perform intravascular ultrasonography to analyze stenotic lesions in detail. Second, the sample size is relatively small, which limited our ability to determine significance. Despite these limitations, our data suggest that a Radius stent together with combined statin and ARB therapy is more effective for the elective treatment of restenosis.

CONCLUSIONS

A self-expanding Radius stent may offer some benefit due to long-term expansion to prevent restenosis. Combined treatment with statin and ARB after stenting is useful for the prevention of coronary restenosis.

要 約

ステント留置後の冠動脈再狭窄予防に有用なスタチンと
アンジオテンシン受容体拮抗薬の併用療法

西川 宏明 三浦伸一郎 下村 英紀 辻田 賢一
岡村 圭祐 張 波 岩田 敦 白井 和之
松尾 邦浩 新井 英和 朔 啓二郎

目 的: ヒドロキシメチルグルタリル(HMG-CoA)還元酵素阻害薬のスタチンは, マウスにおいてアンジオテンシン受容体拮抗薬(ARB)による血管内膜増殖抑制効果を増強することが報告されている. そこで今回, 冠動脈疾患の再狭窄抑制に対するスタチンとARBの併用効果について検討した.

方 法: 固有冠動脈の初発病変に待機的ステントを留置した狭心症210例を対象とした. すべての患者はアスピリンとチクロピジンが投与され, ステント留置後のスタチン投与開始の有無により対照群(137例)とスタチン群(73例)の2群とした. さらに, 両群をARB投与開始の有無により4群に分類した.

結 果: スタチン群の6ヵ月後の再狭窄率(19%)は, 対照群(32%)に比べて有意に低値であった. 自己拡張型Radiusステントの再狭窄率(23%)は, スタチン投与の有無によらずバルーン拡張型Velocityステント(42%)に比べて有意に低値であった. 多変量回帰分析では, ARBを併用していた患者において最も再狭窄率が低値であった[オッズ比(95%信頼区間): 0.3(0.12-0.74)].

結 論: スタチンとARBの併用療法は, ステント留置後の冠動脈再狭窄抑制に有用な治療法であることが示唆された.

J Cardiol 2005 Mar; 45(3): 107-113

References

- 1) Kastelein JJ: The future of best practice. Atherosclerosis 1999; **143**(Suppl 1): S17 - S21
- 2) Takemoto M, Liao JK: Pleiotropic effects of 3-hydroxy-3-methylglutaryl coenzyme A reductase inhibitors. Arterioscler Thromb Vasc Biol 2001; **21**: 1712 - 1719
- 3) Sacks FM, Pfeffer MA, Moye LA, Rouleau JL, Rutherford JD, Cole TG, Brown L, Warnica JW, Arnold JM, Wun CC, Davis BR, Braunwald E, for the Cholesterol and Recurrent Events Trial investigators: The effect of pravastatin on coronary events after myocardial infarction in patients with average cholesterol levels. N Engl J Med 1996; **335**: 1001 - 1009
- 4) Shepherd J, Cobbe SM, Ford I, Isles CG, Lorimer AR, MacFarlane PW, McKillop JH, Packard CJ, for the West of Scotland Coronary Prevention Study Group: Prevention of coronary heart disease with pravastatin in men with hypercholesterolemia. N Engl J Med 1995; **333**: 1301 - 1307
- 5) Mulder HJ, Bal ET, Jukema JW, Zwinderman AH, Scholij MJ, van Boven AJ, Bruschke AV: Pravastatin reduces restenosis two years after percutaneous transluminal coronary angioplasty(REGRESS trial). Am J Cardiol 2000; **86**: 742 - 746
- 6) Serruys PW, Foley DP, Jackson G, Bonnier H, Macaya C, Vrolix M, Branzi A, Shepherd J, Suryapranata H, de Feyter PJ, Melkert R, van Es GA, Pfister PJ: A randomized placebo-controlled trial of fluvastatin for prevention of restenosis after successful coronary balloon angioplasty: Final results of the fluvastatin angiographic restenosis(FLARE) trial. Eur Heart J 1999; **20**: 58 - 69
- 7) Walter DH, Fichtlscherer S, Britten MB, Rosin P, Auch-Schwelk W, Schachinger V, Zeiher AM: Statin therapy, inflammation and recurrent coronary events in patients following coronary stent implantation. J Am Coll Cardiol 2001; **38**: 2006 - 2012
- 8) Fogari R, De Gasparo M: Addressing those two that go together: The angiotensin receptors and their role in blood-flow regulation. Blood Press 2001; **10**: 6 - 15
- 9) Prescott MF, Webb RL, Reidy MA: Angiotensin-converting enzyme inhibitor versus angiotensin , AT1 receptor antagonist: Effects on smooth muscle cell migration and proliferation after balloon catheter injury. Am J Pathol 1991; **139**: 1291 - 1296
- 10) Peters S, Gotting B, Trummel M, Rust H, Brattstrom A: Valsartan for the prevention of restenosis after stenting of typeB2/C lesions: The Val-PREST trial. J Inv Cardiol 2001; **13**: 93 - 97
- 11) Horiuchi M, Cui TX, Li Z, Li JM, Nakagami H, Iwai M: Fluvastatin enhances the inhibitory effects of a selective angiotensin type 1 receptor blocker, valsartan, on vascular neointimal formation. Circulation 2003; **107**: 106 - 112
- 12) Kay IP, Sabate M, Van Langenhove G, Heyndrickx GR, Grollier G, Suryapranata H, Hoorntje JC, van der Giessen

- WJ, Morel MA, Disco C, Serruys PW : The ESSEX (European Scimed Stent Experience) study. *Cathet Cardiovasc Intervent* 2000; **50**: 419 - 425
- 13) Chan AW, Bhatt DL, Chew DP, Quinn MJ, Moliterno DJ, Topol EJ, Ellis SG: Early and sustained survival benefit associated with statin therapy at the time of percutaneous coronary intervention. *Circulation* 2002; **105**: 691 - 696
- 14) Saku K, Zhang B, Ohta T, Arakawa K: Quantity and function of high density lipoprotein as an indicator of coronary atherosclerosis. *J Am Coll Cardiol* 1999; **33**: 436 - 443
- 15) Yu ZX, Tamai H, Kyo E, Kosuga K, Hata T, Okada M, Nakamura T, Komori H, Tsuji T, Takeda S, Motohara S, Uehata H: Comparison of the self-expanding Radius stent and the balloon-expandable Multilink stent for elective treatment of coronary stenoses: A serial analysis by intravascular ultrasound. *Cathet Cardiovasc Intervent* 2002; **56**: 40 - 45
- 16) Kobayashi Y, Honda Y, Christie GL, Teirstein PS, Bailey SR, Brown CL, Matthews RV, De Franco AC, Schwartz RS, Goldberg S, Popma JJ, Yock PG, Fitzgerald PJ: Long-term vessel response to a self-expanding coronary stent: A serial volumetric intravascular ultrasound analysis from the ASSURE Trial: A Stent vs. Stent Ultrasound Remodeling Evaluation. *J Am Coll Cardiol* 2001; **37**: 1329 - 1334
- 17) Wilson DP, Saward L, Zahradka P, Cheung PK: Angiotensin receptor antagonists prevent neointimal proliferation in a porcine coronary artery organ culture model. *Cardiovasc Res* 1999; **42**: 761 - 772
- 18) Kim S, Ohta K, Hamaguchi A, Omura T, Yukimura T, Miura K, Inada Y, Ishimura Y, Chatani F, Iwao H: Angiotensin type receptor antagonist inhibits the gene expression of transforming growth factor-beta 1 and extracellular matrix in cardiac and vascular tissues of hypertensive rats. *J Pharmacol Exp Ther* 1995; **273**: 509 - 515
- 19) Wassmann S, Laufs U, Baumer AT, Muller K, Konkol C, Sauer H, Bohm M, Nickenig G: Inhibition of geranylgeranylation reduces angiotensin-mediated free radical production in vascular smooth muscle cells: Involvement of angiotensin AT1 receptor expression and Rac1 GTPase. *Mol Pharmacol* 2001; **59**: 646 - 654
- 20) Oi S, Haneda T, Osaki J, Kashiwagi Y, Nakamura Y, Kawabe J, Kikuchi K: Lovastatin prevents angiotensin-induced cardiac hypertrophy in cultured neonatal rat heart cells. *Eur J Pharmacol* 1999; **376**: 139 - 148