

## Beneficial Effects of Human Atrial Natriuretic Peptide on Renal Function in a Patient With Repeated Coronary Interventions: A Case Report

Oscar Luis PAREDES, MD  
Junya SHITE, MD, FJCC  
Toshiro SHINKE, MD  
Yusuke IMURO, MD  
Ryouhei YOSHIKAWA, MD  
Satoshi WATANABE, MD  
Toru OZAWA, MD  
Hiromasa OTAKE, MD  
Daisuke MATSUMOTO, MD  
Daisuke OGASAWARA, MD  
Mitsuhiro YOKOYAMA, MD,

### Abstract

Among percutaneous coronary intervention post procedural complications, renal acute dysfunction due to administration of contrast agent is commonly seen in patients with pre-existing renal impairment, especially with co-existent diabetes mellitus and/or congestive heart failure. Although several strategies have been proposed to ameliorate this condition, their effects are inconsistent. A 66-year-old diabetic man at high risk for this complication underwent three distinct percutaneous coronary intervention procedures. Different strategies were used during each intervention to prevent the development of contrast medium-induced nephropathy. Dramatic renal protection was observed with human atrial natriuretic peptide administration or hemofiltration, whereas saline hydration had no apparent effect.

J Cardiol 2005 Oct; 46(4): 161 - 164

### Key Words

■Angiography      ■Natriuretic peptide, atrial      ■Contrast media  
■Renal function      ■Coronary intervention

### INTRODUCTION

Radiocontrast-induced nephropathy (RCIN) is considered to be the third most common cause of in-hospital acquired acute renal failure, and is associated with in-hospital and long term high morbidity and mortality<sup>1-5</sup>. RCIN is usually defined as

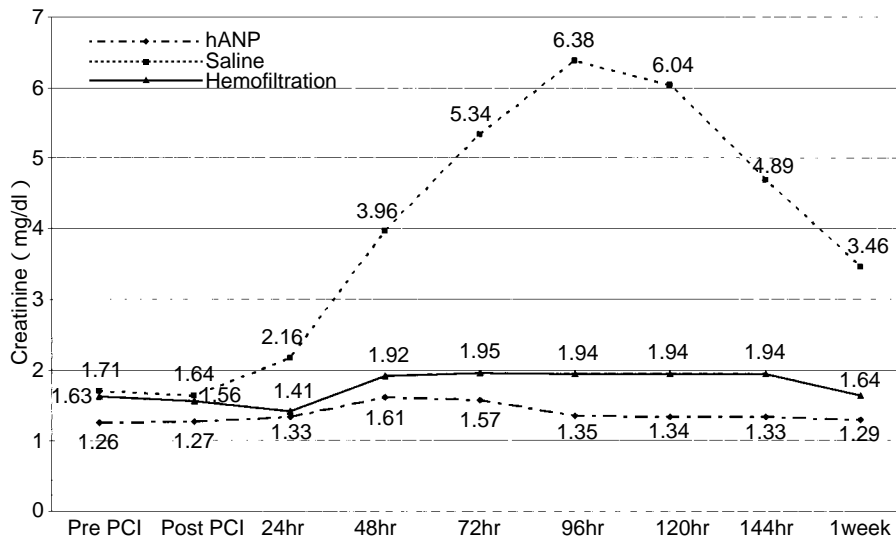
acute deterioration of the renal function that occurs within 72 hr after intravascular administration of contrast agents, and is characterized by an increase in serum creatinine of 25% or > 0.5 mg/dl from the baseline level, in the absence of another etiology<sup>6,7</sup>. Strategies to diminish the incidence involve hydration, pharmacological manipulation with renal

神戸大学大学院医学系研究科 循環呼吸器病態学: 〒650-0017 神戸市中央区楠町7-5-1

Division of Cardiovascular and Respiratory Medicine, Department of Internal Medicine, Kobe University Graduate School of Medicine, Kobe

**Address for correspondence:** SHITE J, MD, FJCC, Division of Cardiovascular and Respiratory Medicine, Department of Internal Medicine, Kobe University Graduate School of Medicine, Kusunoki-cho 7-5-1, Chuo-ku, Kobe 650-0017; E-mail: shite@med.kobe-u.ac.jp

Manuscript received February 4, 2005; revised March 22, 2005; accepted March 23, 2005



**Fig. 1** Changes in serum creatinine level after coronary intervention with the three different strategies  
hANP = human atrial natriuretic peptide; PCI = percutaneous coronary intervention.

vasodilators, endothelin receptor antagonists or antioxidants, and even prophylactic continuous hemofiltration or hemodialysis<sup>1,6,8-10</sup>). Some studies have shown that human atrial natriuretic peptide (hANP) has renal protective effects<sup>2,11-13</sup>), but the beneficial effects for RCIN prevention have not been clearly shown. We treated a diabetic patient with these strategies for preventing RCIN and compare the results.

### CASE REPORT

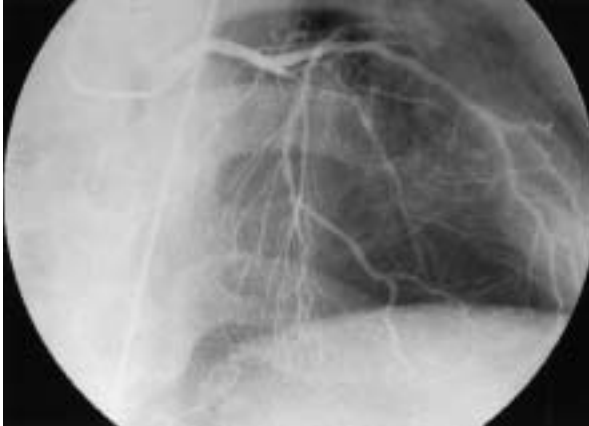A diabetic, hypertensive 66-year-old man was admitted to the hospital for evaluation of angina pectoris. Treadmill exercise test showed ST-segment depression in leads I, aVF, V4-V6. Laboratory test showed hemoglobin A<sub>1c</sub> of 4.5% while taking glibenclamide 2.5 mg/day. Serum blood urea nitrogen was 22 mg/dl and serum creatinine was 1.26 mg/dl. Estimated creatinine clearance was 55 ml/min. Coronary angiography revealed a long diffuse stenosis of 90% in the left anterior descending artery segments 6 to 7. Percutaneous coronary intervention (PCI) was scheduled 6 days after diagnostic catheterization. The preventive strategy for RCIN used hANP (0.025 µg/kg/min) co-administered with 0.9% saline (60 ml/hr) starting 2 hr prior to the PCI and continued for 24 hr. During the intervention, the rotator was required to remove the diffusely calcified plaque and diagonal branch protection was performed with left anterior descending artery stenting. A total of 450 ml

non-ionic contrast medium was used. The serum creatinine level increased to 27% above the baseline 48 hr later, but decreased to the previous level rapidly (Fig. 1). The clinical course was good and the patient was discharged without any symptoms.

Four months later, the patient came to our hospital with recurrent chest pain. On admission, blood urea nitrogen was 20 mg/dl, and serum creatinine was 1.71 mg/dl with estimated creatinine clearance 40 ml/min. Diagnostic catheterization was planned with possible on-site PCI. Reno-protection used only 0.9% saline hydration; starting 2 hr before the procedure at 100 ml/hr, then reduced to 60 ml/hr after PCI and continued for 24 hr.

The finding was a diffuse in-stent restenosis with 99% occlusion (Fig. 2). Plain balloon angioplasty was successfully performed as treatment. The whole procedure (coronary angiography, left ventriculography and PCI) required 220 ml of contrast medium. A great increase in the serum creatinine from baseline level was observed with a maximum peak at 4th day (6.38 mg/dl, 273%), taking 2 weeks to return to the previous level (Fig. 1).

Unfortunately, 3 months later, the patient came again to the emergency room with increasing chest pain with dyspnea. Electrocardiography showed 2 mm ST elevation in I-V4. Troponin T was positive but creatine kinase-MB was within the normal range. Blood urea nitrogen was 28 mg/dl, serum creatinine was 1.63 mg/dl and creatinine clearance was 35 ml/day. Echocardiography revealed severe



**Fig. 2** Left coronary angiography( cranial view ) showing the in-stent restenosis before second intervention

deterioration of left ventricular function. At that time, more aggressive renal protection was considered necessary. Continuous hemofiltration with fluid replacement of 1,000 ml/hr starting 2 hr before the PCI and continued for 18 hr was performed. Coronary angiography showed 99% in-stent restenosis and cutting balloon angioplasty was performed. Volume of contrast media was 180 ml. Serum creatinine increased to 1.95 mg/dl (20% from baseline) at 72 hr after intervention and returned to the previous level after 6 days ( **Fig. 1** )

## DISCUSSION

Guidelines to prevent RCIN emphasize the importance of identifying patients at high risk before intervention<sup>14,15</sup>. Contrast volume should be reduced and volume expansion with saline infusion should be considered to assure a good renal perfusion. Moreover, the use of nephrotoxic drugs should be avoided<sup>14</sup>.

The most popular method to prevent RCIN is volume expansion with saline infusion ( 1 ml/kg-body weight/hr ) starting before the use of contrast medium and continued afterward<sup>15,16</sup>. However, the best benefits are observed only in patients with mild renal impairment and this method is not suitable in all patients.

Some studies demonstrated that hANP has a protective effect for various etiologies of renal dysfunction<sup>10,17,18</sup>. hANP has natriuretic effects,

increasing glomerular filtration rate by dilating afferent arterioles while constricting the efferent arterioles. hANP also antagonizes the secretion of renin, aldosterone and vasopressin. Animal experiments have suggested its usefulness in RCIN<sup>2</sup>. However, clinical trials could not show substantial effects, with conflicting results especially in diabetic patients<sup>9,10,18</sup>. This discrepancy may be due to the presence of heterogeneity in the response to hANP for each patient.

The present patient was at high risk of developing RCIN, and underwent coronary intervention repetitively, so we had the chance to assess the effects of different strategies. Saline + hANP protocol was apparently better than only saline, considering the lower increase of serum creatinine and rapid recovery to the previous level. But there are some limitations for the comparison: the renal function pre-interventional statuses were not exactly the same, and the amount of contrast media used in the hANP protocol ( 450 ml ) was almost twice as much as that in only saline. In spite of these conflicting factors, we believe that the big difference in the increase of serum creatinine after intervention between two strategies is strongly indicative.

At the third intervention, we selected prophylactic continuous hemofiltration to obtain effective renal protection without volume overload. We had a relative low increase of serum creatinine ( 19% ) with return to the previous level within 1 week. Continuous hemofiltration starting before PCI and continued for 24 hr afterward reduced the incidence of RCIN<sup>1</sup>. The main feature of the protective effect was attributed to the high volume of fluid administered, without fluid loss or volume overload, and maintaining hemodynamic stability. This also leads to maintenance of renal perfusion and rapid dilution of contrast medium. However, the complexity and high cost involved in this method is the biggest disadvantage as a routine way of preventing RCIN.

Comparing all distinct variables at each intervention, we think that hANP infusion with saline hydration is an effective method to prevent RCIN and was as effective as hemofiltration in our patient. With further studies, we should clarify what kind of patient would most benefit from hANP infusion.

## 要 約

冠動脈形成術による造影剤腎症に対しヒト心房性ナトリウム利尿ペプチドが  
有用であった1例

オスカル・ルイス・パルデス 志手 淳也 新家 俊郎 伊室 祐介  
吉川 糧平 渡邊 哲史 小澤 徹 大竹 寛雅  
松本 大典 小笠原大介 横山 光宏

経皮的冠動脈形成術施行後に腎機能はしばしば悪化する。糖尿病やうっ血性心不全を合併している腎障害例では、その頻度が著しい。造影剤起因性腎障害を軽減すべく種々の方法が試みられているが、その効果は様でない。我々は糖尿病性腎症を合併した66歳、男性に対し、3回の冠動脈形成術を施行し、おのおの別の方法により腎障害軽減効果を比較することができた。結果は、生理的食塩水のみによる輸液は効果が少なかったのに対し、ヒト心房性Na利尿ペプチド+生理的食塩水による輸液および血液濾過が良好な腎保護効果を示した。

*J Cardiol* 2005 Oct; 46(4): 161 - 164

## References

- 1) Maranezi G, Marana I, Lauri G, Assanelli E, Grazi M, Campodonico J, Trabattini D, Fabbiochi F, Montorsi P, Bartorelli A: The prevention of radiocontrast-agent-induced nephropathy by hemofiltration. *N Engl J Med* 2003; **349**: 1330 - 1340
- 2) Margulies KB, McKinley LJ, Cavero PG, Burnett JC Jr: Induction and prevention of radiocontrast-induced nephropathy in dogs with heart failure. *Kidney Int* 1990; **38**: 1101 - 1108
- 3) Baker CS, Wragg A, Kumar S, De Palma R, Baker LR, Knight CJ: A rapid protocol for the prevention of contrast-induced renal dysfunction: The RAPPID study. *J Am Coll Cardiol* 2003; **41**: 2114 - 2118
- 4) McCullough PA, Wolyn R, Rocher LL, Levin RN, O'Neill WW: Acute renal failure after coronary intervention: Incidence, risk factors, and relationship to mortality. *Am J Med* 1997; **103**: 368 - 375
- 5) Solomon R: Contrast-medium-induced acute renal failure. *Kidney Int* 1998; **53**: 230 - 342
- 6) Levin ER, Gardner DG, Samson WK: Natriuretic peptides. *N Engl J Med* 1998; **339**: 321 - 328
- 7) Morcos SK, Thomsen HS, Webb JA, for the Contrast Media Safety Committee, European Society of Urogenital Radiology(ESUR): Contrast-media-induced nephrotoxicity: A consensus report. *Eur Radiol* 1999; **9**: 1602 - 1613
- 8) Ahluwaila A, MacAllister RJ, Hobbs AJ: Vascular actions of natriuretic peptides: Cyclic GMP-dependent and -independent mechanisms. *Basic Res Cardiol* 2004; **99**: 83 - 89
- 9) Solomon R, Werner C, Mann D, D'Elia J, Silva P: Effects of saline, mannitol, and furosemide to prevent acute decreases in renal function induced by radiocontrast agents. *N Engl J Med* 1994; **331**: 1416 - 1420
- 10) Weisberg LS, Kurnik PB, Kurnik BR: Risk of radiocontrast nephropathy in patients with and without diabetes mellitus. *Kidney Int* 1994; **45**: 259 - 265
- 11) Semigran MJ, Aroney CN, Herrmann HC, Dec GW Jr, Boucher CA, Fifer MA: Effects of atrial natriuretic peptide on myocardial contractile and diastolic function in patients with heart failure. *J Am Coll Cardiol* 1992; **20**: 98 - 106
- 12) Vesely DL: Natriuretic peptides and acute renal failure. *Am J Physiol* 2003; **285**: 167 - 177
- 13) Pollock DM, Opgenorth TJ: Atrial natriuretic peptides in the treatment of acute renal failure. *Ren Fail* 1993; **15**: 439 - 449
- 14) Morcos SK: Contrast media-induced nephrotoxicity: Questions and answers. *Br J Radiol* 1998; **71**: 357 - 365
- 15) Morcos SK: Prevention of contrast media nephrotoxicity: The story so far. *Clin Radiol* 2004; **59**: 381 - 389
- 16) Mueller C, Bueker G, Buertner HJ, Petersen J, Perruchoud AP, Eriksson U, Marsch S, Roskamm H: Prevention of contrast media-associated nephropathy: Randomized comparison of 2 hydration regimens in 1620 patients undergoing angioplasty. *Arch Intern Med* 2002; **162**: 329 - 336
- 17) Allgren RL, Marbury T, Rahman S, Weisberg LS, Fenves AZ, Lafayette RA, Sweet RM, Genter FC, Kurnik BR, Conger JD, Sayegh MH, for the Auriculin Anaritide Acute Renal Failure Study Group: Anaritide in acute tubular necrosis. *N Engl J Med* 1997; **336**: 828 - 834
- 18) Kurnik BR, Allgren RL, Genter FC, Solomon RJ, Bates ER, Weisberg LS: Prospective study of atrial natriuretic peptide for the prevention of radiocontrast-induced nephropathy. *Am J Kidney Dis* 1998; **31**: 674 - 680