

## Sequential Use of Aminophylline and Theophylline for the Treatment of Atropine-Resistant Bradycardia After Spinal Cord Injury: A Case Report

Tomohiro SAKAMOTO, MD\*  
Tsuneaki SADANAGA, MD  
Tomoki OKAZAKI, MD

### Abstract

A 66-year-old Japanese man was brought to our emergency department after he was accidentally compressed into a lateral groove. Physical examination revealed pinprick sensory level of T4 and motor level of C7. On the 4th hospital day, electrocardiography suddenly showed sinus bradycardia of 33 beats/min. Bolus injection of 0.5 mg of atropine sulphate was not effective. Bolus injection of aminophylline was administered followed by continuous infusion. His heart rate increased and remained stable at 60 to 70 beats/min. Therapy was switched from aminophylline to oral theophylline and continued for about 5 weeks, with no recurrence of bradycardia. Use of xanthine derivatives is thought to be an effective, safe and simple treatment for spinal cord injury-induced bradycardia.

J Cardiol 2007 Feb; 49(2): 91-96

### Key Words

■Bradycardia (aminophylline, theophylline)

■Antiarrhythmia (atropine)

### INTRODUCTION

Bradycardia and cardiac arrest are complications observed in the acute phase of cervical spinal cord injury.<sup>1,2)</sup> The bradycardia is self-limited, disappearing within 3-5 weeks after the onset of paraplegia, and usually does not require implantation of a permanent pacemaker.<sup>3)</sup> However, medical treatment for the disorder often fails and temporary transvenous ventricular pacing is required.<sup>4,5)</sup> Previously, oral theophylline therapy was found to be beneficial in patients with sick sinus syndrome.<sup>6)</sup> However, whether this therapy is also effective in treating bradycardia associated with spinal cord injury was unclear. Recently, the use of aminophylline<sup>7)</sup> or theophylline<sup>8)</sup> was reported as a useful alternative treatment for severe symptomatic brady-

cardia in patients with spinal cord injury from the U.S. and Germany, respectively. In this report we describe a Japanese case of cervical spinal cord injury complicated with atropine-resistant severe bradycardia, which was managed by sequential administration of both aminophylline and theophylline.

### CASE REPORT

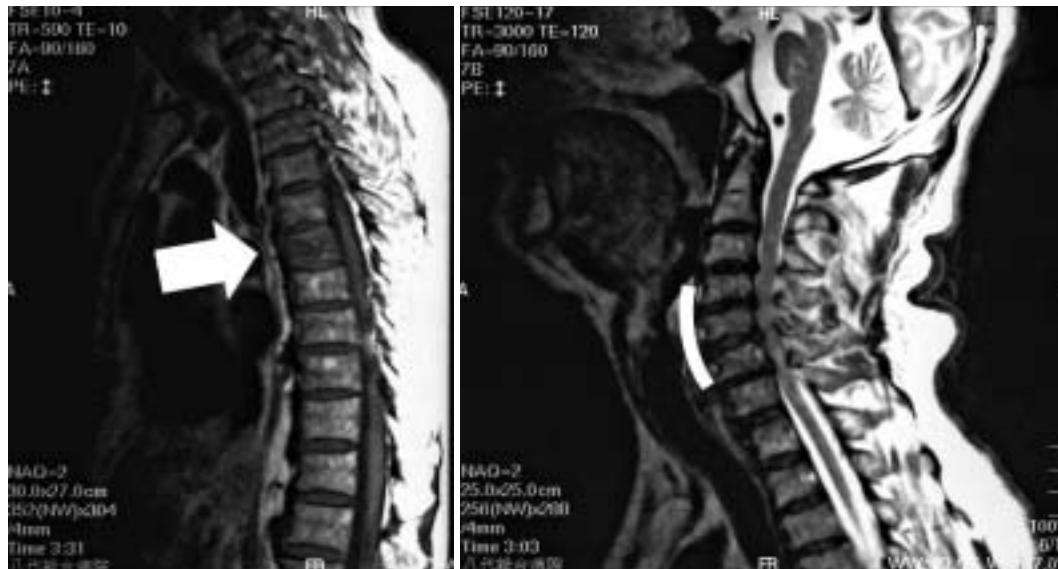
A 66-year-old Japanese man with no significant medical history was brought to our emergency department after he was accidentally compressed into a lateral groove. He had symptoms of neck pain, inability to move his legs, and lack of sensation below his breast. His vital signs were stable on admission, and physical examination revealed pinprick sensory level of T4 and motor level of C8

健康保険八代総合病院 循環器科: 〒866-8660 熊本県八代市松江城町 2-26; \*(現) 済生会熊本病院心臓血管センター 内科: 〒861-4193 熊本県熊本市近見 5-3-1

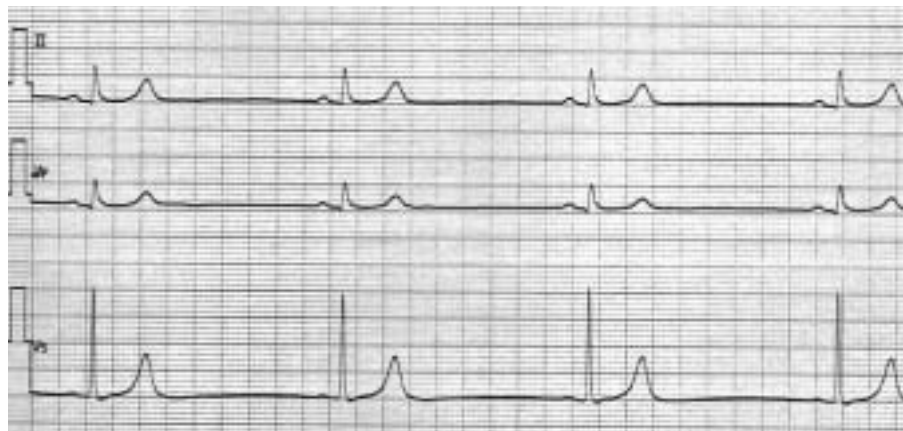Department of Cardiovascular Medicine, Health Insurance Yatsushiro General Hospital, Kumamoto; \*(present) Division of Cardiology, Cardiovascular Center, Saiseikai Kumamoto Hospital, Kumamoto

**Address for correspondence:** SAKAMOTO T, MD, Division of Cardiology, Cardiovascular Center, Saiseikai Kumamoto Hospital, Chikami 5-3-1, Kumamoto, Kumamoto 861-4193; E-mail: tom@kumamoto-u.ac.jp

Manuscript received September 13, 2006; revised October 30, 2006; accepted November 2, 2006



**Fig. 1 Magnetic resonance images of the thoracic and cervical spinal cord**  
 Fresh compression fracture of the T6 (left, white arrow) and spinal canal stenosis at C5/6 and C6/7 with abnormal signal of the cervical spinal cord (right, white line) were observed.

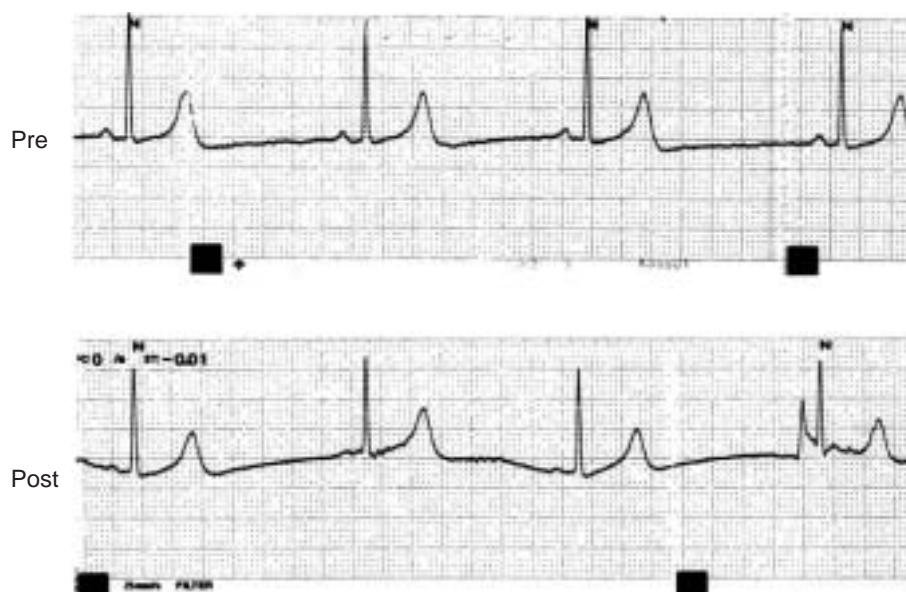

**Fig. 2 Three lead electrocardiogram**  
 Sinus bradycardia (33 beats/min) was recorded at the time of symptom onset.

(American Spinal Association Impairment Scale,<sup>9)</sup> Class A-Central Cord). Magnetic resonance imaging revealed compression fracture at T6 and spinal canal stenosis at C5/6 and C6/7 with intramedullary abnormal signals (Fig. 1). The patient was considered to have cervical spinal cord injury induced by strong traumatic stress at pre-existing cervical spondylosis. Methylprednisolone 30 mg/kg was administered intravenously for 15 min followed 45 min later by continuous infusion (5.4 mg/kg/hr) for the next 23 hr.

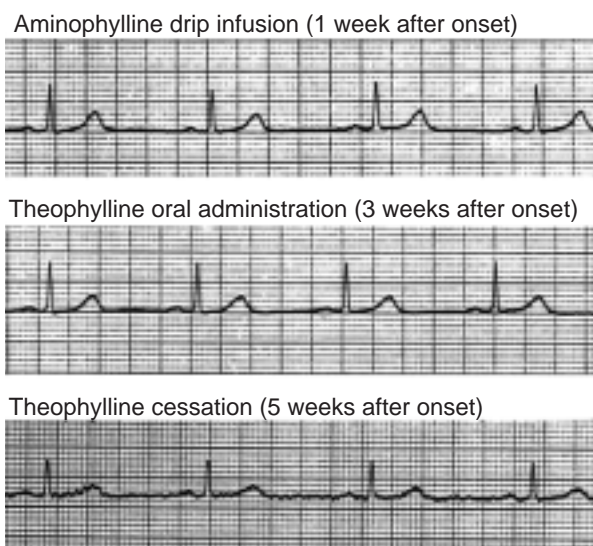
On the 4th hospital day, he suddenly complained

of chest discomfort, cold, and diaphoresis. Electrocardiography (ECG) revealed sinus bradycardia of 33 beats/min and his blood pressure dropped to 60 mmHg systolic during this episode (Fig. 2). There were no significant ischemic ST-T changes or new bundle branch block in the 12-lead ECG. Bolus injection of atropine sulphate 0.5 mg was not effective to increase his heart rate (Fig. 3). Bolus injection of aminophylline (250 mg) was administered followed by continuous infusion (0.5 mg/kg/hr). His heart rate increased within 1 hr and remained stable at 60 to 70 beats/min during



**Fig. 3** Bedside electrocardiograms before and after atropine injection

Administration of intravenous atropine (0.5 mg) was not effective to increase the heart rate.



**Fig. 4** Comparison of lead II of 12-lead electrocardiogram during aminophylline and theophylline therapy

Heart rate was 57 beats/min during drip infusion of aminophylline (upper), 63 beats/min during oral administration of theophylline (middle), and 58 beats/min with no medications (lower).

the infusion (Fig. 4, upper panel). On the 19th hospital day, intravenous aminophylline therapy was switched to oral theophylline (400 mg/day) and discontinued after the 38th hospital day with no recurrence of bradycardia (Fig. 4, middle and lower pan-

els). The chart of his heart rate and blood pressure during the entire clinical course is shown in response to the treatment (Fig. 5). The drug levels in the blood were  $11.2 \mu\text{g/ml}$  during aminophylline infusion and  $9.7 \mu\text{g/ml}$  after switching to oral theophylline.

## DISCUSSION

This Japanese patient with spinal cord injury-related severe bradycardia was successfully managed with aminophylline administered intravenously during the acute phase followed by oral theophylline. The correction of the bradycardia was most likely due to the drugs, although the natural course of the disease may have been responsible.

Cardiovascular abnormalities associated with acute spinal cord injury are observed more often with severe cervical cord injury compared with milder cervical cord injury or thoracolumbar cord trauma.<sup>1)</sup> Persistent bradycardia defined as mean heart rate for at least 1 day  $< 60$  beats/min was observed in all of 31 patients with severe cervical cord injury and mean heart rate  $< 45$  beats/min in 71%. The occurrence of persistent bradycardia peaked 4 days after injury. The onset period of severe sinus bradycardia in the present case was consistent with that report.

The cardiac abnormality underlying cervical cord injury-induced bradycardia may be due to the acute

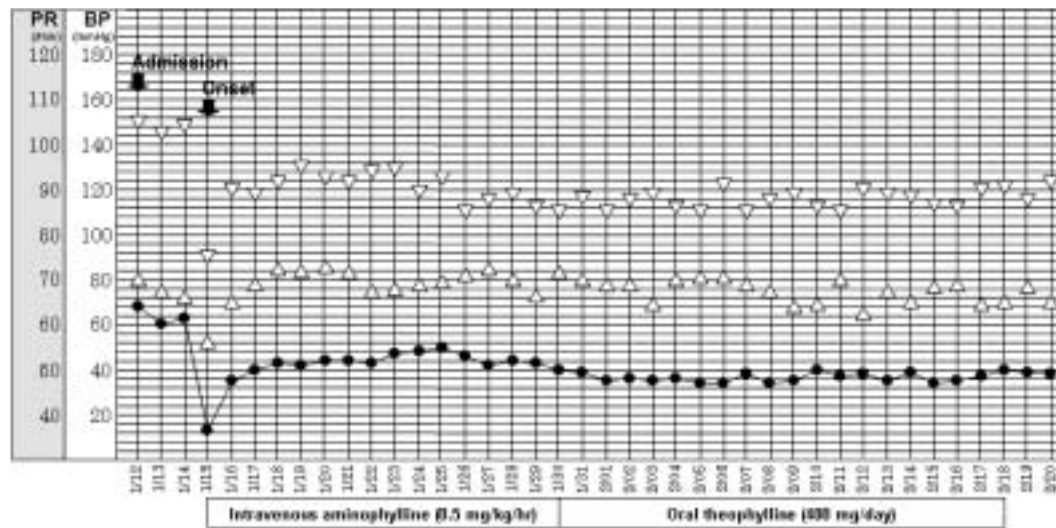


Fig. 5 Chart of heart rate and blood pressure during the clinical course  
 : PR( pulse rate ) , : BP( blood pressure )

autonomic imbalance imposed on the heart by a cervical cord lesion. Sympathetic innervation exits the spinal cord in preganglionic fibers at the 1st through 4th thoracic levels. On the other hand, parasympathetic control is exerted through the vagus nerve, which originates at the level of the medulla oblongata. Therefore, injury to the cervical cord could completely disrupt the cardiac sympathetic influences from higher centers whereas the parasympathetic control remains intact. This might be the reason why the use of atropine, which relatively activates sympathetic tone by reducing parasympathetic activity, was not effective to increase heart rate.

Besides atropine, 0.5 mg repeated to a total dose of 3 mg, epinephrine ( 2 - 10  $\mu$ g/min ) or dopamine ( 2 - 10  $\mu$ g/kg/min ) infusions are recommended for the management of symptomatic bradycardia with poor perfusion in the setting of cardiopulmonary resuscitation and emergency cardiovascular care.<sup>10)</sup> However, in contrast to bradycardia associated with acute coronary syndromes, which is promptly reversed by effective reperfusion with percutaneous coronary intervention, the bradycardia observed with spinal cord injury lasts 3 to 5 weeks.<sup>3)</sup> Therefore, the use of dopamine or epinephrine is not suitable in this clinical setting because of their potential hazardous effects on the heart and vasculature in extended use. In some cases of atropine-resistant bradycardia due to spinal cord injury, transvenous ventricular pacing is used.<sup>4,5)</sup> However,

extended use of a transvenously inserted pacemaker lead should be avoided if at all possible because of the risk of deep vein thrombosis due to prolonged bed rest. Furthermore, the sinus bradycardia after spinal cord injury is self-limiting in its natural course.<sup>1)</sup> Taking these factors into consideration, we tried to use xanthine derivatives in this specific Japanese patient instead of catecholamines or a pacemaker in accordance with the previously treated Caucasian patients.<sup>7,8)</sup>

Xanthine derivatives such as aminophylline and theophylline exert positive chronotropic effects on the sinoatrial and atrioventricular node cells. Possible mechanisms of the xanthine derivatives include antagonism of the negative chronotropic effects of adenosine by competitive blocking of extracellular adenosine receptors,<sup>11)</sup> release of endogenous catecholamines from sympathetic nerve endings and adrenergic medulla,<sup>12)</sup> and inhibition of phosphodiesterase ( PDE ) leading to an increase in cyclic adenosine monophosphate with a subsequent rise in catecholamines.<sup>13)</sup> The ischemic metabolite adenosine was unlikely to be involved in our case, and higher serum concentration of the drug of as much as  $10^{-5}$  to  $10^{-4}$  mol/l is needed to release endogenous catecholamine,<sup>14)</sup> so we hypothesized that the xanthine derivatives worked mainly by inhibiting PDE. Extended use of xanthine derivatives might also be somehow harmful because of the PDE inhibition. Tremor, seizure, nausea, and hyperventilation are all typical adverse

effects of the drugs.

These agents have been used to treat bradycardia associated with acute myocardial ischemia, especially with inferior myocardial infarction<sup>15,16)</sup> and sick sinus syndrome.<sup>6)</sup> In addition, the effects of a relatively large dose of aminophylline (300 mg bolus followed by 5 mg/kg/hr) and a mild dose of theophylline (200 mg p.o. followed by 100 mg every 8 hr) on spinal cord injury-induced bradycardia were also reported.<sup>7,8)</sup> In our case, 0.5 mg/kg/hr of continuous infusion of aminophylline after an intravenous loading dose of 250 mg was effective in increasing the heart rate to 57 beats/min. The blood drug concentration achieved in our patient was similar to those achieved when these agents are used for bronchodilation. The initial intravenous infusion of aminophylline was switched to oral administration of a sustained-release theophylline tablet (200 mg twice daily). The same blood concentration was obtained and bradycardia did not recur

after this change of agent. Although theophylline is an effective drug to treat bradycardia related to spinal cord injury, the therapeutic dose of the drug could vary by race, and the level and extent of spinal cord injury. This therapy appears to be as effective in Japanese as in Caucasians. Our case suggests that the initial doses of xanthine derivatives are similar to those used in the treatment of bronchial asthma. We need further experience of lower doses of the drugs for this purpose.

In summary, bradycardia which is associated with acute spinal cord injury can be successfully treated in Japanese patients with the serial use of aminophylline and theophylline. This therapy may be an effective alternative to transvenous ventricular pacing or extended use of catecholamine in patients with atropine-resistant bradycardia. A randomized, controlled trial is needed to validate the widespread use of xanthine derivatives in this common but serious clinical setting.

## 要 約

### 頸部脊椎損傷後アトロピン耐性高度徐脈におけるアミノフィリン およびテオフィリン投与の有効性

坂本 知浩 定永 恒明 岡崎 智樹

症例は66歳の男性。歩行中に側溝に転落して動けなくなっているところを発見され、救急搬送された。来院時のバイタルは正常であったが、T4レベルの感覚障害およびC7レベルの運動機能障害を呈していた。頸部脊椎損傷の診断によりメチルプレドニゾロンの持続投与が行われた。第4病日、冷汗を伴う胸部苦悶が出現し、モニター心電図上、心拍数33/minの洞性徐脈を呈した。硫酸アトロピンが無効であったため、アミノフィリン250mgの静注に引き続き0.5mg/kg/hrの持続投与を行ったところ、心拍数は60-70/minに上昇し症状も消失した。第19病日に経口のテオフィリン(400mg)に切り替えられ、第38病日に中止されたが、再発を認めなかった。静注および経口での薬物血中濃度はそれぞれ11.2および9.7 μg/mlであった。キサンチン誘導体投与は、頸部脊椎損傷後の徐脈に対し有効、安全かつ簡便な治療法であると考えられた。

*J Cardiol* 2007 Feb; 49(2): 91-96

## References

- 1) Lehmann KG, Lane JG, Piepmeier JM, Batsford WP: Cardiovascular abnormalities accompanying acute spinal cord injury in humans: Incidence, time course and severity. *J Am Coll Cardiol* 1987; **10**: 46-52
- 2) Vallbona C, Cardus D, Spencer WA, Hoff HE: Patterns of sinus arrhythmia in patients with lesions of the central nervous system. *Am J Cardiol* 1965; **16**: 379-389
- 3) Winslow EB, Lesch M, Talano JV, Meyer PR: Spinal cord injuries associated with cardiopulmonary complications. *Spine* 1986; **11**: 809-812
- 4) Silbert PL, Davis JM: Late asystole in high cervical spinal cord injury: Case report. *Paraplegia* 1990; **28**: 137-140
- 5) Gilgoff IS, Ward SL, Hohn AR: Cardiac pacemaker in high spinal cord injury. *Arch Phys Med Rehabil* 1991; **72**: 601-603
- 6) Saito D, Matsubara K, Yamanari H, Obayashi N, Uchida S, Maekawa K, Sato T, Mizuo K, Kobayashi H, Haraoka S: Effects of oral theophylline on sick sinus syndrome. *J Am Coll Cardiol* 1993; **21**: 1199-1204
- 7) Pasnoori VR, Leesar MA: Use of aminophylline in the

- treatment of severe symptomatic bradycardia resistant to atropine. *Cardiol Rev* 2004; **12**: 65 - 68
- 8 ) Schulz-Stubner S: The use of small-dose theophylline for the treatment of bradycardia in patients with spinal cord injury. *Anesth Analg* 2005; **101**: 1809 - 1811
- 9 ) Marino RJ, Barros T, Biering-Sorensen F, Burns SP, Donovan WH, Graves DE, Haak M, Hudson LM, Priebe MM; ASIA Neurological Standards Committee 2002: International standards for neurological classification of spinal cord injury. *J Spinal Cord Med* 2003 ; **26**( Suppl 1 ): S50 - S56
- 10 ) Anonymous : 2005 American heart association guidelines for cardiopulmonary resuscitation and emergency cardiovascular care : Part 7.3 : Management of symptomatic bradycardia and tachycardia. *Circulation* 2005 ; **112** : IV 67 - IV 77
- 11 ) Belardinelli L, Fenton RA, West A, Linden J, Althaus JS, Berne RM: Extracellular action of adenosine and the antagonism by aminophylline on the atrioventricular conduction of isolated perfused guinea pig and rat hearts. *Circ Res* 1982; **51**: 569 - 579
- 12 ) Westfall DP, Fleming WW: Sensitivity changes in the dog heart to norepinephrine, calcium and aminophylline resulting from pretreatment with reserpine. *J Pharmacol Exp Ther* 1968; **159**: 98 - 106
- 13 ) Rall TW: Role of adenosine 3',5'-monophosphate (cyclic AMP) in actions of catecholamines. *Pharmacol Rev* 1972; **24**: 399 - 409
- 14 ) Ellenbogen KA, Szentpetery S, Katz MR: Reversibility of prolonged chronotropic dysfunction with theophylline following orthotopic cardiac transplantation. *Am Heart J* 1988; **116**: 202 - 206
- 15 ) Strasberg B, Bassevich R, Mager A, Kusniec J, Sagie A, Sclarovsky S: Effects of aminophylline on atrioventricular conduction in patients with late atrioventricular block during inferior wall acute myocardial infarction. *Am J Cardiol* 1991; **67**: 527 - 528
- 16 ) Altun A, Kirdar C, Ozbay G: Effect of aminophylline in patients with atropine-resistant late advanced atrioventricular block during acute inferior myocardial infarction. *Clin Cardiol* 1998; **21**: 759 - 762