

## Progressive Congestive Heart Failure Due to Common Iliac Arteriovenous Fistula: A Case Report

Naoyuki SATA, MD  
Kiyohisa HIRAMINE, MD  
Takashi HORINOUCI, MD  
Shigeru AMITANI, MD  
Kenkichi MIYAHARA, MD  
Chieri KIMURA, MD<sup>\*1</sup>  
Jun MOHARA, MD<sup>\*1</sup>  
Yukinori MORIYAMA, MD<sup>\*1</sup>  
Yasuhiro TANAKA, MD, FJCC<sup>\*2</sup>  
Hirohito TSUBOUCHI, MD<sup>\*2</sup>

### Abstract

Arteriovenous shunt is one of the causes of heart failure, but heart failure caused by common iliac arteriovenous fistula is relatively rare. A 64-year-old man who developed acute heart failure due to venous perforation of a common iliac aneurysm and also had bilateral aneurysms (diameter 58 mm) was referred to our department. On admission, the patient complained of dyspnea and swollen left leg, so diuretic agent was administered to treat the heart failure. Cardiac catheterization showed a shunt rate of 80.6%, as well as 5.0 Qp/Qs and O<sub>2</sub> step-up across perforation of the common iliac vein. Despite the therapy, pleural effusion and ascites exacerbated, and the heart failure became difficult to control, so surgical treatment was performed. The aneurysm was replaced with an artificial vessel, and the fistula was closed by direct suturing. Postoperatively, the symptoms disappeared, and the patient is in good health.

*J Cardiol* 2007 Mar; 49(3): 143 - 147

### Key Words

■ Aneurysms (common iliac artery)

■ Aortic diseases

■ Heart failure

### INTRODUCTION

Arteriovenous shunt can affect the heart and vessels, and arteriovenous shunt is common at the common iliac level. Most cases are iatrogenic, sometimes as complications from intraabdominal surgery or puncture.<sup>1,2)</sup> Arteriovenous shunt is also one of the causes of heart failure, including rare

cases of common iliac arteriovenous fistula.<sup>3)</sup> Rupture of an aneurysm into a vein causes the symptoms associated with heart failure, but most aneurysms and arteriovenous fistulas are asymptomatic. Furthermore, edema may occur ipsilateral to the arteriovenous fistula.<sup>4)</sup> Vascular abnormalities that cause heart failure may be closely related to the general condition, so that thorough physical exami-

新杏病院 循環器科, <sup>\*1</sup>心臓血管外科: 〒890-0073 鹿児島県鹿児島市宇宿3-41-1; <sup>\*2</sup>鹿児島大学大学院医歯学総合研究科 人間環境学講座消化器疾患・生活習慣病学, 鹿児島

Divisions of Cardiology and <sup>\*1</sup>Cardiovascular Surgery, Shinkyō Hospital, Kagoshima; <sup>\*2</sup>Department of Digestive and Life-Style Related Diseases, Human Environmental Sciences, Health Research Studies, Kagoshima University Graduate School of Medical and Dental Sciences, Kagoshima

**Address for correspondence:** SATA N, MD, Division of Cardiology, Shinkyō Hospital, Usuki 3-41-1, Kagoshima, Kagoshima 890-0073; E-mail: sanoa@m.kufm.kagoshima-u.ac.jp

Manuscript received July 31, 2006; revised November 21 and 28, 2006; accepted December 1, 2006

nation, including auscultation, is particularly important.

The present patient had heart failure caused by an arteriovenous shunt associated with venous perforation of a right common iliac aneurysm with pain and swelling of the contralateral leg. Arteriovenous shunt of the leg is one of the causes of heart failure, so should be considered in the differential diagnosis of heart failure.

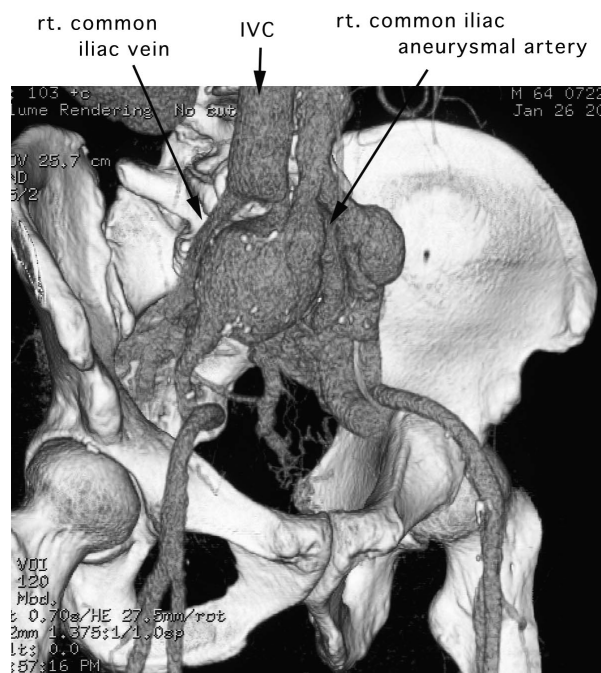
### CASE REPORT

A 64-year-old man had no disease requiring periodic hospital visits. Forty years earlier, he underwent surgery to remove kidney stones from the right urinary tract. He had no history of hypertension, hyperlipidemia or smoking.

The patient suddenly experienced pain and swelling of the left leg. The patient also complained of abdominal discomfort. Gastric endoscopic examination and abdominal ultrasonography revealed abdominal venous dilatation. Chest radiography revealed congestive heart failure, and computed tomography confirmed bilateral common iliac aneurysms and right common iliac arteriovenous fistula (Fig. 1). The patient was then referred to our department.

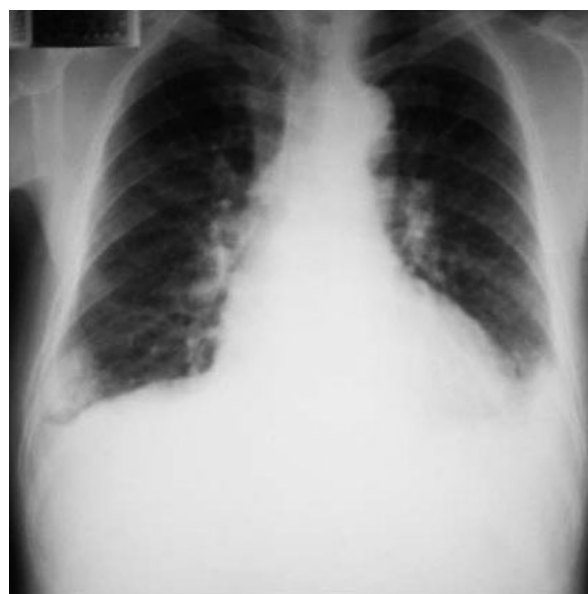On admission, the patient complained of dyspnea, and pain and swelling of the left leg. Blood pressure was 100/76 mmHg, and heart rate was 90/min, with normal sinus rhythm. A continuous murmur was also audible in the abdominal region. Chest radiography confirmed cardiac dilatation, pulmonary congestion and pleural effusion (Fig. 2). Electrocardiography confirmed normal sinus rhythm and complete right bundle branch block. Echocardiography showed normal left ventricular wall movement, mildly elevated pulmonary artery pressure, and markedly enlarged inferior vena cava. Diuretic therapy was initiated to treat congestive heart failure, and although the symptoms improved transiently, heart failure again exacerbated, despite increased dose of diuretic agents, and ascites was seen. Hence, the heart failure became difficult to control with drug therapy.

The results of cardiac catheterization and contrast-enhanced aortography were as follows: common iliac arteriovenous shunt rate was 80.6%, Qp/Qs was 5.0, and O<sub>2</sub> step-up was seen in the common iliac vein (Table 1). Shunt flows were confirmed at the right common iliac vein and right common iliac aneurysm (Fig. 3). Based on the



**Fig. 1** Abdominal three-dimensional computed tomography scan

rt. = right; IVC = inferior vena cava.



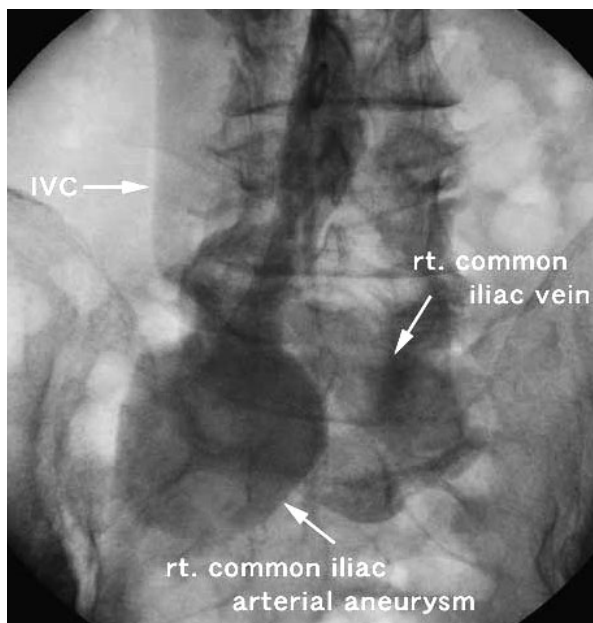
**Fig. 2** Chest radiograph

clinical course, the diagnosis was congestive heart failure. He then underwent Y-graft replacement and common iliac arteriovenous fistula ligation (Fig. 4). Postoperative right cardiac catheterization revealed marked improvements in pressure data

**Table 1 Echocardiographic findings and hemodynamics before and after operation**

	Echocardiography	
	Before operation	After operation
Left ventricular end-diastolic diameter( mm )	55	42
Left ventricular end-systolic diameter( mm )	36	28
Inferior vena cava( mm )	25	9
Pulmonary arterial pressure( mmHg )	54	20
Hemodynamics	Cardiac catheterization	
	Before operation	After operation
Pulmonary capillary wedge pressure( mp $\bar{x}$ mmHg )	22	4
Pulmonary arterial pressure( sp/dp/mp $\bar{x}$ mmHg )	60/30/40	22/6/12
Right ventricular pressure( sp/edp $\bar{x}$ mmHg )	60/25	22/4
Right atrial pressure( mp $\bar{x}$ mmHg )	22	3
	Qp/Qs = 5.07	
	L R shunt rate : 80.6%	

mp = mean pressure ; sp = systolic pressure ; dp = diastolic pressure ; edp = end-diastolic pressure ; Qp/Qs = ratio of blood flow before and after common iliac arteriovenous fistula.



**Fig. 3 Angiogram of the abdominal aorta( left anterior oblique view 45 °)**  
Abbreviations as in Fig. 1.

( **Table 1** ) Postoperative course was favorable, and the patient recovered without complications. At present( 3 months after surgery ), the patient has returned to work and is not taking any medication.

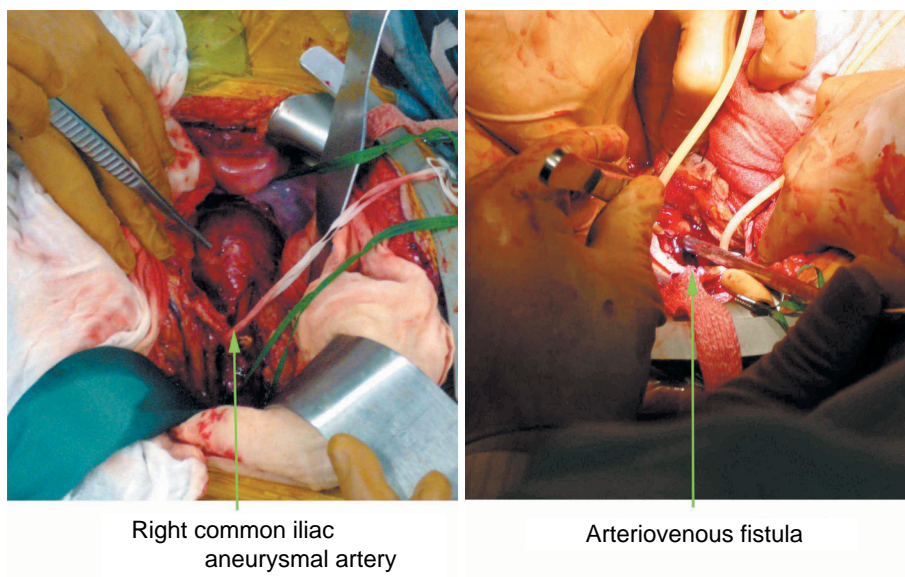
**DISCUSSION**

Arteriovenous shunt affects the heart, large ves-

sels and small vessels, and arteriovenous shunt at the common iliac level is not uncommon. Arteriovenous shunt can be caused by trauma or infection,<sup>5,6)</sup> but is often iatrogenic, and may occur as a complication of orthopedic surgery, urologic surgery or puncture.<sup>7-9)</sup> Several studies have reported venous perforation of aneurysms, and there have been 32 reported cases of common iliac arteriovenous fistula, including complications from heart failure.<sup>10)</sup>

The onset mechanism for venous perforation of aneurysms may involve localized degeneration and ulceration of the aortic wall due to arteriosclerosis or infection.<sup>11)</sup> Symptoms at the time of onset include dyspnea associated with heart failure and swelling of the leg ipsilateral to the arteriovenous fistula. The present patient had swelling of the leg contralateral to arteriovenous fistula, but the swelling disappeared postoperatively, so may have been caused by venous compression or perfusion disturbance due to the aneurysm. Even when an aneurysm grows in size, it is often asymptomatic, and leg swelling is an important diagnostic sign. Although the symptoms associated with heart failure were transiently alleviated by drip infusion of diuretic agents, the present patient gradually worsened, and when ascites was confirmed, heart failure could not be controlled with drug therapy.

The present patient had previously undergone surgery for kidney stones ipsilateral to the aneurysm, so persistent arteriovenous fistula due to



Right common iliac  
aneurysmal artery

Arteriovenous fistula

**Fig. 4 Intraoperative photographs**  
Arteriovenous fistula is  
10 mm in diameter.

surgical complications was suspected. However, the clinical course after onset of venous aneurysm perforation is rapid.<sup>12)</sup> In the present patient, left leg swelling appeared suddenly, and the symptoms exacerbated rapidly, thus suggesting acute-onset venous perforation.

At surgery, ulceration of the arterial wall around the perforation was confirmed. Hypotension may be associated with a rapid decrease in intraventricular

blood immediately after surgery,<sup>13)</sup> but in the present patient, hemodynamics were stable immediately after surgery, and as frequently found, the patient returned to a normal life without medication. Thus, arteriovenous shunt at the leg level can cause heart failure, and because the enlarged aneurysm and venous perforation are often asymptomatic, it is necessary to consider arteriovenous shunt as one of the causes of heart failure.

#### 要 約

##### 総腸骨動静脈瘤の静脈穿破によりうっ血性心不全をきたした1例

佐多 直幸 平峯 聖久 堀之内尚志 網谷 滋 宮原 健吉  
木村知恵里 茂原 淳 森山由紀則 田中 康博 坪内 博仁

心不全の原因として、動静脈シャント疾患があるが、総腸骨動静脈瘤による心不全の例は比較的まれである。今回我々は総腸骨動脈瘤の静脈穿破による急性心不全を経験したので報告する。症例は64歳、男性。心不全、右総腸骨動静脈瘤、両側動脈瘤(径58mm)を指摘され当科に紹介入院した。入院時、呼吸苦と左下腿腫脹を訴え、心不全に対して利尿薬治療を開始した。心臓カテーテル検査で総腸骨静脈の動脈瘤前後でのシャント率: 80.6%, Qp/Qs比: 5.0, 総腸骨静脈の穿通部前後でのO<sub>2</sub> step-upを認めた。治療を継続するも、胸腹水は増加し心不全コントロールが困難となったため、手術を施行した。動脈瘤は、人工血管で置換し、瘻孔を直接縫合閉鎖した。以後、症状は消失し経過良好である。

*J Cardiol* 2007 Mar; 49(3): 143 - 147

## References

- 1 ) Santos E, Peral V, Aroca M, Hernandez Lezana A, Serrano FJ, Vilacosta I, Gallego J: Arteriovenous fistula as a complication of lumbar disc surgery: Case report. *Neuroradiology* 1998; **40**: 459 - 461
- 2 ) Sy AO, Plantholt S: Congestive heart failure secondary to an arteriovenous fistula from cardiac catheterization and angioplasty. *Cathet Cardiovasc Diagn* 1991; **23**: 136 - 138
- 3 ) Weimann S, Flora G: Primary arteriovenous fistula between the common iliac vessels secondary to aneurysmal disease. *Surgery* 1987; **102**: 91 - 95
- 4 ) McAuley CE, Peitzman AB, deVries EJ, Silver MR, Steed DL, Webster MW: The syndrome of spontaneous iliac arteriovenous fistula: A distinct clinical and pathophysiologic entity. *Surgery* 1986; **99**: 373 - 377
- 5 ) Hartung O, Garcia S, Alimi YS, Juhan C: Extensive arterial aneurysm developing after surgical closure of long-standing post-traumatic popliteal arteriovenous fistula. *J Vasc Surg* 2004; **39**: 889 - 892
- 6 ) Sternbergh WC, Money SR: Iliac artery stent infection treated with superficial femoral vein. *J Vasc Surg* 2005; **41**: 348
- 7 ) Kwon TW, Sung KB, Cho YP, Kim DK, Ko GY, Yoon HK, Kim GE: Large vessel injury following operation for a herniated lumbar disc. *Ann Vasc Surg* 2003; **17**: 438 - 444
- 8 ) Zimmerman R, Sprayregen S: Arterio-venous shunting in renal transplant rejection. *Angiology* 1978; **29**: 40 - 47
- 9 ) McCann RL, Schwartz LB, Pieper KS: Vascular complications of cardiac catheterization. *J Vasc Surg* 1991; **14**: 375 - 381
- 10 ) Gregoric ID, Jacobs MJ, Reul GJ, Rochelle DG: Spontaneous common iliac arteriovenous fistula manifested by acute renal failure: A case report. *J Vasc Surg* 1991; **14**: 92 - 97
- 11 ) Shumacker HB Jr: Aneurysm development and degenerative changes in dilated artery proximal to arteriovenous fistula. *Surg Gynecol Obstet* 1970; **130**: 636 - 640
- 12 ) Nakano K, Oosawa M, Akiyama K, Kondoh Y: Abdominal arteriovenous fistula due to rupture of aorto-iliac aneurysm with multivarious clinical manifestations: Report of a case with successful repair. *Nippon Geka Gakkai Zasshi* 1986; **87**: 1583 - 1587 (in Jpn with Eng abstr)
- 13 ) Inoue K, Kitamura S, Oyama C, Kawachi K, Morita R, Nishii T, Kameda Y: A right common iliac aneurysm perforating into the inferior vena cava with resultant congestive heart failure. *Nippon Geka Gakkai Zasshi* 1989; **90**: 141 - 144 (in Jpn with Eng abstr)