

Volume Measurement of the Left Ventricle in Children Using Real-Time Three-Dimensional Echocardiography: Comparison With Ventriculography

Mayu IINO, MD
Hirohiko SHIRAIISHI, MD, FJCC
Kou ICHIHASHI, MD, FJCC
Masaru HOSHINA, MD
Mari SAITOH, MD
Yuka HIRAKUBO, MD
Yasuko MORIMOTO, MD
Mariko Y. MOMOI, MD

Abstract

Objectives. Recently, a real-time three-dimensional echocardiography (RT3DE) volume scanning technique was developed and used clinically. For precise ventricular volumetry, independent of mathematical assumptions, imaging techniques such as three-dimensional echocardiography are required in children with heart disease. This study evaluated whether RT3DE is suitable for left ventricular volumetry in children, and whether left ventricular volumes measured by RT3DE correlate sufficiently well with those measured by left ventriculography (LVG).

Methods. Twenty-five children with heart disease, 17 boys and 8 girls aged from 8 months to 18 years (mean age 5.9 ± 5.3 years), underwent cardiac catheterization at our institution. RT3DE was performed within 30 min after LVG using the Philips SONOS 7500 ultrasound system with an electronic sector probe consisting of a $\times 4$ matrix phased array transducer (center frequency of 2–4 MHz). Ultrasound images of the ventricle were calculated offline using TomTec 4D Cardio-View RT 1.2 software. Left ventricular volumes by LVG were calculated using Siemens Hicor T.O.P. Finally, the left ventricular volumes by RT3DE and LVG were compared.

Results. Left ventricular volumes measured by RT3DE correlated and agreed well with those measured by LVG ($r = 0.996$, $Y = 0.566 + 0.964 X$, mean difference -0.29 ± 1.90 ml; left ventricular end-systolic volume, $r = 0.979$, $Y = -0.187 + 0.897 X$, mean difference -6.76 ± 10.58 ml; left ventricular end-diastolic volume).

Conclusions. RT3DE is suitable for left ventricular volumetry in children. There was a good correlation between RT3DE and LVG, but the volume of left ventricular end-diastolic volume estimated by RT3DE was smaller than that by LVG.

J Cardiol 2007 May; 49(5): 221–229

Key Words

■ Echocardiography, transthoracic (three-dimensional) ■ Pediatric cardiology
■ Angiocardiography (ventriculography) ■ Cardiac volume (measurement)

自治医科大学 小児科: 〒329-0498 栃木県下野市薬師寺 3311-1

Department of Pediatrics, Jichi Medical University, Tochigi

Address for correspondence: IINO M, MD, Department of Pediatrics, Jichi Medical University, Yakushiji 3311-1, Shimotsuke, Tochigi 329-0498; E-mail: miino@jichi.ac.jp

Manuscript received January 5, 2007; revised February 8, 2007; accepted February 13, 2007

INTRODUCTION

Volume measurement of the left ventricle is necessary to evaluate cardiac function and is currently performed using two-dimensional echocardiography (2DE) or angiocardiology. Echocardiography is an inexpensive, noninvasive, portable, and easily repeatable modality for evaluating cardiac function in comparison with angiocardiology, although the 2D echocardiographic measurement of ventricular volume is limited by assumptions of ventricular geometry and image positioning. More accurate ventricular volume measurement using three-dimensional echocardiography (3DE) will mark a new step in pediatric cardiovascular diagnosis and treatment.¹⁻⁶⁾

Recently, a real-time three-dimensional echocardiography (RT3DE) volume scanning technique was developed and used clinically.⁷⁻¹⁴⁾ However, there are insufficient data with regard to the feasibility, accuracy and reproducibility of measuring left ventricular volumes using this system, and comparing and validating RT3DE measurements with other established modalities, such as left ventriculography (LVG) in children.¹⁵⁻²⁴⁾

This study evaluated whether RT3DE is suitable for left ventricular volumetry in children, and whether left ventricular volumes measured by RT3DE correlate sufficiently well with those measured by LVG.

SUBJECTS AND METHODS

Patient data

Twenty-five children with heart disease, 17 boys and 8 girls aged from 8 months to 18 years (mean age 5.9 ± 5.3 years), underwent cardiac catheterization at our institution. The indications for cardiac catheterization were pre- and post-operative assessment of cardiac anatomy and hemodynamics in patients with known congenital heart disease or assessment of coronary lesion in patients with Kawasaki disease, arteritis and chest pain (Table 1). Informed consent was obtained from the parents.

Real-time three-dimensional echocardiographic data

RT3DE was performed within 30 min after LVG. To confirm essentially unchanged hemodynamics, the scan immediately followed the cardiac catheter investigation, which was performed with patients in

Table 1 Patients investigated in this study

Heart disease	n=25
Patent ductus arteriosus	6
Ventricular septal defect	5
Atrial septal defect	5
Kawasaki disease	5
Tetralogy of Fallot post intracardiac repair	1
Cor triatrium	1
Takayasu arteritis	1
Chest pain	1

Twenty-five children (mean age 5.3 ± 5.9 years, 17 boys and 8 girls) with heart disease were prospectively enrolled.

the supine position. Depending on the location for ideal imaging quality, the transducer was positioned apically.

The ultrasonic diagnostic equipment used in this study was SONOS 7500 (Philips Medical Systems) with an electronic sector probe consisting of a $\times 4$ Matrix phased array transducer (center frequency of 2–4 MHz). The $\times 4$ Matrix phased array houses 3,000 elements and a conical volumetric data set can be acquired. The images were optimized using the biplane mode to visualize all left ventricular epicardial and endocardial contours. For a full volume image, a large conical 3D data set with a field of view of 90×90 degrees was acquired. The full volume data set was compiled from four 23×90 degree subvolumes with electrocardiography (ECG) triggering and the acquisition time was about 3–4 sec (4 beats) with the full cycle on mode. All data sets were saved onto a hard disk drive, and then downloaded to compact disks for offline analysis.^{10-14, 25, 26)}

Ultrasound images of the ventricle were calculated offline using 4D Cardio-View RT 1.2 software (TomTec Imaging Systems GmbH). The software includes the average rotation method which can set up a central shaft and trace the long-axis plane. The software can calculate from the upper to the lower plane areas by integral calculus, and the accuracy of this method is reported to be greater than that of Simpson's method using 2DE.¹¹⁾ This software can calculate ventricular volumes using two, four, eight, and sixteen cut planes. Images of the left ventricle were calculated using four and eight cut planes in this study. The 3D data set was displayed in a 4-tiled image screen. The two upper images were long-axis images, and the left lower image was a

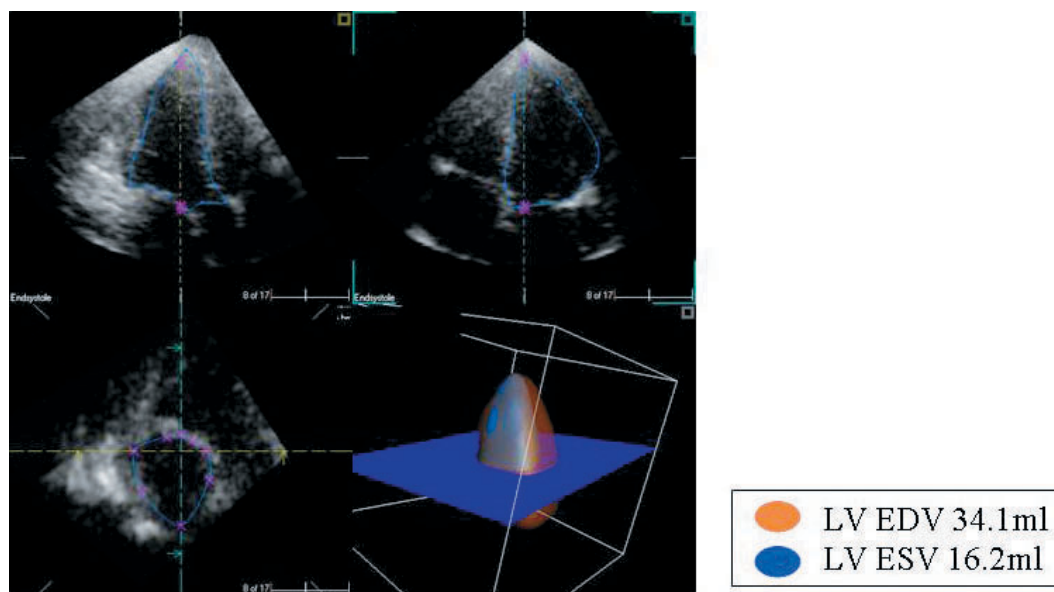


Fig. 1 Offline analysis of real-time three-dimensional echocardiography data

The data set is displayed in a 4-tiled image screen. The two *upper* images are long-axis images, and the *left lower* image is a short-axis image. Left ventricular endocardial borders were traced manually after fine tuning at end-systole and end-diastole. Four slices of the left ventricle along the long axis were obtained from a short-axis reference image at 45-degree increments around a 180-degree plane on four cut planes. The *right lower* images are left ventricular end-systolic (*blue*) and end-diastole (*orange*) volumes.

LVEDV = left ventricular end-diastolic volume; LVESV = left ventricular end-systolic volume.

short-axis image. Left ventricular endocardial borders were traced manually after fine-tuning at end-systole and end-diastole. Left ventricular volumes and ejection fraction were calculated using an interactive splice algorithm with software for the right lower image.²⁷⁾ Four slices of the left ventricle along the long axis were obtained from short-axis reference images at 45-degree increments around a 180-degree plane on four cut planes, and eight slices of the left ventricle along the long axis were obtained from short-axis reference images at 22.5-degree increments around a 180-degree plane on eight cut planes. Volumes of the left ventricle were calculated using an interactive splice algorithm with software (**Fig. 1**). The image at the QRS complex of the simultaneously registered ECG was selected as the end-diastolic condition and the first image after closure of the aortic valve was selected to represent the end-systolic state. The endocardial borders were traced manually on the end-diastolic and end-systolic images. The papillary muscles were included within the left ventricular cavity inseparable from the myocardium.

Angiocardiographic data

All younger children were investigated under deep sedation (thiopental sodium), whereas older patients, usually over the age of 10 years, received local anesthesia with lidocaine hydrochloride. For most patients, complete assessment of hemodynamics was undertaken, including pressure measurement and oxymetry. Left ventriculograms were registered simultaneously on right anterior oblique (30-degree) and left lateral oblique (60-degree) films. Contrast medium ranging from 1 to 1.5 ml / kg was selectively injected into the left ventricular within 2 sec using a Pigtail catheter (CX catheter; Cathex Limited) inserted into the femoral artery.

The image at the QRS complex of simultaneously registered ECG was selected as the end-diastolic condition and the first image after closure of the aortic valve was selected to represent the end-systolic state. On the end-diastolic and end-systolic images, the endocardial borders were traced manually on right anterior oblique films, and the data were fed into a computer program for analysis (**Fig. 2**).

Left ventricular volumes were calculated by the area-length's rule using Hicor T.P.O. (Siemens

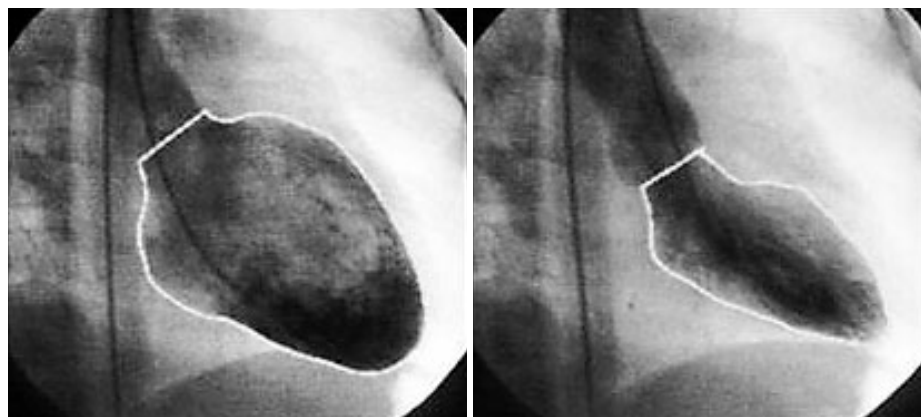


Fig. 2 Analysis of left ventriculography data on right anterior oblique films

The *left side* shows a left ventricular end-diastolic image and the *right side* shows an end-systolic image. Left ventricular endocardial borders were traced manually to calculate left ventricular volumes and ejection fraction. Left ventricular ejection fraction = 64%. Stroke volume = 24.7 ml. Left ventricular end-diastolic volume = 38.6 ml. Left ventricular end-systolic volume = 13.9 ml.

AG). The longitudinal ventricular axis was defined between the middle of the aortic valve and the ventricular apex. The papillary muscles were included within the left ventricular cavity inseparable from the myocardium.

Statistical analysis

Measurements of left ventricular end-systolic volume (LVESV), left ventricular end-diastolic volume (LVEDV), and left ventricular ejection fraction (LVEF) by RT3DE were analyzed using left ventriculographic measurements as the reference standard. To examine the correlation and agreement between the two sets of measurement, linear regression analysis and the Bland-Altman method were used.^{28, 29)}

Inter- and intraobserver variability

To test the variability in ventricular volume calculations using RT3DE, the first observer (M.I.) and the second observer (H.S.), who were both unaware of previous results, repeated randomly selected RT3DE calculations. Variability was expressed as the difference of the mean of the two results, as a percentage of the mean.

RESULTS

Data for RT3DE and LVG were acquired successfully for analysis. Measurements of LVESV using RT3DE correlated and agreed well with LVG, but LVEDV measurements using RT3DE were

smaller than those of LVG.

Figs. 3–7 show linear regression analysis and the Bland-Altman method of LVESV, LVEDV, LVEF using RT3DE and LVG measurements. There was good correlation and agreement in the measurement of LVESV ($Y = 0.566 + 0.964 X$, $r = 0.996$, mean difference -0.29 ± 1.90 ml; four cut planes, $Y = 0.618 + 0.983 X$, $r = 0.995$, mean difference 0.22 ± 1.95 ml; eight cut planes) between RT3DE and LVG (**Figs. 3, 4**). There was also good correlation in LVEDV ($Y = -0.187 + 0.897 X$, $r = 0.979$; four cut planes, $Y = -0.631 + 0.926 X$, $r = 0.982$; eight cut planes). However, there was underestimation of the LVEDV (mean difference -6.76 ± 10.58 ml; four cut planes, -5.34 ± 9.64 ml; eight cut planes) between RT3DE and LVG (**Figs. 5, 6**). There was loose correlation in LVEF ($Y = 17.552 + 0.66 X$, $r = 0.686$, mean difference $-3.26 \pm 4.22\%$; four cut planes, $Y = 20.779 + 0.612 X$, $r = 0.627$, $-3.19 \pm 4.62\%$; eight cut planes) (**Fig. 7**) using RT3DE compared with LVG measurements.

Interobserver variability of RT3DE measurements was: 14% for LVESV; 8% for LVEDV; and 3% for LVEF on four cut planes, 16% for LVESV; 9% for LVEDV; and 12% for LVEF on eight cut planes. Intraobserver variability of RT3DE measurements was: 7% for LVESV; 3% for LVEDV; and 6% for LVEF on four cut planes, 6% for LVESV; 2% for LVEDV; and 7% for LVEF on eight cut planes.

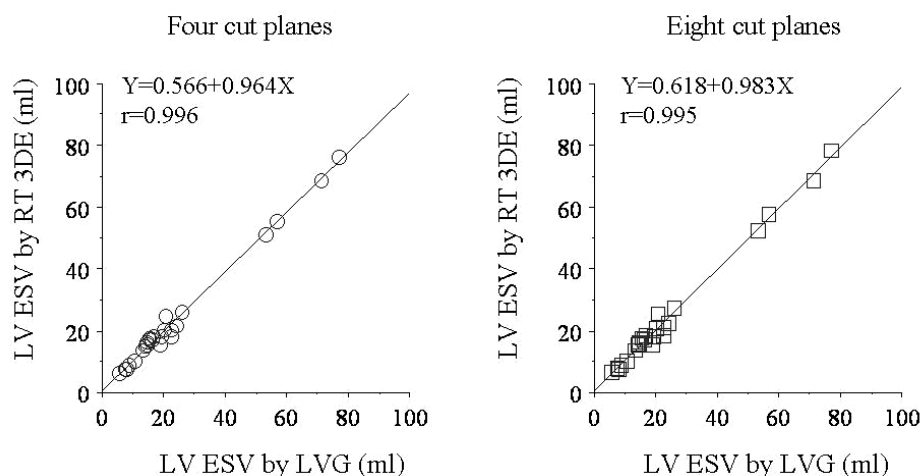


Fig. 3 Linear regression analysis of left ventricular end-systolic volumes by left ventriculography and real-time three-dimensional echocardiography
 RT3DE = real-time three-dimensional echocardiography; LVG = left ventriculography. Other abbreviation as in Fig. 1.

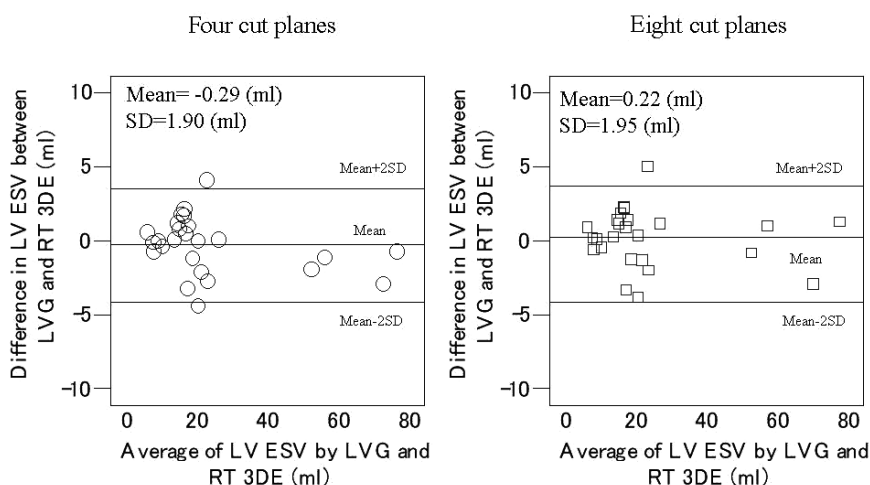


Fig. 4 Bland-Altman method of left ventricular end-systolic volumes by left ventriculography and real-time three-dimensional echocardiography
 Abbreviations as in Figs. 1, 3.

DISCUSSION

This study demonstrated that RT3DE measurements of left ventricular volumes in children with heart disease using a full-volume acquisition strategy are accurate and comparable with angiographic measurements. RT3DE can provide accurate volume measurement of the left ventricle in children. Linear regression analysis and the Bland-Altman method showed good correlation and agreement using RT3DE compared with LVG.

3DE is not dependent on left ventricular geome-

try and is superior to 2DE for measurements of left ventricular indexes.¹⁻⁶⁾ Conventional 2D echocardiographic measurement of ventricular volume is limited by assumptions of ventricular geometry and image positioning, and is reported to underestimate left ventricular volume.⁸⁾ There are many clinical conditions in children with congenital heart diseases in which left ventricular geometry is altered significantly, which leads to erroneous measurements of left ventricular indexes by M-mode and 2DE methods. The software used in our study has an average rotation method that can set a central

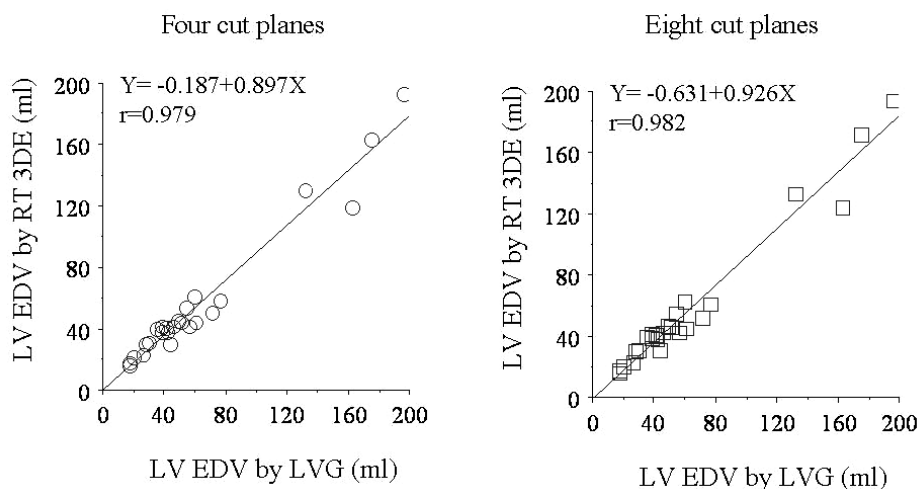


Fig. 5 Linear regression analysis of left ventricular end-diastolic volumes by left ventriculography and real-time three-dimensional echocardiography
Abbreviations as in Figs. 1, 3.

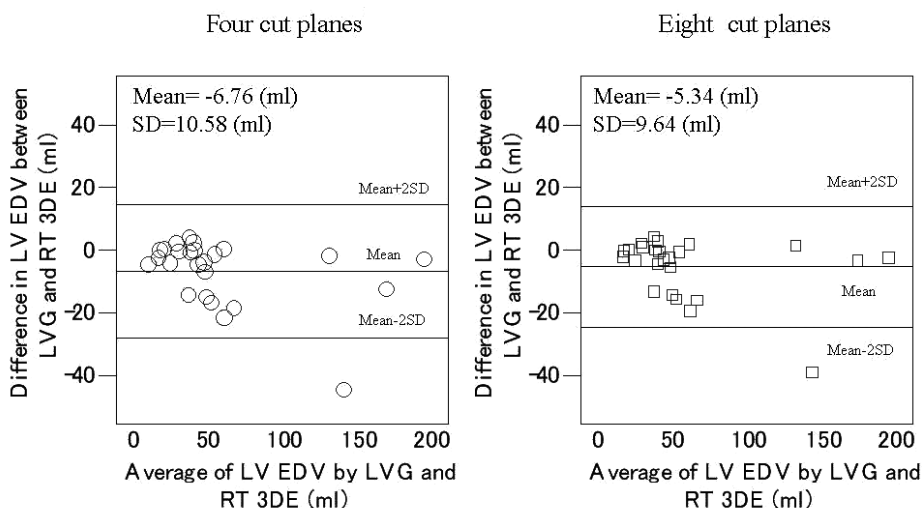


Fig. 6 Bland-Altman method of left ventricular end-diastolic volumes by left ventriculography and real-time three-dimensional echocardiography
Abbreviations as in Figs. 1, 3.

shaft and can trace the long-axis plane, and then calculate upper from lower plane areas using integral calculus. The accuracy of this method is reported to be greater than that of Simpson's method with 2DE.¹⁰⁻¹⁴ Quantitative RT3DE has been applied for left ventricular volumes and functions in humans, animals and phantom models of adults.^{6,7,9,10,30} We studied the volume measurement of a pediatric ventricular model using 3DE. Experimental studies demonstrated that calculation by manual tracing of the interior surface is the best method for accurate volume measurement.^{25,26}

Accordingly, the endocardial borders were traced manually for accurate left ventricular volume measurement.

Previous studies assessed left ventricular indexes using RT3DE compared with quantitative gated single-photon emission computed tomography (QGSPECT) in adults.^{6,10} RT3DE correlated well with QGSPECT in the measurement of LVEDV and LVESV ($r = 0.97$, mean difference 3.4 ml for LVEDV, $r = 0.98$, mean difference 2 ml for LVESV), and LVEF obtained by RT3DE had good agreement with that obtained by QGSPECT ($r =$

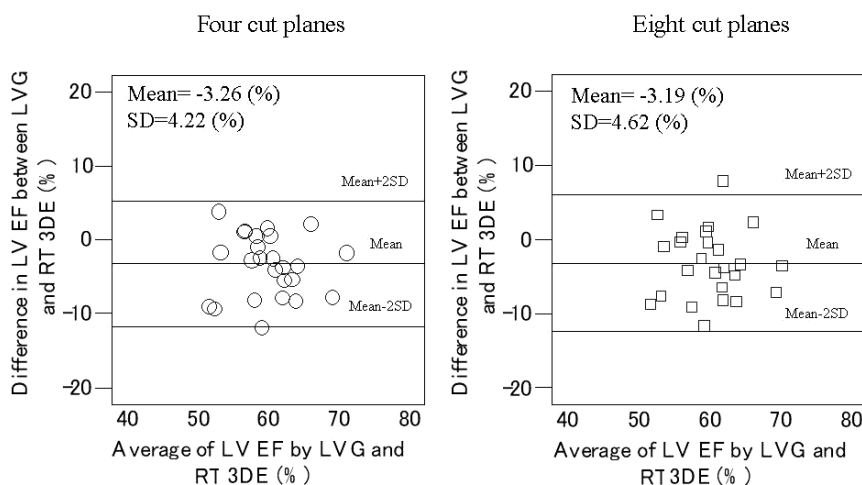


Fig. 7 Bland-Altman method of left ventricular ejection fraction by left ventriculography and real-time three-dimensional echocardiography

LVEF = left ventricular ejection fraction. Other abbreviations as in Figs. 1, 3.

0.92, mean difference -0.2%) in patients with wall motion abnormality.¹⁰ However, the measurement of left ventricular indexes using QGSPECT is not currently used in children. Therefore, QGSPECT could not be used as the reference standard for the measurement of left ventricular volume in our study.

In our study, children aged 8 months to 18 years were investigated. In previous comparative studies using magnetic resonance imaging (MRI), patients needed to be kept quiet and to achieve prolonged breath holding during MRI.^{7,9,13,14,30} Infants who are not cooperative and cannot hold their breath may need sedation and possibly endotracheal intubation during MRI, and patients with a cardiac pacemaker are contraindicated for MRI. Therefore, MRI cannot be used as the first-line modality for the assessment of left ventricular volume in children, and could not be used as the reference standard for the measurement of left ventricular volume in our study. Measurements of LVESV, LVEDV, mass, stroke volume and LVEF by RT3DE correlated well ($r = 0.86-0.97$, $p < 0.001$) and agreed well with MRI in children.¹⁴ However, only children aged 6 to 18 years were enrolled in that study. In our study, RT3DE was applied in much younger children.

The measurement of left ventricular volume using angiocardiology is the standard method, especially in children with congenital heart disease.¹⁶ Therefore, we compared left ventricular volumes using RT3DE with those measured using

angiocardiology, the reference standard, to determine its feasibility, accuracy, and reproducibility. Volume measurement of the left ventricle (10–80 ml) by RT3DE was correlated with LVG in an animal study.⁹ We measured a wide range of pediatric hearts in children aged 8 months to 18 years. Our study estimated volume measurements of small to moderate left ventricular volumes (5–200 ml), and demonstrated that RT3DE is feasible, accurate and reproducible to measure left ventricular volumes in children.

In our study, there was good correlation and agreement between the measurements of LVESV using RT3DE and LVG. However, measurements of LVEDV using RT3DE were smaller than LVG. Previous studies demonstrated a tendency to underestimate left ventricular volumes by 3DE compared with MRI or angiocardiology.^{12,14} There are various reasons for the underestimation of LVEDV using RT3DE in our study. First, the patient's respiratory movement was difficult to control to acquire RT3DE images just after LVG. Second, the transducer was positioned in only an apical acoustic window. Technically, to acquire an RT3DE data set, the whole left ventricular cavity could not always be placed within the image angle. This may also contribute to the underestimation of LVEDV by RT3DE in our study.

There are several limitations in this study. First, it was performed under anesthesia for catheterization under static conditions. When we measure ventricular volume in daily examination, we must con-

sider the effect of patient movement. Second, the only available RT3DE transducer had an operating frequency of 2–4 MHz. To acquire images with superior quality and to measure more accurately, harmonic imaging or intracardiac contrast injection may enhance endocardial border delineation. Third, current ECG triggering is necessary for a full volume data set from four subvolumes that may potentially cause data discontinuity between the four individual data sets due to breathing, patient movement, or arrhythmia. Finally, the software in our study

required manual tracing of the endocardial boundaries. The introduction of automated border detection, if accurate, would make this technique even more attractive in the future.

CONCLUSIONS

RT3DE is feasible for volumetry of the left ventricle in most children. There was good correlation between RT3DE and LVG. The volumes of LVEDV measured by RT3DE may be smaller than those measured by LVG.

要 約

リアルタイム3D心エコー図法による小児の左室容積計測: 左室造影法との比較

飯野 眞由 白石裕比湖 市橋 光 保科 優
齋藤 真理 平久保由香 森本 康子 桃井真里子

目 的: 近年, リアルタイム3D心エコー図法による心腔容積計測が臨床応用されるようになってきた。3D心エコー図法を用いて心室形態に依存しない正確な心腔容積計測ができれば, とくにさまざまな心室形態を有する心疾患児において極めて有用となる。そこで3D心エコー図法による左室容積計測が小児において臨床応用可能か否かを明らかにする目的で, 3D心エコー図法と心臓カテーテル検査・左室造影法による測定値が一致するか否かを検討した。

方 法: 対象は, 当院小児科に心臓カテーテル検査目的で入院した8ヵ月から18歳までの25例(平均年齢 5.9 ± 5.3 歳, 男17例, 女8例)である。心臓カテーテル検査・左室造影後30分以内に3D心エコー図検査を実施し画像を記録した。超音波装置はPhilips製SONOS7500で2–4MHzの電子セクタプローブを使用した。記録した3D画像からTomTec製4D Cardio-View RT1.2解析ソフトを用いて左室容積を計測した。左室造影法による左室容積はSiemens製Hicor T.O.Pを用いて計測した。3D心エコー図法で計測した左室容積を左室造影法と比較した。

結 果: 3D心エコー図法で計測した左室容積は, 左室造影法で求めた左室容積と相関性が高く, とくに収縮末期でよく一致した(左室収縮末期容積: $Y = 0.566 + 0.964 X$, 相関係数 $r = 0.996$, 誤差 -0.29 ± 1.90 ml, 左室拡張末期容積: $Y = -0.187 + 0.897 X$, 相関係数 $r = 0.979$, 誤差 -6.76 ± 10.58 ml)。

結 論: 3D心エコー図法による左室容積計測は, 心臓カテーテル検査・左室造影法との相関性が高く, 小児において有用な検査法であるが, 拡張末期容積については心エコー図法による計測値は左室造影法に比べ小さかった。

J Cardiol 2007 May; 49(5): 221–229

References

- 1) Siu SC, Rivera JM, Guerrero JL, Handschumacher MD, Lethor JP, Weyman AE, Levine RA, Picard MH: Three-dimensional echocardiography: In vivo validation for left ventricular volume and function. *Circulation* 1993; **88**: 1715–1723
- 2) Sapin PM, Schroder KM, Gopal AS, Smith MD, DeMaria AN, King DL: Comparison of two- and three-dimensional echocardiography with cineventriculography for measurement of left ventricular volume in patients. *J Am Coll Cardiol* 1994; **24**: 1054–1063
- 3) Siu SC, Levine RA, Rivera JM, Xie SW, Lethor JP, Handschumacher MD, Weyman AE, Picard MH: Three-dimensional echocardiography improves noninvasive assessment of left ventricular volume and performance. *Am Heart J* 1995; **130**: 812–822
- 4) Abdullah M, Maeno Y, Bigras JL, McCrindle BW, Smallhorn JF, Boutin C: Superiority of 3-dimensional versus 2-dimensional echocardiography for left ventricular volume assessment in small piglet hearts. *J Am Soc Echocardiogr* 2000; **13**: 918–923
- 5) Hubka M, Bolson EL, McDonald JA, Martin RW, Munt B, Sheehan FH: Three-dimensional echocardiographic mea-

- surement of left and right ventricular mass and volume: In vitro validation. *Int J Cardiovasc Imaging* 2002; **18**: 111–118
- 6) Fukuda S, Hozumi T, Watanabe H, Muro T, Yamagishi H, Yoshiyama M, Takeuchi K, Yoshikawa J: Freehand three-dimensional echocardiography with rotational scanning for measurements of left ventricular volume and ejection fraction in patients with coronary artery disease. *Echocardiography* 2005; **22**: 111–119
 - 7) Schmidt MA, Ohazama CJ, Agyeman KO, Freidlin RZ, Jones M, Laurienzo JM, Brennenman CL, Arai AE, von Ramm OT, Panza JA: Real-time three-dimensional echocardiography for measurement of left ventricular volumes. *Am J Cardiol* 1999; **84**: 1434–1439
 - 8) Qin JX, Jones M, Shiota T, Greenberg NL, Tsujino H, Firstenberg MS, Gupta PC, Zetts AD, Xu Y, Ping Sun J, Cardon LA, Odabashian JA, Flamm SD, White RD, Panza JA, Thomas JD: Validation of real-time three-dimensional echocardiography for quantifying left ventricular volumes in the presence of a left ventricular aneurysm: In vitro and in vivo studies. *J Am Coll Cardiol* 2000; **36**: 900–907
 - 9) Ota T, Kisslo J, von Ramm OT, Yoshikawa J: Real-time, volumetric echocardiography: Usefulness of volumetric scanning for the assessment of cardiac volume and function. *J Cardiol* 2001; **37**(Suppl I): 93–101
 - 10) Arai K, Hozumi T, Matsumura Y, Sugioka K, Takemoto Y, Yamagishi H, Yoshiyama M, Kasanuki H, Yoshikawa J: Accuracy of measurement of left ventricular volume and ejection fraction by new real-time three-dimensional echocardiography in patients with wall motion abnormalities secondary to myocardial infarction. *Am J Cardiol* 2004; **94**: 552–558
 - 11) Arai K, Hozumi T, Matsumura Y, Oe H, Sugioka K, Ujino K, Takemoto Y, Muro T, Yamagishi H, Akioka K, Yoshiyama M, Takeuchi K, Yoshikawa J: Feasible and accurate measurement of left ventricular volume and ejection fraction by new real-time three-dimensional echocardiography. *Circulation J* 2004; **68**(Suppl I): 485(abstr)
 - 12) Fleming SM, Cumberledge B, Kiesewetter C, Parry G, Kenny A: Usefulness of real-time three-dimensional echocardiography for reliable measurement of cardiac output in patients with ischemic or idiopathic dilated cardiomyopathy. *Am J Cardiol* 2005; **95**: 308–310
 - 13) Corsi C, Lang RM, Veronesi F, Weinert L, Caiani EG, MacEneaney P, Lamberti C, Mor-Avi V: Volumetric quantification of global and regional left ventricular function from real-time three-dimensional echocardiographic images. *Circulation* 2005; **112**: 1161–1170
 - 14) Bu L, Munns S, Zhang H, Disterhoft M, Dixon M, Stolpen A, Sonka M, Scholz TD, Mahoney LT, Ge S: Rapid full volume data acquisition by real time 3-dimensional echocardiography for assessment of left ventricular indexes in children: A validation study compared with magnetic resonance imaging. *J Am Soc Echocardiogr* 2005; **18**: 299–305
 - 15) Heusch A, Koch JA, Krogmann ON, Korbmacher B, Bourgeois M: Volumetric analysis of the right and left ventricle in a porcine heart model: Comparison of three-dimensional echocardiography, magnetic resonance imaging and angiocardiography. *Eur J Ultrasound* 1999; **9**: 245–255
 - 16) Heusch A, Rubo J, Krogmann ON, Bonig H, Bourgeois M: Volume measurement of the left ventricle in children with congenital heart defects: 3-dimensional echocardiography versus angiocardiography. *Cardiology* 1999; **92**: 45–52
 - 17) Acar P, Marx GR, Saliba Z, Sidi D, Kachaner J: Three-dimensional echocardiographic measurement of left ventricular stroke volume in children: Comparison with Doppler method. *Pediatr Cardiol* 2001; **22**: 116–120
 - 18) Meyer-Wittkopf M, Cole A, Cooper SG, Schmidt S, Sholler GF: Three-dimensional quantitative echocardiographic assessment of ventricular volume in healthy human fetuses and in fetuses with congenital heart disease. *J Ultrasound Med* 2001; **20**: 317–327
 - 19) Wong PC, Gao H, Sklansky M: Real time volume-rendered transthoracic three-dimensional echocardiography for the evaluation of pediatric heart disease. *Circulation* 2003; **108**(Suppl IV): 677(abstr)
 - 20) Bhat AH, Li X, Sahn DJ: Clinical experience and validation studies of a non-gated multi-frequency fetal/obstetric three-dimensional system for determining fetal cardiac mass. *Circulation* 2003; **108**(Suppl IV): 677(abstr)
 - 21) Esh-Broder E, Ushakov FB, Imbar T, Yagel S: Application of free-hand three-dimensional echocardiography in the evaluation of fetal cardiac ejection fraction: A preliminary study. *Ultrasound Obstet Gynecol* 2004; **23**: 546–551
 - 22) Bhat AH, Corbett V, Carpenter N, Liu N, Liu R, Wu A, Hopkins G, Sohaey R, Winkler C, Sahn CS, Sovinsky V, Li X, Sahn DJ: Fetal ventricular mass determination on three-dimensional echocardiography: Studies in normal fetuses and validation experiments. *Circulation* 2004; **110**: 1054–1060
 - 23) Acar P: Three-dimensional echocardiography in congenital heart disease. *Arch Pediatr* 2006; **13**: 51–56 (in French with Eng abstr)
 - 24) Hata T, Kanenishi K, Tanaka H, Kimura K: Real-time 3-D echocardiographic evaluation of the fetal heart using instantaneous volume-rendered display. *J Obstet Gynaecol Res* 2006; **32**: 42–46
 - 25) Ino M, Shiraishi H, Ichihashi K, Hoshina M, Momoi MY: Volume measurement of small ventricular model by real-time three-dimensional echocardiography. *Ped Cardiol Card Surg* 2006; **22**: 3–6
 - 26) Ino M, Shiraishi H, Ichihashi K, Hoshina M, Momoi MY: Volume measurement of a pediatric ventricular phantom model using three-dimensional echocardiography. *J Med Ultrasonics* 2006; **33**: 197–201
 - 27) Kawai J, Yoshida K, Hozumi T, Ookawa M, Akasaka T, Tanabe K, Takagi T, Yamamuro A, Yagi T, Morioka S, Yoshikawa J: Three-dimensional transesophageal echocardiographic measurement of left ventricular volumes using the average rotation method: Comparison with the disk summation method. *J Cardiol* 2001; **38**: 153–161 (in Jpn with Eng abstr)
 - 28) Bland JM, Altman DG: Statistical methods for assessing agreement between two methods of clinical measurement. *Lancet* 1986; **I**: 307–310
 - 29) Stanton AG: Comparing two different measurements of the same thing. *in* *Primer of Biostatistics*, 6th Ed. McGraw Hill, New York, 2002; pp 305–310
 - 30) Krenning BJ, Voormolen MM, Roelandt JR: Assessment of left ventricular function by three-dimensional echocardiography. *Cardiovasc Ultrasound* 2003; **1**: 12