

Role of a Novel Conduction Pattern Around the Coronary Sinus in Cavotricuspid Isthmus Dependent Right Atrial Flutter

Yoshio YAMAGUCHI, MD

Hiroichi TSUGAWA, MD

Nakaba FUJIOKA, MD

Kenichi KASENO, MD

Michihiko KITAYAMA, MD

Kouji KAJINAMI, MD, FJCC

Abstract

Objectives. We tested our hypothesis that, in atrial flutter (AFL) dependent on the cavotricuspid isthmus (CTI), lower loop reentry is the common pathway route at the coronary sinus posterior site, and thus, dual loop reentry is a common circular pattern.

Methods and Results. We studied 25 patients with CTI-dependent AFL, 16 with chronic counterclockwise atrial flutter (CCW-AFL) and 9 with clockwise atrial flutter (CW-AFL) and determined the precise reentry circuitry, especially for conduction patterns around the coronary sinus orifice, using electroanatomical mapping. We measured post pacing interval and tachycardia cycle length during entrainment from sites within the flutter circuit. The coronary sinus anterior pacing site was within the AFL circuit in 16 of the 25 CCW-AFL patients, and in 6 of the 9 CW-AFL patients. Both the coronary sinus anterior and posterior sites were within the AFL circuit in 8 of 16 CCW-AFL and 8 of the 9 CW-AFL patients. Results of 3-dimensional activation mapping suggest that all of these patients have a dual loop reentry circuit, and that coronary sinus posterior conduction broke through the eustachian valve/ridge.

Conclusions. Coronary sinus posterior conduction consisted of the flutter circuit and appeared to be critical for maintaining AFL.

J Cardiol 2007 Jul; 50(1): 1-10

Key Words

■ Atrial flutter

■ Electrophysiology

■ Reentry

INTRODUCTION

Atrial flutter (AFL), most often defined as macroreentrant tachycardia, is maintained by the circular movement of the activation wave front around the tricuspid annulus.^{1,2)} Dual loop reentry (DLR) uses the cavotricuspid isthmus (CTI) and completes two broad competing loops with a common pathway in about 50% of cases of typical right atrial (RA) counterclockwise flutter (CCW-AFL).³⁾

In this pathway, the anterior loop is around the tricuspid annulus and the posterior loop is around the inferior vena cava (IVC) or the posterior block line. This finding suggests that AFL is treatable by linear ablation of the CTI.

A recent anatomical study⁴⁾ showed that the eustachian valve/ridge (EVR) had a muscular layer running from the RA septal wall to the CTI, the EVR was not fused to the thebesian valve, and a small flat area remained between the EVR and the

金沢医科大学 循環器内科: 〒920-0293 石川県河北郡内灘町大学1-1

Department of Cardiology, Kanazawa Medical University School of Medicine, Ishikawa

Address for correspondence: YAMAGUCHI Y, MD, Department of Cardiology, Kanazawa Medical University School of Medicine, Daigaku 1-1, Uchinada-machi, Kahoku-gun, Ishikawa 920-0293; E-mail: yoshio-y@kanazawa-med.ac.jp

Manuscript received February 20, 2007; revised March 24, 2007; accepted March 30, 2007

coronary sinus (CS) orifice in 44% of necropsied normal human hearts ($n = 80$). Therefore, most cases of RA clockwise flutter (CW-AFL) are supported by a reentrant circuit around the IVC or a figure-of-eight DLR involving both the IVC and tricuspid annulus.^{3,5-8} Although DLR may circle both the IVC and tricuspid annulus, the potential role of conduction around the CS orifice in maintaining AFL remains unclear.

Based on these considerations, we hypothesized that lower loop reentry was the common pathway route at the CS posterior site in CTI-dependent AFL,^{5,7} so that DLR had a common circular pattern. To test this hypothesis, we studied patients with CTI-dependent AFL, and investigated the precise reentry circuitry, especially for conduction patterns around the CS orifice, using high-density 3-dimensional (3D) mapping.⁹

SUBJECTS AND METHODS

Study population

The subjects were 25 patients who underwent mapping and ablation of CTI-dependent chronic CCW-AFL ($n = 16$) and CW-AFL ($n = 9$). All patients had suffered from tachyarrhythmic events for 33.5 ± 55.7 months (mean \pm SD, range 3 to 180), had a history of more than one hospitalization, and were unresponsive to a mean 2.4 ± 1.2 antiarrhythmic drugs (range 1 to 4). To ensure visualization of F-waves, inverted F-waves were documented for leads II, III, and a V_F in 16 patients with CCW-AFL, and positive or isoelectric F-waves were observed in inferior leads in another 9 patients with CW-AFL. All antiarrhythmic medications were discontinued for at least 5 half-lives before the procedure. All patients gave written informed consent and the research protocol was approved by the ethics committee of Kanazawa Medical University.

Electrophysiological study

In all patients, venous accesses were obtained with 7F and 8F sheaths in the right internal jugular vein and femoral veins. A 20-pole catheter (Halo XP20, Biosense-Webster Inc.) was placed counterclockwise along the tricuspid annulus with the distal tip at the lateral entrance point to the isthmus between the CTI and IVC and the proximal electrode at the high interatrial septum. A 10-pole catheter was positioned in the CS (Response CSL, St. Jude Medical Inc.) with electrode spacing 2-8-

2 mm; and a built-in 0.025 inch lumen with the proximal, bipolar electrode positioned 1 cm distal to the CS orifice as determined in the left anterior oblique (LAO) projection. A quadripolar catheter was positioned to record His bundle electrocardiography. Atrial activation was also recorded at the anterior septum and CS. The 12-lead surface electrocardiography and intracardiac signals were recorded, and programmed stimulation was delivered through a programmable stimulator (EP WorkMate, EP MedSystems Inc.).

Activation and voltage mapping were performed in 16 of the 25 patients with 3D electroanatomical mapping (Biosense-Webster Inc.). RA mapping points totaled 194 ± 56 (range 138 to 254 points). A 7F navi-star catheter (4-mm tip, 2 bipolar electrode pairs, interelectrode distance 2 mm; Biosense-Webster Inc.) was used as the mapping/ablation catheter. The catheter was dragged over the endocardial surface to record electrograms at different sites. Complete RA endocardial maps were obtained for all patients to ensure reconstruction of a detailed activation 3D map.⁷⁻⁹ This catheter was also used for entrainment pacing at the RA.^{7,10,11} Intracardiac signals were filtered with low and high cutoff frequencies of 30 and 500 Hz, with a sampling frequency of $\sim 1,000$ Hz.

The cycle length of the AFL was measured as the tachycardia cycle length (TCL) and entrainment was done at pacing cycle lengths 10, 20, and 30 msec shorter than the TCL.^{5,10} Pacing was done at twice the local capture threshold determined during pacing at a faster rate than the TCL. Entrainment pacing used overdrive pacing at multiple atrial sites in all patients (Fig. 1). The postpacing interval (PPI) was defined as the time interval from the last pacing artifact to the first local electrogram recorded at the pacing site.^{3,5,10} The pacing site was considered to be within the reentrant circuit when the difference between the PPI and the TCL was within 30 msec.^{5,6}

Anatomical findings

An angiography series of the coronary artery, RA, and CS was obtained for all patients. The CTI was localized at roughly the 6 o'clock position in the LAO projection. The EVR was attached medially to the orifice of the IVC along the CS orifice. This site was at 4:00 to 6:30 in the LAO projection. The CS orifice was located at the junction of the great cardiac vein and the origin of the CS, the

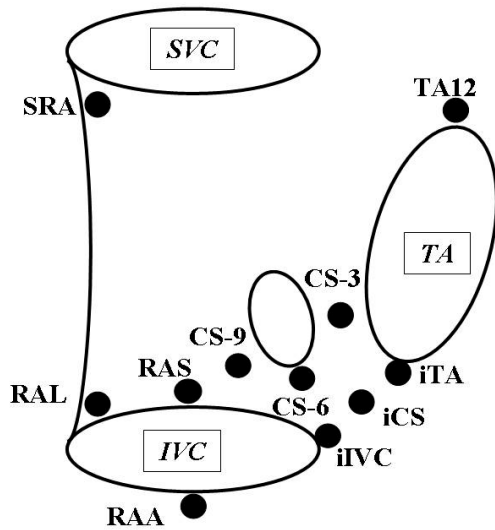


Fig. 1 Entrainment pace mapping points

CS-3 = coronary sinus (CS) orifice at 3:00 in the right anterior oblique projection; CS-6 = coronary sinus orifice at 6:00 in the right anterior oblique projection; CS-9 = coronary sinus orifice at 9:00 in the right anterior oblique projection; iTA = cavotricuspid isthmus (CTI) near the tricuspid annulus; iCS = cavotricuspid isthmus near the coronary sinus orifice; iIVC = cavotricuspid isthmus near the inferior vena cava; RAS = right atrium (RA) lower septal site; RAL = right atrium lower lateral site; RAA = right atrium lower anterior site; SRA = superior right atrium; TA12 = superior tricuspid annulus; IVC = inferior vena cava; SVC = superior vena cava; TA = tricuspid annulus.

thebesian valve, and the EVR. The site was at 4:00 to 5:00 in the right anterior oblique (RAO) projection. The CS-3 was at 3:00 for the CS orifice in the RAO projection (Fig. 1). The CS-9 was at 9:00 for the CS orifice in the RAO projection. The anatomical structure and catheter positioning were reinforced by 3D electroanatomical mapping information and biplane mobile fluoroscopy.

Coronary sinus pacing site

The pacing catheter was placed into the CS and pulled outside the CS orifice. The CS-3 pacing site was positioned between CS-3 and tricuspid annulus, and similarly, the CS-9 pacing site was located between CS-9 and IVC close to the EVR (Fig. 1).

Statistical analysis

All continuous variables are expressed as mean \pm SD. Statistical comparisons within the group were made using a paired *t*-test. $p < 0.05$ was considered statistically significant.

RESULTS

Patient profiles

The baseline characteristics of the study group of 25 patients were not significantly different (sex, age, underlying heart disease, used antiarrhythmic drugs, cardiothoracic ratio, flutter cycle length), excluding the conduction pattern around the coronary sinus (Tables 1, 2).

Fifteen of the 25 subjects had structurally normal hearts, of whom 6 had coronary artery disease, and 4 cardiomyopathy. All patients who underwent entrainment pacing and radiofrequency energy were determined to have AFL originating from the CTI, so ablation was successful in all patients.^{1,2,12)}

PPI-TCL for coronary sinus orifice

During entrainment from sites (Fig. 1) within the flutter circuit, the mean PPI-TCL interval was ≤ 30 msec for all pacing rates regardless of the AFL direction. The CS orifice pacing site was within the AFL circuit in all patients (Fig. 2). The CS-3 was within the AFL circuit in 19 of 25 patients (76%: mean PPI-TCL = 16.2 msec) and outside the circuit in 6 patients (mean PPI-TCL = 53.2 msec, $p < 0.05$). The CS-9 was within the AFL circuit in 16 of 25 patients (64%: mean PPI-TCL = 15.3 msec), outside the AFL circuit in 9 patients (mean PPI-TCL = 52.8 msec, $p < 0.05$), and within the AFL circuit for both the CS anterior and posterior in 10 of 25 patients (40%).

CCW-AFL was confirmed in 16 of 25 patients. The CS-3 pacing site was within the circuit in 13 patients (81%: mean PPI-TCL = 17.3 msec) and outside the AFL circuit in 3 patients (mean PPI-TCL = 69.7 msec, $p < 0.05$). CW-AFL was confirmed in 9 of 25 patients. The CS-3 pacing site was within the AFL circuit in 6 of 9 patients (67%: mean PPI-TCL = 13.4 msec), and outside the circuit in 3 patients (mean PPI-TCL = 36.7 msec, $p = 0.15$). Pacing sites were within the AFL circuit both for the CS-3 site and CS-9 sites in 9 of 16 CCW-AFL patients (56%) and in 8 of 9 CW-AFL patients (89%) (Figs. 3, 4).

Macroreentrant circuits in CCW-AFL and CW-AFL

Entrainment mapping results indicated that the RA lower portion of the quarterly divisions (anterior, lateral, septal, and CTI near IVC), tricuspid annulus superior, and RA superior (Fig. 1) were

Table 1 Patient characteristics in CS-3 and CS-9 groups

	CS-3	CS-9	<i>p</i> value*	CS-3 and -9	<i>p</i> value**
<i>n</i>	9(36)	6(24)	NS	10(40)	NS
Male	8(89)	5(83)	NS	8(80)	NS
Age (yr)	73±8	61±19	NS	67±17	NS
Hypertension	6(67)	4(67)	NS	4(40)	NS
Ischemic heart disease	3(33)	1(17)	NS	4(40)	NS
Cardiomyopathy	1(11)	0	NS	3(30)	NS
Ia	5(56)	4(67)	NS	6(60)	NS
Ic	3(33)	2(33)	NS	2(2)	NS
CTR (%)	51±4	50±4	NS	51±4	NS
CCW	8(89)	3(50)	NS	5(50)	NS
FCL (msec)	253±33	252-42	NS	254±46	NS
PPI-FCL(msec)					
iTA	23±20	25±13	NS	21±20	NS
iCS	25±20	18±10	NS	14±16	NS
iIVC	48±17	7±4	0.028	17±13	0.008
CS-3	22±9	53±21	0.027	9±6	0.021
CS-9	53±11	16±9	0.028	16±10	0.008

Continuous values are mean±SD. (): %.

*CS-3 vs CS-9, **CS-3 vs CS-3 and -9.

Ia=Vaughan-Williams Ia group drug; Ic=Vaughan-Williams Ic group; CTR=cardiothoracic ratio on chest radiography; CCW=counterclockwise; FCL=flutter cycle length; PPI=post pacing interval. Other abbreviations as in Fig. 1.

Table 2 Patient characteristics in CW-AFL and CCW-AFL groups

	CW-AFL (<i>n</i> =9)	CCW-AFL (<i>n</i> =16)	<i>p</i> value
Male	6(67)	15(94)	NS
Age (yr)	65±17	69±17	NS
Hypertension	6(67)	8(50)	NS
Ischemic heart disease	4(44)	4(25)	NS
Cardiomyopathy	2(22)	2(13)	NS
Ia	5(56)	10(63)	NS
Ic	3(33)	4(25)	NS
CTR (%)	51±3	51±5	NS
FCL (msec)	257±45	251±37	NS
PPI-FCL(msec)			
iTA	21±12	24±21	NS
iCS	21±16	18±18	NS
iIVC	16±14	31±24	0.032
CS-3	20±14	27±24	NS
CS-9	18±13	35±22	0.007

Continuous values are mean±SD. (): %.

CW=clockwise; AFL=atrial flutter. Other abbreviations as in Fig. 1, Table 1.

part of the reentrant circuit because the PPI-TCL was within 30 msec of the TCL. The tricuspid annulus superior site at roughly 11:00 to 12:00 in the LAO projection was outside the AFL circuit in 6 of 25 patients (mean PPI-TCL = 42 msec). The superior RA site was within the AFL circuit in 5 patients (mean PPI-TCL = 16.2 msec). Lower loop reentry (LLR)^{5,6)} demonstrated in the posterior and septal regions of the lower RA along the IVC, was within the AFL circuit in 17 patients. Only the LLR circuit was within the AFL circuit in 3 patients, 1 with CCW-AFL and 2 with CW-AFL.

3D activation mapping in 10 of these 14 patients showed identical revolution times around the IVC and tricuspid annulus (Figs 3, 4). Typical AFL with a single reentrant loop around the tricuspid annulus was confirmed in 6 patients, all of whom had CCW-AFL. Activation wave fronts collided at the septum where a substantial conduction delay was noted (Fig. 5) at the CS-3 site in patients with CS posterior conduction breakthrough and only LLR circuit.

DISCUSSION

Our major finding was that most CTI-dependent




Fig. 2 Post pacing interval-flutter cycle length (PPI-FCL)

Subjects were divided into three groups based on atrial flutter circuit patients at the coronary sinus orifice, CS-3 and CS-9 and cavotricuspid isthmus.

CS-3 < 30 msec group: PPI-TCL < 30 msec at both the CS-3 and near the tricuspid annulus sites.

CS-9 < 30 msec group: PPI-TCL < 30 msec at both the CS-9 and near the inferior vena cava sites.

CS-3 and -9 < 30 msec group: PPI-TCL < 30 msec at both CS-3 and CS-9.

Mean PPI-FCL from two points was compared, and *p* is shown. Values are numbers of cases or mean \pm SD. Statistical comparisons within the group were made using a paired *t*-test. *p* < 0.05 was considered statistically significant.

Abbreviations as in Fig. 1, Tables 1, 2.

AFL involved a reentrant circuit around the CS-9 site in both CCW-AFL and CW-AFL cases. Entrainment pacing at the CS-9 site along the EVR or the posterior septum revealed that PPIs were comparable to the TCL in 16 of 25 patients. CS-9 conduction traversed between the IVC and CS orifice in 13 of these 16 patients. 3D activation sequence mapping showed an activation wave front circulating around the IVC or the RA superior, with evidence of slow conduction in 6 of the 25 patients. Activation wave fronts collided at the internal septum at the CS-3 site in patients with CS posterior conduction breakthrough and only LLR circuit (**Fig. 5**).

Conduction breakthrough the EVR in CTI-dependent AFL

The musculature of the CS has been implicated in a variety of arrhythmias, including those mediated by accessory pathways, and focal^{13,14} and macroreentrant atrial tachycardia.^{7,15} This musculature has a consistent but morphologically variable left atrial CS myocardial connection^{2,5,9,16,17} and

RA of CTI in the tricuspid trabecular muscle. A recent anatomical study⁴ reported that the EVR had a small flat area remaining between the EVR and CS orifice in 44% of necropsied normal human hearts (*n* = 80). Our study provides the first evidence that almost all CTI-dependent AFL may be occur through the CS posterior wall. In short, the EVR and circuit pattern and both CCW and CW did not differ in patients without prior atriotomy. Recent studies suggested that conduction through the EVR was highly possible.^{2,5,6,11,16,17} During early conduction breakthrough in the lower RA, the activation wave front collided in the high lateral RA or the septum, and conduction through the CTI was demonstrated by activation sequence mapping or 3D electroanatomical mapping in 6 CCW-AFL patients (spontaneously in 3)⁶ and in 11 of 12 CW-AFL patients.¹¹ Analysis of 36 episodes of sustained atypical right AFL found LLR in 24 (67%), 13 (54%) episodes had early breakthrough at the lower lateral tricuspid annulus, and 9 (38%) episodes showed multiple annular breaks.⁵ A pattern of posterior breakthrough from the EVR to the

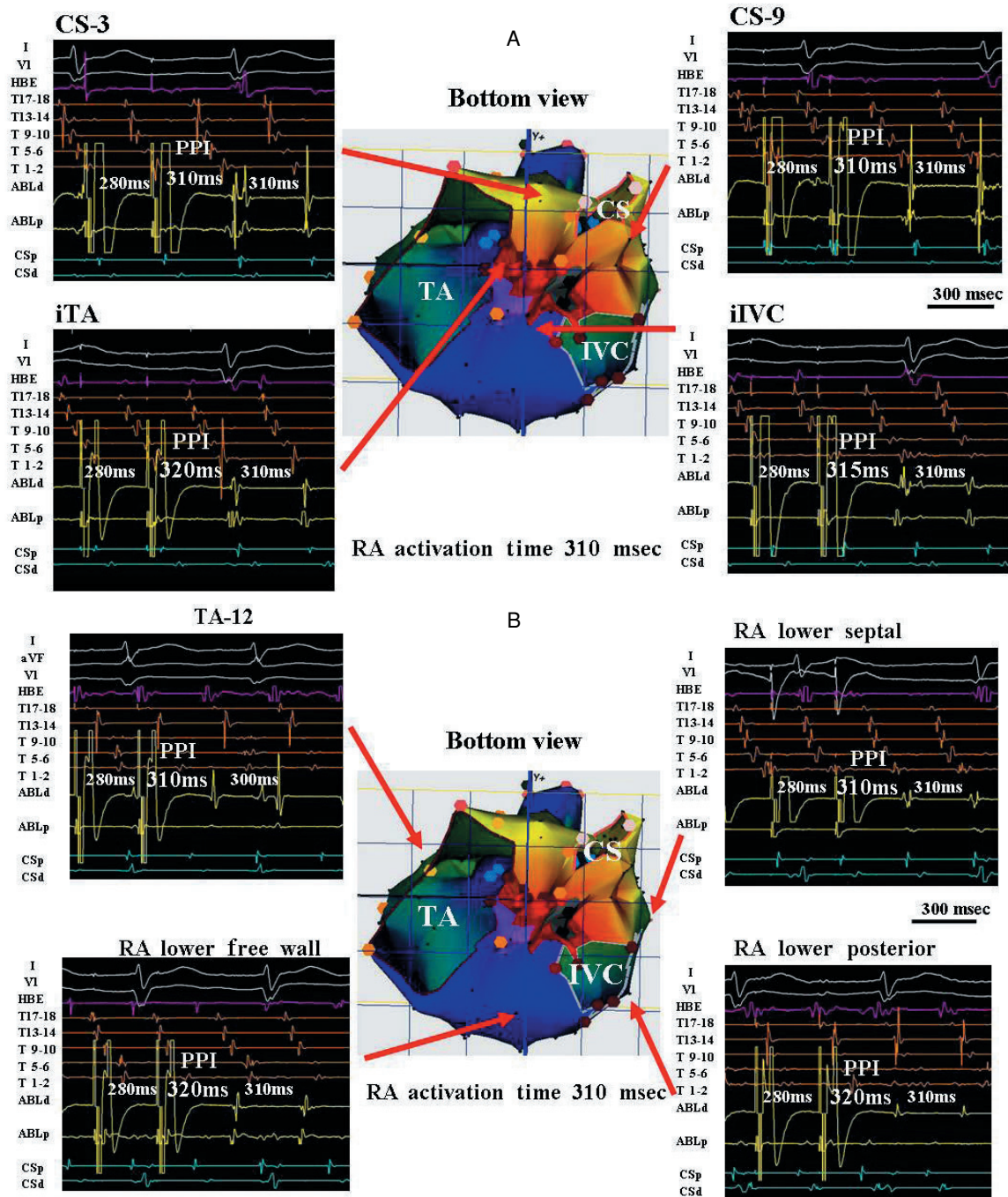


Fig. 3 Representative case with counterclockwise atrial flutter (CCW-AFL)

A: In the 3-dimensional-activation map (center), blue dots represent double potential and fragment electrograms. Red dots are radiofrequency points. Black dots and area are < 0.1 mV. Reference electrograms were recorded within the coronary sinus. Activation proceeded in a complete CCW loop from red to purple around the TA and IVC. Entrainment pace mapping sites, CTI (iTA and iIVC), and coronary sinus orifices (CS-3 and CS-9) to measure PPI are shown by red arrows. Entrainment pacing from the iTA and iIVC revealed a PPI of 320 and 315 msec, which indicated that the iTA and iIVC are part of the reentrant circuit. Similarly, entrainment pacing from CS-3 and CS-9 revealed PPI for both of 310 msec, indicating that CS-3 and CS-9 may be part of the reentrant circuit. The iIVC electrogram sequence seems to be different from the other site of T1-2 and ABL-d. The iIVC pacing site is slightly in the RA lower free wall direction, so the multielectrode catheter T1-2 and ABL-d are closer.

B: Entrainment pace mapping sites, superior TA (TA-12) and around IVC, are shown by red arrows. Entrainment pacing from TA-12, RA lower free wall, lower posterior wall, and lower septal wall revealed PPI of 310, 320, 320, and 310 msec, respectively, which indicates that both the superior TA and around the IVC are part of the reentrant circuit. These results may suggest that activation from the CTI to CS-3 and CS-9 traversed the eustachian ridge/valve, and circulated around the TA and lower RA. ABL-d, ABL-p = radiofrequency ablation catheter distal and proximal bipolar electrogram; CS-d, CS-p = coronary sinus distal and proximal electrogram; HBE = His bundle electrogram; T17-18, T13-14, T9-10, T5-6, T1-2 = bipolar electrograms recorded from decapolar catheter placed around TA. Other abbreviations as in Fig. 1, Tables 1, 2.

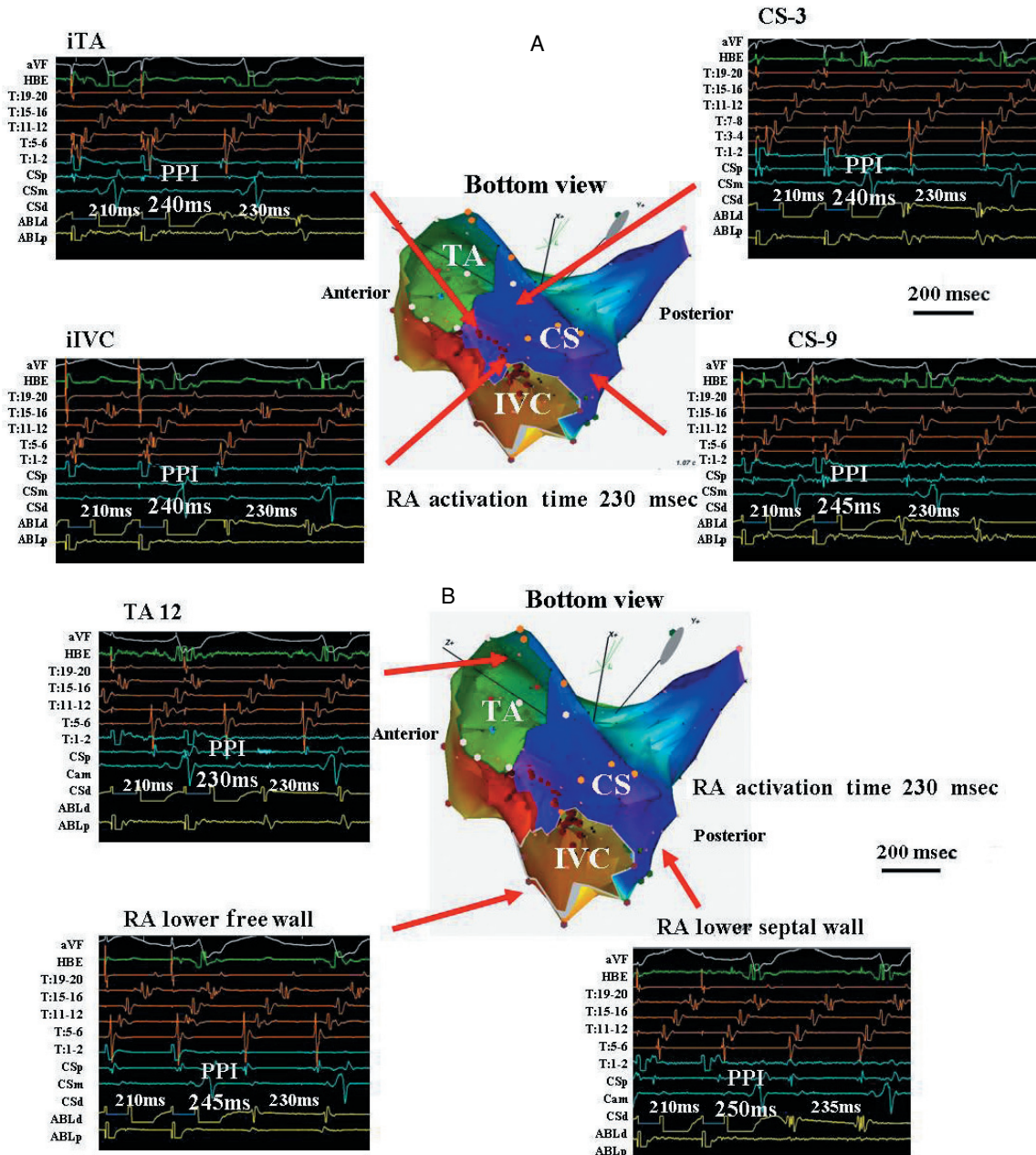


Fig. 4 Representative case with clockwise atrial flutter (CW-AFL)

A: In the 3-dimensional-activation map (*center*), blue dots represent double potentials and fragments. Red dots are radiofrequency ablation points. Activation proceeded in a complete CW loop from red to purple around the TA and IVC. Entrainment pace mapping sites to measure the PPI are shown by red arrows. Entrainment pacing from the iTA and iIVC, CS-3, CS-9 revealed PPI of 240, 240, 240, and 245 msec, respectively, which may suggest that all of the CTI (iTA and iIVC), CS-3, and CS-9 are part of the reentrant circuit.

B: Entrainment pacing from the TA-12, RA lower free wall, and lower septal wall revealed PPI of 230, 245, and 250 msec, respectively, which also indicates that all of the superior TA, RA lower free wall, and lower septal wall were part of the reentrant circuit. These mapping results consisted of the conduction from CS-3 and CS-9 to CTI.

Abbreviations as in Figs. 1, 3, Tables 1, 2.

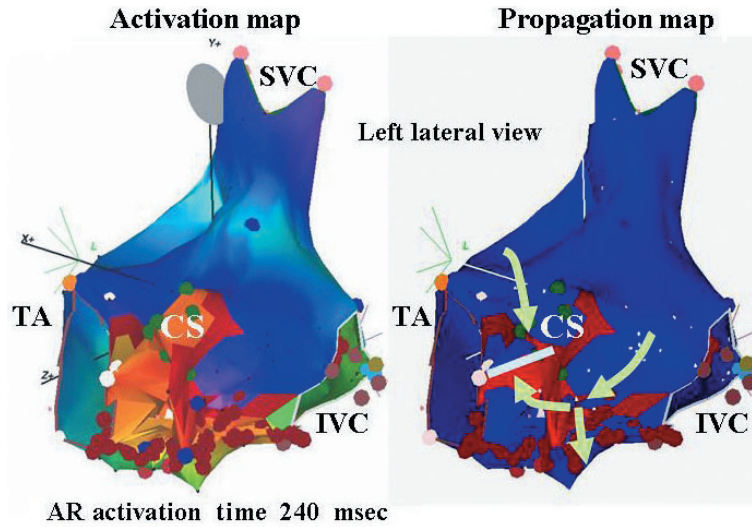


Fig. 5 Lower loop reentry in clockwise atrial flutter in left lateral view

Left: The RA posterior wall and septal wall (included the coronary sinus area) are forward sites. 3-dimensional electroanatomical map of baseline in lower loop reentry (LLR). Blue dots: double potential. Yellow dots: fractionated potential. Red dots: ablation point. Activation proceeds in a complete CW loop from red to purple around the IVC. The CTI is activated from posteromedial to anterolateral as in CW-AFL.

Right: CW-AFL propagation during tachycardia showed the activation wave front around the IVC. The red zone indicates propagation of the activation wave front and the blue zone regions recovering from previous excitation. Green arrows represent the earliest wave front of CW-AFL around the coronary sinus orifice. In this map, the collision of wave fronts is shown at mid-septum (white bar) in the lower septum, so the circuit around the tricuspid annulus blocked conduction. Separate from this conduction, another conduction circled around IVC and formed the second reentrant circuit, LLR. In this CW-AFL case, LLR consisted of conduction that broke through the eustachian ridge/valve.

Abbreviations as in Figs. 1, 3, Tables 1, 2.

septum was observed in 4 (14%) of 28 patients. None of these studies conducted high-density entrainment mapping to determine the CS orifice position or included atypical conduction pattern CCW-AFL patients. In common AFL, the LLR circuit is considered to be the flutter activation front, which circles along the IVC, through the CS-3 site, and curves in the mid RA septum.^{3,6,11)} In atypical AFL patients, the lower loop activation wavefront could break EVR directly.^{5,11)} In our study, the lower loop activation front was defined through the CS-9 or CS-3, and formed a LLR circuit in both CW-AFL and CCW-AFL patients.

Reentry circuits in CTI-dependent AFL

Postoperative macroreentrant AFL includes DLR and figure-of-eight loops. These AFLs circulate around postoperative scars, which could slow the conduction zone formed in injured myocardial muscles adjacent to operative scars or anatomical barriers.^{7,8)} DLR was defined in 6 of 12 CCW-AFL patients who had no cardiotomy.³⁾ Entrainment mapping was conducted to evaluate atrial electro-

grams from the tricuspid annulus and the posterior RA with paradoxical delayed capture and found that the posterior line of the block did not extend to the superior vena cava. DLR in 4 of 12 CW-AFL patients after applying 3D anatomical mapping found that 4 tachycardia episodes involved a CW loop around the tricuspid annulus and showed reentrant tachycardia around the IVC, with the activation wave front propagating from the septal to the lateral aspect of the CTI.¹¹⁾

Study limitations

Our study has certain limitations. Our analysis of PPI was limited to sites at which entrainment pacing had a measurable effect on RA conduction. Pacing of the entire EVR would have made it very difficult to compare electrograms at the same recording site in all patients. Application of intracardiac echocardiography, a technique to visualize various intra-atrial structures that are not visualized on fluoroscopy, may allow precise localization of the intracardiac catheters relative to these anatomic structures.¹⁸⁾ Some of the flutter involved was rela-

tively slow, suggesting that an antiarrhythmic drug effect may have persisted.

We did not determine the potential influence of the crista terminalis, an elongated muscular prominence between the SVC and IVC in the posterolateral wall of the RA.^{3,18)} The crista terminalis and sinus venosa were demonstrated to be the line of the conduction block during typical AFL. However, most crista terminalis conduction gaps using non-contact mapping are functional and only appeared when upper loop reentry was done to evaluate transverse conduction across the crista terminalis during typical AFL, and pacing from the CS and low anteriolateral RA found no transverse crista terminalis gap conduction during typical AFL.¹⁹⁾ We evaluated only the crista terminalis lower position (RA lower lateral position) and superior crista terminalis (RA superior position) using entrainment pace mapping, so we did not evaluate the crista terminalis gap and CS pacing or posterior block line in detail.

The present study performed entrainment pacing outside around CS orifice, IVC, superior RA and obtained PPI-FCL within 30 msec in almost all CTI-dependent AFL patients. However, we did not use the multi-electrode catheter location for the RA

posterior wall^{3,11)} and simultaneously measured paradoxical delayed capture of both tricuspid annulus and IVC or superior RA site. Therefore, to confirm dual loop reentry circuit, this issue should be taken into consideration in future studies. In addition, the validity of our criteria for the position on the AFL circuit, PPI-FCL of shorter than 30 msec, should be confirmed by future studies.

CONCLUSIONS

We have demonstrated that almost all flutter patients had a CS anatomical barrier, although CS-3 and CS-9 muscular conductions were separated by the CTI trabecular muscle layer. CS-9 conduction may extend from the lower RA to the anterior RA through the CTI, and consist of a flutter circuit, which may be critical for maintaining AFL. Most AFL was propagated in a broad-band flutter wave front pattern from the RA post-septal wall to the CTI or vice versa, through CS orifice conduction, so radiofrequency ablation should be performed closely along the complete bidirectional block line in the CTI. Therefore, in an incomplete isthmus block line or recurrence of CTI-dependent AFL, analysis of CS orifice conduction may be useful for obtaining a complete bidirectional block line.

要 約

三尖弁輪-下大静脈間峡部依存性心房粗動における

冠状静脈洞周囲伝導の役割

山口 善央 津川 博一 藤岡 央
 紘野 健一 北山 道彦 梶波 康二

目 的: 三尖弁輪-下大静脈間峡部依存性心房粗動において、冠状静脈洞後壁を伝播する旋回路が存在し、それがlower loop reentryを形成し、それによってdual loop reentryが形成されるのではないかと仮定した。

方 法: 対象は慢性心房粗動連続25例の通常型心房粗動(CCW-AFL)16例と非通常型心房粗動(CW-AFL)9例である。冠状静脈洞周囲でentrainment pace mappingを施行し、post pacing interval (PPI)とtachycardia cycle length (TCL)を計測し、旋回路が冠状静脈洞の三尖弁輪側か下大静脈側のどちらかを旋回するのかを検討した。また、併せてelectroanatomical mappingを施行した。

結 果: PPI-TCLの結果からは、CCW-AFL16例中13例とCW-AFL9例中6例が冠状静脈洞の三尖弁輪側を通過すると考えられた。さらにCCW-AFL8例とCW-AFL8例が冠状静脈洞の三尖弁輪側も下大静脈側も同様に通過すると考えられた。Electroanatomical mappingの結果では、それらはdual loop reentryを形成している可能性が示された。

結 論: 冠状静脈洞下大静脈側を伝播する心房粗動の興奮波は、三尖弁輪-下大静脈間峡部依存性心房粗動の成立・維持に関連しているものと推察された。

J Cardiol 2007 Jul; 50(1): 1-10

References

- 1) Cosio FG, Lopez-Gil M, Goicolea A, Arribas F, Barroso JL: Radiofrequency ablation of the inferior vena cava-tricuspid valve isthmus in common atrial flutter. *Am J Cardiol* 1993; **71**: 705–709
- 2) Nakagawa H, Lazzara R, Khastgir T, Beckman KJ, McClelland JH, Imai S, Pitha JV, Becker AE, Arruda M, Ganzalez MD, Widman LE, Rome M, Neuhauser J, Wang X, Calame JD, Goudeau MD, Jackman WM: Role of the tricuspid annulus and the eustachian valve/ridge on atrial flutter: Relevance to catheter ablation of the septal isthmus and a new technique for rapid identification of ablation success. *Circulation* 1996; **94**: 407–424
- 3) Fujiki A, Nishida K, Sakabe M, Sugao M, Tsuneda T, Mizumaki K, Inoue H: Entrainment mapping of dual-loop macroreentry in common atrial flutter: New insights into the atrial flutter circuit. *J Cardiovasc Electrophysiol* 2004; **15**: 679–685
- 4) Adachi M, Igawa O, Tomokuni A, Sawaguchi M, Suga T, Yano A, Miake J, Inoue Y, Fujita S, Shigemasa C: Anatomical characteristics of the Eustachian ridge, a barrier to conduction during common type atrial flutter. *Circulation* 1996; **94**(Suppl): 1-380(abstr)
- 5) Yang Y, Cheng J, Bochoeyer A, Hamdan MH, Kowal RC, Page R, Lee RJ, Steiner PR, Saxon LA, Lesh MD, Modin GW, Scheinman MM: Atypical right atrial flutter patterns. *Circulation* 2001; **103**: 3092–3098
- 6) Cheng J, Cabeen WR Jr, Scheinman MM: Right atrial flutter due to lower loop reentry: Mechanism and anatomic substrates. *Circulation* 1999; **99**: 1700–1705
- 7) Magnin-Poull I, De Chillou C, Miljoen H, Andonache M, Aliot E: Mechanisms of right atrial tachycardia occurring late after surgical closure of atrial septal defects. *J Cardiovasc Electrophysiol* 2005; **16**: 681–687
- 8) Shah D, Jais P, Takahashi A, Hocini M, Peng JT, Clementy J, Haissaguerre M: Dual-loop intra-atrial reentry in humans. *Circulation* 2000; **101**: 631–639
- 9) Shah D, Haissaguerre M, Jais P, Takahashi A, Hocini M, Clementy J: High-density mapping of activation through an incomplete isthmus ablation line. *Circulation* 1999; **99**: 211–215
- 10) Morton JB, Sanders P, Deen V, Vohra JK, Kalman JM: Sensitivity and specificity of concealed entrainment for the identification of a critical isthmus in the atrium: Relationship to rate, anatomic location and antidromic penetration. *J Am Coll Cardiol* 2002; **39**: 896–906
- 11) Zhang S, Younis G, Hariharan R, Ho J, Yang Y, Ip J, Thakur RK, Seger J, Scheinman MM, Cheng J: Lower loop reentry as a mechanism of clockwise right atrial flutter. *Circulation* 2004; **109**: 1630–1635
- 12) Tada H, Oral H, Sticherling C, Chough SP, Baker RL, Wasmer K, Pelosi FJ, Knight, Strickberger SA, Morady F: Double potentials along the ablation line as a guide to radiofrequency ablation of typical atrial ablation. *J Am Coll Cardiol* 2001; **38**: 750–755
- 13) Chugh A, Oral H, Good E, Han J, Tamirisa K, Lemola K, Elmouchi D, Tschopp D, Reich S, Igic P, Borun F, Pelosi F, Morady F: Catheter ablation of atypical atrial flutter and atrial tachycardia within the coronary sinus after left atrial ablation for atrial fibrillation. *J Am Coll Cardiol* 2005; **46**: 83–91
- 14) Kistler PM, Fynn SP, Haqqani H, Stevenson IH, Vohra JK, Morton JB, Sparks PB, Kalman JM: Focal atrial tachycardia from the ostium of the coronary sinus: Electrocardiographic and electrophysiological characterization and radiofrequency ablation. *J Am Coll Cardiol* 2005; **45**: 1488–1493
- 15) Markowitz SM, Brodman RF, Stein KM, Mittal S, Slotwiner DJ, Iwai S, Das MK, Lerman BB: Lesional tachycardias related to mitral valve surgery. *J Am Coll Cardiol* 2002; **39**: 1973–1983
- 16) Antz M, Otomo K, Arruda M, Scherlag BJ, Pitha J, Tondo C, Lazzara R, Jackmann WM: Electrical conduction between the right atrium and the left atrium via the musculature of the coronary sinus. *Circulation* 1998; **98**: 1790–1795
- 17) Chauvin M, Shah DC, Haissaguerre M, Marcellin L, Brachenmacher C: The anatomic basis of connections between the coronary sinus musculature and the left atrium in humans. *Circulation* 2000; **101**: 647–652
- 18) Olgin JE, Kalmann JM, Fitzpatrick AP, Lesh MD: Role of right atrial endocardial structures as barriers to conduction during human type I atrial flutter: Activation and entrainment mapping guided by intracardiac echocardiography. *Circulation* 1995; **92**: 1839–1848
- 19) Liu TY, Tai CT, Huang BH, Higa S, Lin YJ, Huang JL, Yuniadi Y, Lee PC, Ding YA, Chen SA: Functional characterization of the crista terminalis in patients with atrial flutter: Implications for radiofrequency ablation. *J Am Coll Cardiol* 2004; **43**: 1639–1645