

Accessory Mitral Valve Associated With Aortic and Mitral Regurgitation and Left Ventricular Outflow Tract Obstruction in an Elderly Patient: A Case Report

Hidekazu TANAKA, MD
Hiroya KAWAI, MD, FJCC
Kazuhiro TATSUMI, MD
Toshiya KATAOKA, MD
Tetsuuri ONISHI, MD
Mitsuhiro YOKOYAMA, MD, FJCC
Yutaka OKITA, MD*

Abstract

A 65-year-old man was admitted to our hospital because of exertional dyspnea. Transthoracic and transesophageal echocardiography showed a parachute-like structure measuring 20 × 16 mm, which projected into the left ventricular outflow tract (LVOT) and passed through the aortic valve in systole, and prolapsed back into the left ventricular cavity in diastole. Moderate aortic and mitral regurgitation were also observed, as well as LVOT obstruction with a peak gradient of 30 mmHg. There were no other congenital cardiac abnormalities. In addition, real-time three-dimensional transthoracic echocardiography showed that the parachute-like structure in the LVOT was attached to the anterior mitral leaflet and left ventricular lateral wall by a chorda tendineae-like structure. The diagnosis of accessory mitral valve was based on the echocardiographic characteristics. Surgical treatment was performed because of the presence of accessory mitral valve, moderate aortic and mitral regurgitation, and LVOT obstruction. The postoperative course was uneventful, and the patient has been asymptomatic during a follow-up period of 24 months. Echocardiographic examination proved to be useful for the detection of accessory mitral valve.

J Cardiol 2007 Jul; 50(1): 65–70

Key Words

- Aortic regurgitation
- Mitral regurgitation
- Congenital heart disease (accessory mitral valve)

INTRODUCTION

Accessory mitral valve (AMV) is a congenital anomaly that can lead to left ventricular outflow tract (LVOT) obstruction and is extremely rare in adults. More than half of the cases show other congenital cardiac anomalies.^{1–4)} This report concerns

a 65-year-old man who had AMV associated with LVOT obstruction, significant aortic regurgitation (AR) and mitral regurgitation (MR). Surgical treatment was successful and echocardiographic examination proved to be useful for the detection of AMV.

神戸大学大学院医学系研究科 循環呼吸器病態学, *呼吸循環器外科学: 〒650-0017 神戸市中央区楠町 7-5-2
Division of Cardiovascular and Respiratory Medicine, Department of Internal Medicine, *Department of Cardiovascular, Thoracic, and Pediatric Surgery, Kobe University Graduate School of Medicine, Kobe

Address for correspondence: KAWAI H, MD, FJCC, Division of Cardiovascular and Respiratory Medicine, Department of Internal Medicine, Kobe University Graduate School of Medicine, Kusunoki-cho 7-5-2, Chuo-ku, Kobe 650-0017; E-mail: hkawai@med.kobe-u.ac.jp

Manuscript received February 28, 2007; revised April 7, 2007; accepted April 10, 2007

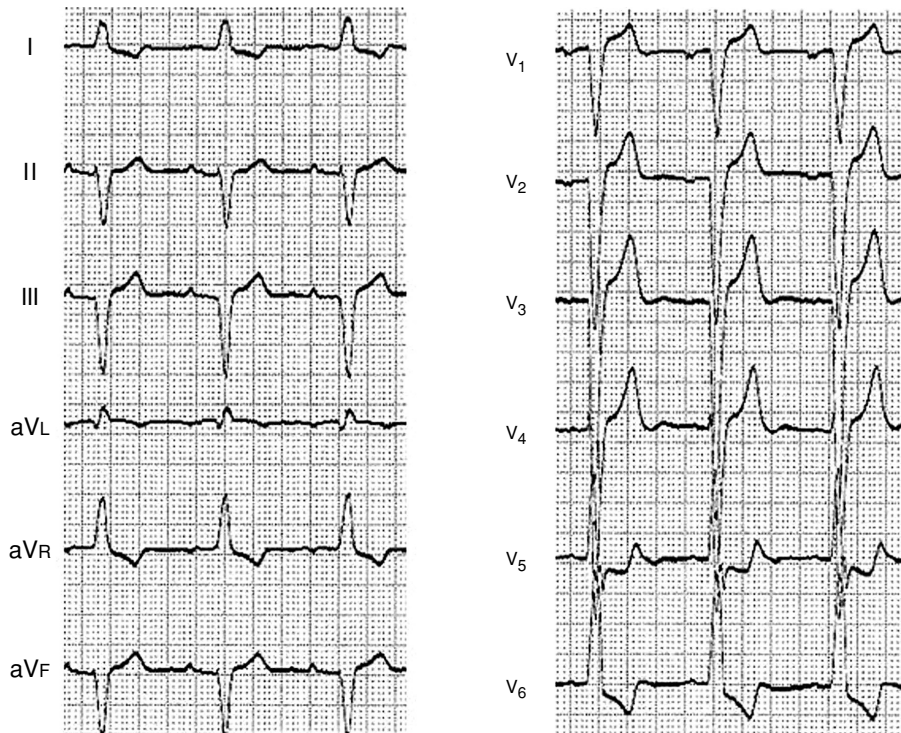


Fig. 1 Electrocardiogram

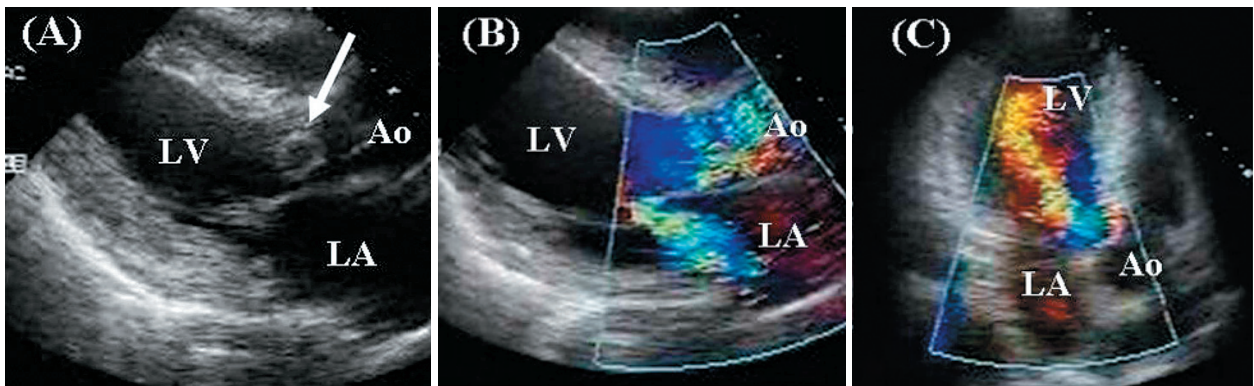


Fig. 2 Transthoracic echocardiograms

String-like abnormal structure was visible in the left ventricular outflow tract (arrow), with moderate mitral regurgitation (B) and aortic regurgitation (C). Mild left ventricular outflow tract obstruction was present with a peak gradient of 30 mmHg.

LV = left ventricle; LA = left atrium; Ao = aorta.

CASE REPORT

A 65-year-old man was admitted to our hospital because of exertional dyspnea. Electrocardiography had shown an abnormality 7 years previously, which had not been identified. Physical examination found his blood pressure was 148/72 mmHg and pulse regular at 72 beats/min. A Levine III to-and-fro type heart murmur was detected at the left

sternal border in the third intercostal space. Laboratory test results were normal except for brain natriuretic peptide level (120 pg/ml). Chest radiography indicated a cardiothoracic ratio of 62% and enlargement of the left ventricle, and electrocardiography (Fig. 1) showed complete left bundle-branch block. Transthoracic echocardiography (Fig. 2) showed a string-like abnormal structure in the LVOT, moderate AR and MR, and mild LVOT

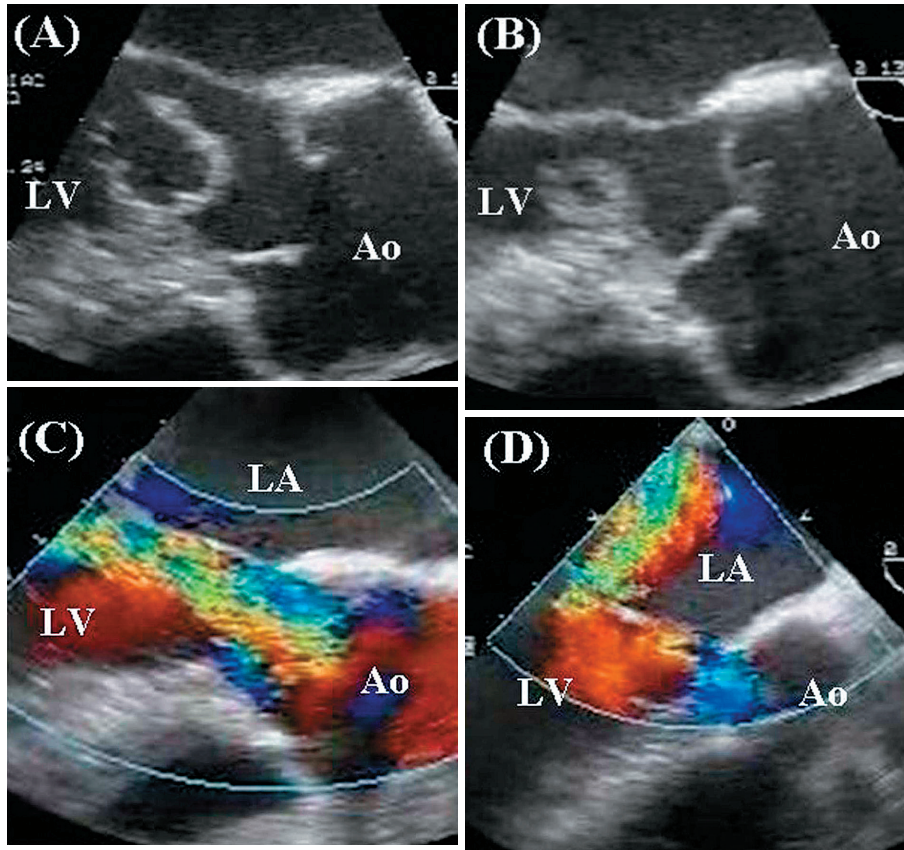


Fig. 3 Transesophageal echocardiograms

A parachute-like structure measuring 20×16 mm projected into the left ventricular outflow tract and through the aortic valve in systole (A) and prolapsed back into the left ventricular cavity in diastole (B). Moderate aortic regurgitation (C) and mitral regurgitation (D). Abbreviations as in Fig. 2.

obstruction with a peak gradient of 30 mmHg. The end-diastolic and end-systolic diameters of the left ventricle were 59 mm and 40 mm, respectively, and the left ventricular ejection fraction was 54%.

Transesophageal echocardiography (Fig. 3) indicated that a parachute-like structure measuring 20×16 mm projected into the LVOT and passed through the aortic valve in systole, and prolapsed back into the left ventricular cavity in diastole. Moderate AR and MR were also observed, but no other congenital cardiac abnormalities. Real-time three-dimensional transthoracic echocardiography clarified that the parachute-like structure in the LVOT was attached to the anterior mitral leaflet and left ventricular lateral wall by a chorda tendineae-like structure (Fig. 4). The diagnosis of AMV was based on the echocardiographic findings.

Coronary angiography showed no significant stenosis. The patient's AR was Sellers grade III,

and pulmonary capillary wedge pressure, pulmonary blood pressure, and cardiac index were 9 mmHg, 29/6 mmHg, and 3.78 l/min/m², respectively. Left ventriculography was not performed because of the presence of the abnormal tissue in the LVOT. Surgical treatment was recommended because of the presence of AMV, and significant AR, MR, and LVOT obstruction.

At surgery, the mass was confirmed to be a parachute-like structure attached to the lateral site of the anterior mitral leaflet and left ventricular lateral wall by a chordae tendineae-like structure and tethered to the anterior mitral leaflet. The mass was removed without complications by aortotomy, and gross examination (Fig. 5-A) indicated a smooth and valvular leaflet-like structure. Because of the thickened aortic valves and enlarged fenestrations of the left coronary cusp, the aortic valve was replaced with a 23 mm Carpentier-Edwards valve.

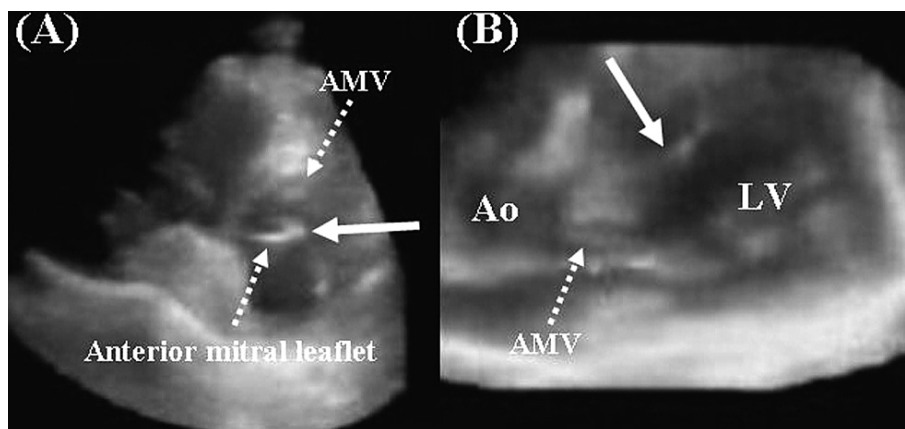


Fig. 4 Real-time three-dimensional echocardiograms

A: The parachute-like structure was attached to the anterior mitral leaflet (*arrow*).

B: The parachute-like structure was attached to the left ventricular lateral wall by a chorda tendineae-like structure (*arrow*).

AMV = accessory mitral valve. Other abbreviations as in Fig. 2.

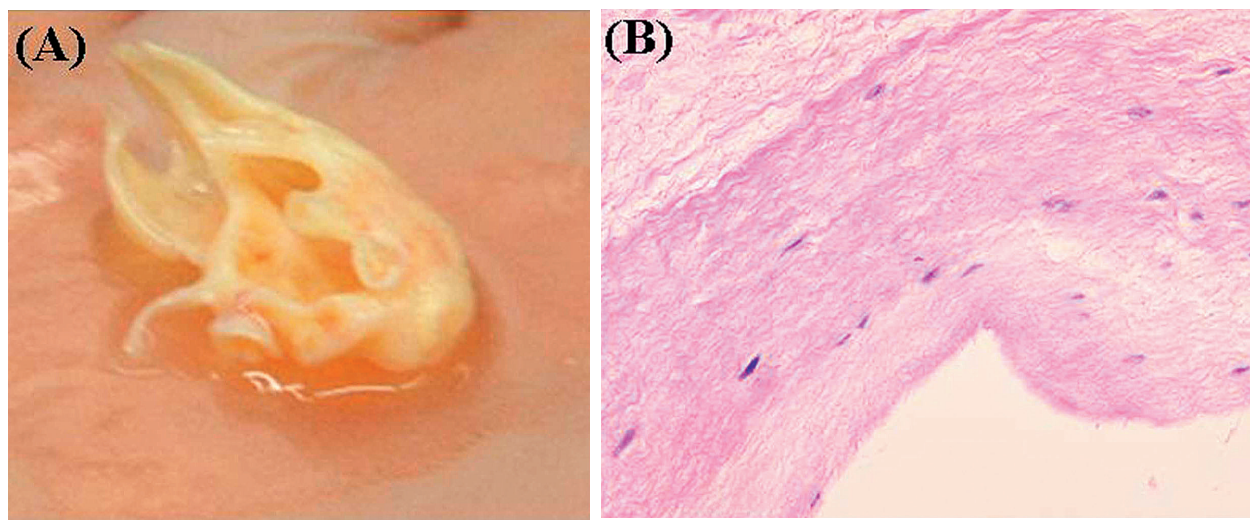


Fig. 5 Photograph and photomicrograph of the accessory mitral valve

Gross examination (*A*) showed a smooth and valvular leaflet-like structure. Histological examination (*B*; hematoxylin-eosin staining $\times 100$) showed normal mitral valve tissue. No fibrous tissue or myxoid dysplasia was found.

The mitral valve was repaired with a 30 mm Physio-ring. Histological examination (**Fig. 5–B**) showed normal mitral valve tissue, leading to a diagnosis of AMV.

After surgery, transthoracic echocardiography demonstrated resolution of the LVOT obstruction and absence of residual AMV, AR and MR. The postoperative course was uneventful, and the patient has been asymptomatic during a follow-up period of 24 months.

DISCUSSION

The present elderly patient with AR, MR, and LVOT obstruction caused by AMV could be successfully treated with surgery. Transthoracic, transesophageal, and real-time three-dimensional transthoracic echocardiography proved to be useful for the detection of AMV.

AMV is an extremely rare congenital cardiac anomaly, which can cause a variety of clinical fea-

tures.¹⁻⁴⁾ Currently, fewer than 100 cases of AMV have been reported, with adults accounting for fewer than 30, since the first description in 1963.⁵⁾ AMV has been diagnosed immediately after birth, and in a 77-year-old patient. The mean age at diagnosis is around 6.5 years.⁶⁾ Little is known about the etiology and course of AMV. AMV is probably the result of incomplete separation of the mitral valve from the endocardial cushion tissue to the ventricular septum during embryological development.⁷⁾ Histological descriptions of tissue specimens in some cases of AMV indicate that about half show normal mitral valve tissue (including our patient), and the remainder have fibrous tissue or myxoid dysplasia.^{1, 8-10)} AMV is usually (more than 70%) associated with other congenital cardiac anomalies and often produces significant cardiac symptoms in the neonatal period or early child-

hood. Ventricular septal anomalies, mainly ventricular septal defect and septal aneurysm, are the most frequently encountered anomalies.¹¹⁾ Most cases were associated with LVOT obstruction, and about 80% presented severe LVOT obstruction with a peak gradient of more than 50 mmHg.¹²⁾ The symptoms in patients with AMV depend on the degree of LVOT obstruction.^{12,13)} However, our patient had been asymptomatic until 65 years old. The cause of his exertional dyspnea might be significant AR or MR.

The main indication for surgery for AMV is severe LVOT obstruction, other congenital malformations, or exploration of an intracardiac mass.^{12,13)} Early surgical removal is recommended for AMV causing LVOT obstruction because the pressure gradient may increase with age.¹³⁾

要 約

大動脈弁、僧帽弁閉鎖不全症と左室流出路狭窄を伴った高齢者の僧帽弁副組織の1例

田中 秀和 川合 宏哉 辰巳 和宏 片岡 俊哉

大西 哲存 横山 光宏 大北 裕

症例は65歳、男性。労作時の呼吸困難のため当院に入院となった。経胸壁および経食道心エコー図断層図では左室流出路に20×16mmのバラシュート状の構造物を認め、収縮期には大動脈弁側へ、拡張期には左室側へ移動していた。カラードップラー法により大動脈弁および僧帽弁逆流はともに中等度であり、連続波ドップラー法により推定圧較差が30mmHgの左室流出路狭窄を伴っていた。他の先天性心疾患の合併は認められなかった。さらに、経胸壁リアルタイム三次元心エコー図ではバラシュート様の膜様構造物が僧帽弁前尖と左室側壁に腱索様の組織で付着していることが観察された。以上の心エコー図所見より、異常構造物は僧帽弁副組織と診断した。左室流出路に異常構造物が存在すること、有意な大動脈弁および僧帽弁逆流と左室流出路狭窄が認められることより、外科的手術を行った。術後の経過は良好で、現在、無症状で術後24ヵ月経過している。今回我々が経験した僧帽弁副組織の観察には、経胸壁リアルタイム三次元心エコー図検査を含めた心エコー図検査が有用であった。

J Cardiol 2007 Jul; 50(1): 65-70

References

- 1) Ascutito RJ, Ross-Ascutito NT, Kopf GS, Kleinman CS, Talner NS: Accessory mitral valve tissue causing left ventricular outflow obstruction (two-dimensional echocardiographic diagnosis and surgical approach). *Ann Thorac Surg* 1986; **42**: 581-584
- 2) Akasaka T, Anbe J, Nakajima H, Ozeki M, Mitsuishi T, Suzuki R, Takahashi S, Yanagawa Y: Successful surgical treatment of subaortic stenosis caused by an accessory mitral valve. *J Cardiovasc Surg (Torino)* 1990; **31**: 584-586
- 3) Eiriksson H, Midgley FM, Karr SS, Martin GR: Role of echocardiography in the diagnosis and surgical management of accessory mitral valve tissue causing left ventricular outflow tract obstruction. *J Am Soc Echocardiogr* 1995; **8**: 105-107
- 4) Yasui H, Kado H, Tokunaga S, Kanegae Y, Fukae K, Masuda M, Tokunaga K: Trans-ventricular septal defect approach for resection of accessory mitral valve tissue. *Ann Thorac Surg* 1993; **55**: 950-953
- 5) Shone JD, Sellers RD, Anderson RC, Adams P Jr, Lillehei

- CW, Edwards JE: The developmental complex of “parachute mitral valve”, supra-ventricular ring of left atrium, subaortic stenosis, and coarctation of aorta. *Am J Cardiol* 1963; **11**: 714–725
- 6) Meyer-Hetling K, Alexi-Meskishvili VV, Dahnert I: Critical subaortic stenosis in a newborn caused by accessory mitral valve tissue. *Ann Thorac Surg* 2000; **69**: 1934–1937
 - 7) Van Praagh R, Corwin RD, Dahlquist EH Jr, Freedom RM, Mattioli L, Nebesar RA: Tetralogy of Fallot with severe left ventricular anomalous attachment of the mitral valve to the ventricular septum. *Am J Cardiol* 1970; **26**: 93–101
 - 8) Sono J, McKay R, Arnold RM: Accessory mitral valve leaflet causing aortic regurgitation and left ventricular outflow tract obstruction: Case report and review of published reports. *Br Heart J* 1988; **59**: 491–497
 - 9) Kuribayashi R, Imai T, Yagi Y, Gomi H: Subaortic stenosis caused by an accessory tissue of the mitral valve. *J Cardiovasc Surg (Torino)* 1979; **20**: 591–596
 - 10) Tanimoto T, Kajino T, Hirose O, Kamiya T, Naito T, Kozuka A: A case of left ventricular (LV) outflow tract obstruction caused by accessory endocardial cushion tissue with supra-ventricular aortic stenosis (SVAS). 38th Proceedings of JSUM 1981; 311–312
 - 11) Rodrigues AG, Mercier LA, Tardif JG, de Guise P: Aneurysm of the membranous ventricular septum and accessory valvular tissue causing obstruction of the pulmonary outflow tract in corrected transposition. *J Am Soc Echocardiogr* 1995; **8**: 957–960
 - 12) Prifti E, Bonacchi M, Bartolozzi F, Frati G, Leacche M, Vanini V: Postoperative outcome in patients with accessory mitral valve tissue. *Med Sci Monit* 2003; **9**: RA146–RA153
 - 13) Aoka Y, Ishizuka N, Sakomura Y, Nagashima H, Kawana M, Kawai A, Kasanuki H: Accessory mitral valve tissue causing severe left ventricular outflow tract obstruction in an adult. *Ann Thorac Surg* 2004; **77**: 713–715