

Cardiovascular Imaging In-a-Month

● Echocardiographic Findings of Intracardiac Mass

Hidekazu TANAKA, MD
Hiroya KAWAI, MD, FJCC
Tatsuro ISHIDA, MD
Akihiro YOSHIDA, MD
Mitsuhiro YOKOYAMA, MD, FJCC

CASE

A 71-year-old woman with a two-month history of shortness of breath was referred to our institution for further examination of a mass in the heart. Transthoracic echocardiography (**Fig. 1**) showed the left and right atrial walls were thickened and replaced by an immobile mass extending into the Valsalva sinus and mild pericardial effusion.

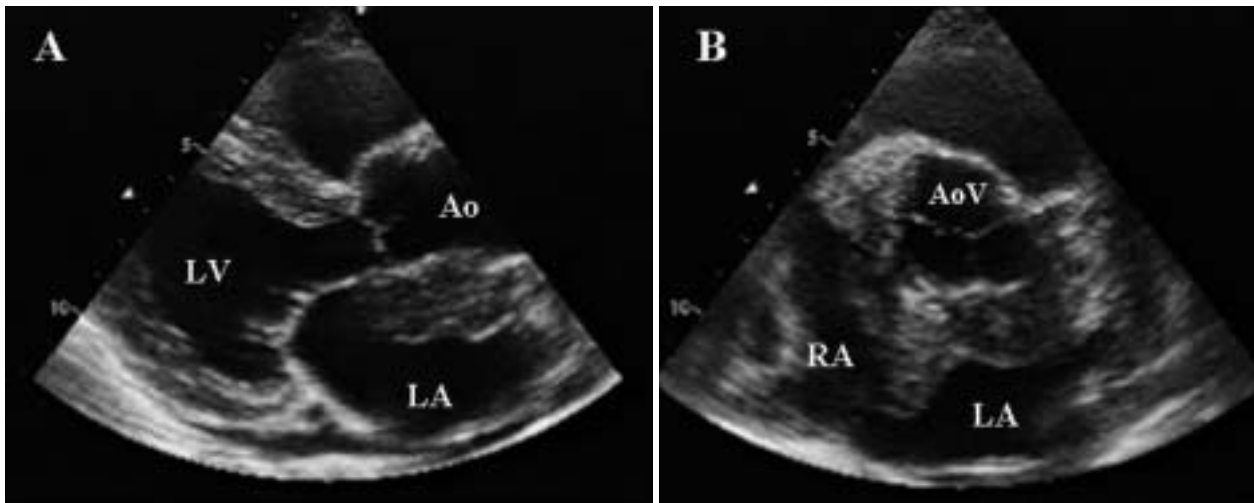


Fig. 1

神戸大学大学院医学系研究科 循環呼吸器病態学〔田中秀和, 川合宏哉, 石田達郎, 吉田明弘, 横山光宏〕: 〒650-0017 神戸市中央区楠町 7-5-2

Division of Cardiovascular and Respiratory Medicine, Department of Internal Medicine, Kobe University Graduate School of Medicine, Kobe

Address for correspondence: KAWAI H, MD, FJCC, Division of Cardiovascular and Respiratory Medicine, Department of Internal Medicine, Kobe University Graduate School of Medicine, Kusunoki-cho 7-5-2, Chuo-ku, Kobe 650-0017; E-mail: hkawai@med.kobe-u.ac.jp

Manuscript received March 30, 2007; revised April 10, 2007; accepted April 17, 2007

Point of Diagnosis

Transesophageal echocardiography (**Fig. 2**) confirmed that both atrial walls were replaced by the abnormal thickened mass, which extended around the aortic root, and enclosed the left main coronary trunk. Full-body computed tomography showed no abnormal lymph node swelling. Whole-body positron emission tomographic imaging with fluo-

rine-18 fluorodeoxyglucose showed positive uptake only in the heart, and no involvement of any malignant cells was observed by bone marrow examination. Endomyocardial biopsy of the mass was performed with disposable biopsy forceps through the right femoral vein and guided by intracardiac echocardiography. Histological examination of the

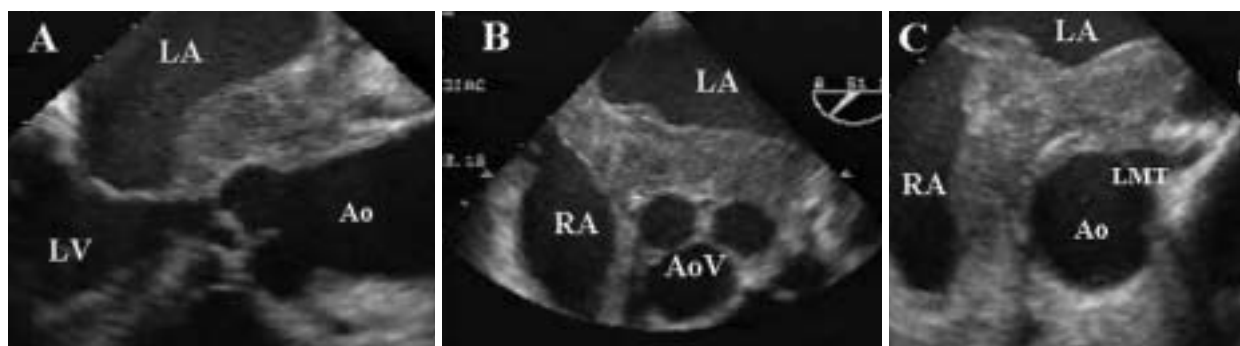

Fig. 2

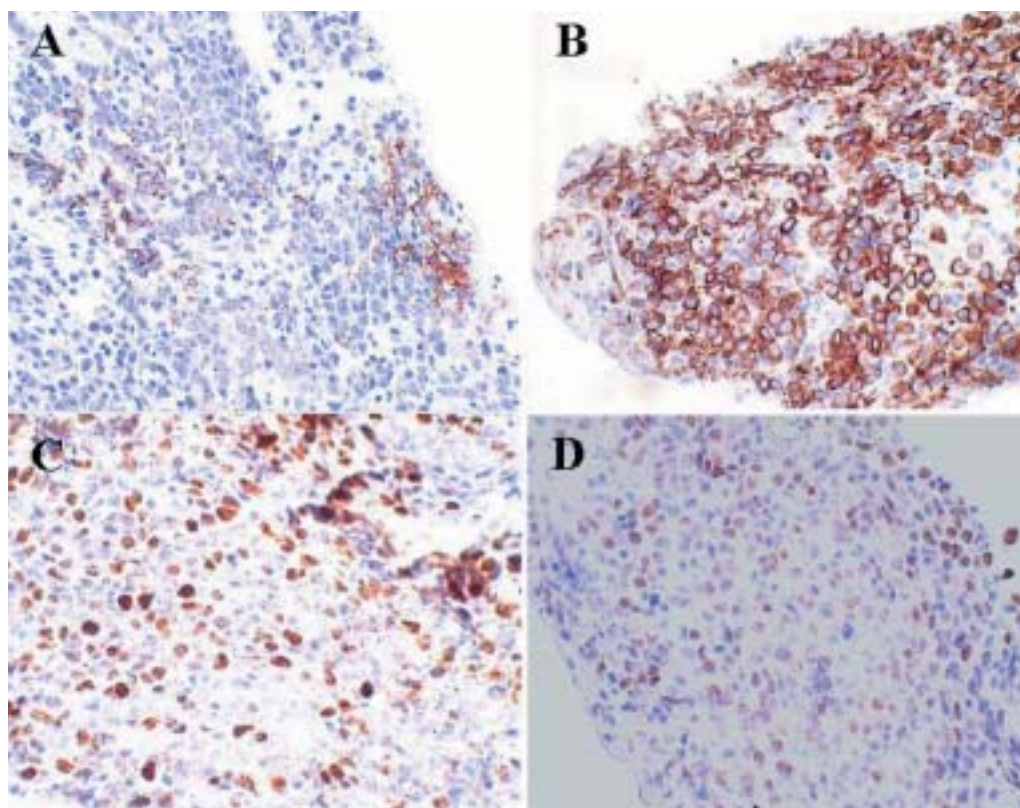


Fig. 3

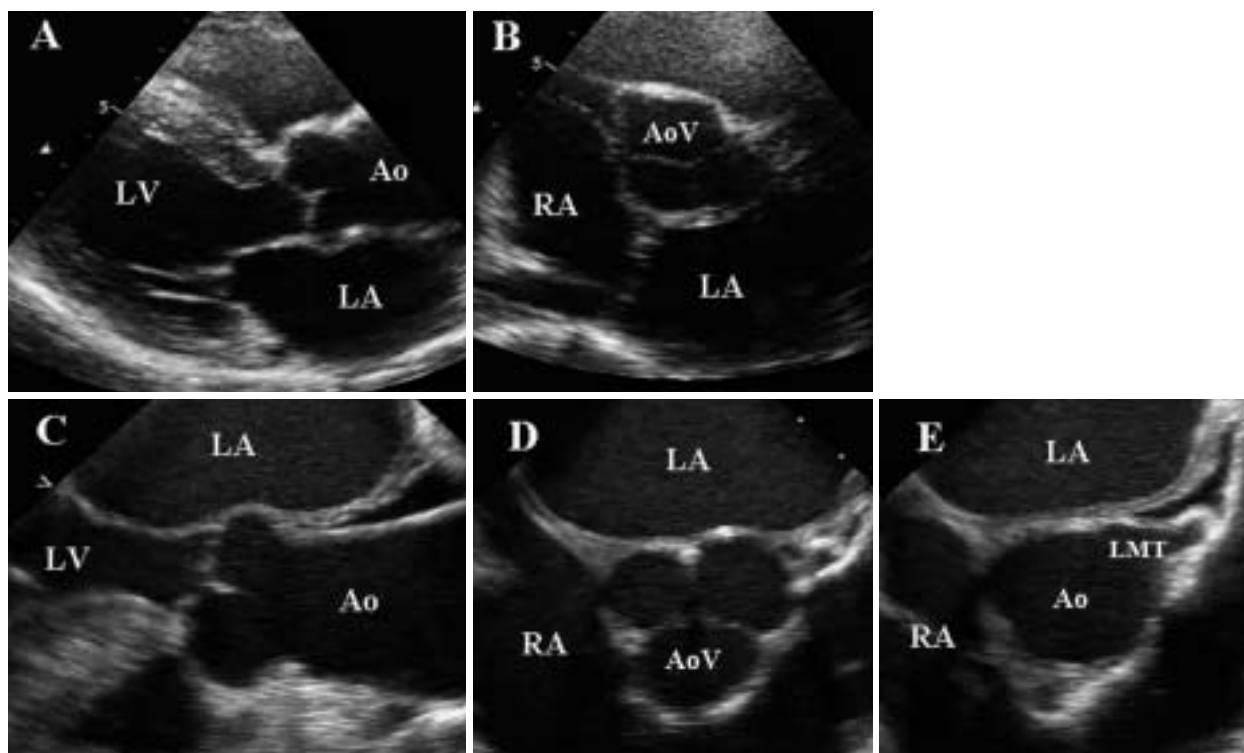


Fig. 4

specimens yielded positive results for B-cell marker CD20, CD79a, MUM1, and PAX5, and negative results for T-cell markers CD3, CD45RO, and CD30 (Fig. 3). Based on a definite diagnosis of primary cardiac diffuse large B-cell lymphoma, the patient was treated with systemic chemotherapy consisting of cyclophosphamide, doxorubicin hydrochloride, vincristine sulfate and prednisolone and monoclonal CD 20 antibody (Rituximab) (R-CHOP). Initial course of the R-CHOP therapy resulted in marked regression of the mass and after four courses the cardiac mass had almost completely disappeared (Fig. 4).

Diagnosis: Primary cardiac diffuse large B-cell lymphoma

Key Words: Drug therapy (chemotherapy); Echocardiography, transesophageal, transthoracic

Fig. 1 Transthoracic echocardiograms on admission

Parasternal long-axis (A) and short-axis (B) views of transthoracic echocardiography showed left and right atrial walls thickened and replaced by an immobile mass extending into the Valsalva sinus.

LA = left atrium; RA = right atrium; LV = left ventricle; AoV = aortic valve; Ao = aorta.

Fig. 2 Transesophageal echocardiograms on admission

Long-axis view (A) and aortic valve (B) and coronary orifice (C) levels of short-axis views of transesophageal echocardiography confirmed that both atrial walls were replaced by the abnormal thickened mass, which extended around the aortic root and enclosed the left main coronary trunk.

LMT = left main coronary trunk. Other abbreviations as in Fig. 1.

Fig. 3 Photomicrographs of the specimens

Histological examination of the specimens yielded positive results for B-cell marker CD20 (A), CD79a (B), MUM1 (C), and PAX5 (D).

Fig. 4 Transthoracic and transesophageal echocardiograms after therapy

The same views as Fig. 1 (A and B) and Fig. 2 (C, D and E) demonstrated that the cardiac mass almost completely disappeared after four courses of the R-CHOP therapy.

Abbreviations as in Figs. 1, 2.