

Static Balloon Atrial Septostomy With Buddy Wire Technique: A Case Report

Hideshi TOMITA, MD, FJCC*¹

Kinya HATAKEYAMA, MD

Wataru SODA, MD

Manabu WATANABE, MD*²

Nobuyuki TAKAGI, MD*²

Abstract

The buddy wire technique, *i.e.* the use of a second 0.014" guidewire placed alongside the one employed to advance balloons, stents or other devices, improves the balloon or stent support and also provides guiding catheter stability. Furthermore, it concentrates forces transferred from the balloon along the line of the wire. We used a second 0.014" Platinum PLUS™ guidewire as a buddy wire during static balloon atrial septostomy in a 19-day-old baby with hypoplastic left heart syndrome, in whom standard balloon atrial septostomy was inadequate even with a fully dilated balloon. This procedure effectively dilated the atrial septal defect.

—J Cardiol 2007 Oct; 50(4): 259–262

Key Words

- Cardiac surgery (static balloon atrial septostomy, buddy wire)
- Heart failure (hypoplastic left heart syndrome)

INTRODUCTION

Hypoplastic left heart syndrome is a lethal obstructive heart defect in neonates. The conventional treatment approach has been to perform an emergency stage one palliation, the Norwood procedure, in the early neonatal period. However, this approach still carries a considerable risk of morbidity and even mortality.¹⁾ The main risk with the Norwood procedure occurs at surgery and during the inter-stage period before second stage palliation.²⁾ A different approach to initial palliation avoids the early Norwood procedure and consists of bilateral banding of the pulmonary arteries combined with some strategy to maintain unrestricted systemic blood flow through the ductus by stenting or continuous infusion of prostaglandin E₁.^{3,4)} This

approach is crucially dependent on establishing unrestricted interatrial communication in the catheterization laboratory. This can be achieved by various techniques including standard balloon atrial septostomy (BAS); Park blade atrial septostomy; static BAS; atrial septostoplasty with cutting balloon followed by static balloon dilation; or even stent implantation in the atrial septum.^{5–9)} Currently in Japan, new devices are often difficult to introduce, so cutting balloons larger than 4 mm are unavailable, Park blades are nearly impossible to obtain, and the specifications of Palmaz Genesis stents suitable as balloon expandable stents applicable to neonates are limited.

We attempted static BAS with the buddy wire technique in a neonate, in whom interatrial communication was hard to dilate by a conventional BAS,

北海道立小児総合保健センター 循環器科,*²心臓血管外科: 〒047-0261 北海道小樽市銭函1-10-1; *²(現)昭和大学横浜市北部病院 循環器センター: 〒224-8503 横浜市都筑区茅ヶ崎中央35-1

Departments of Cardiology and *²Cardiovascular Surgery Hokkaido Children's Hospital and Medical Center, Hokkaido; *¹(present) Cardiovascular Center, Showa University Northern Yokohama Hospital, Yokohama

Address for correspondence: TOMITA H, MD, FJCC, Cardiovascular Center, Showa University Northern Yokohama Hospital, Chigasaki-cho 35-1, Tsuzuki-ku, Yokohama 224-8503; E-mail: tomitah@med.showa-u.ac.jp

Manuscript received May 31, 2007; accepted June 15, 2007

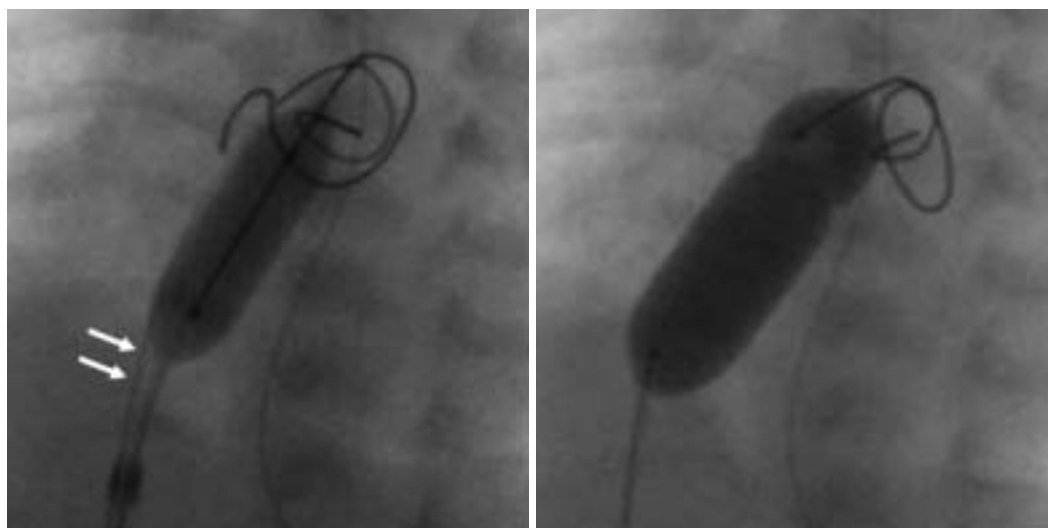


Fig. 1 Balloon dilation

Left: Static balloon dilation with a SLALOM™ balloon, 8mm/2cm. Arrows indicate the 0.014" Platinum PLUS™ guidewire placed as a buddy wire.

Right: Postdilation with a Tyshak II™ balloon, 12mm/3cm.

because of elastic recoil.

CASE REPORT

A 40-week-gestation, 4,010 g male neonate was diagnosed as having hypoplastic left heart syndrome with mitral stenosis, aortic stenosis, an atrial septal defect (ASD) of 4 mm, and a widely patent ductus. Under continuous infusion of lipoprostaglandin E₁, he underwent conventional BAS on day 5 with balloon inflation with 2.5 ml of diluted contrast medium. Echocardiography showed the ASD diameter increased from 3.8 to 4.9 mm, and peak Doppler velocity through the communication decreased from 1.7 to 1.4 m/sec. Pinhole rupture of the balloon complicated the procedure. The next day the patient underwent bilateral pulmonary banding. Subsequently, SaO₂ was controlled around 80%, but mild tachypnea around 50/min persisted and gradually worsened. The ASD diameter was measured at about 4 mm, and the peak velocity gradually increased from 1.2 to 1.5 m/sec. Consequently, we scheduled redilation of the ASD for day 19. Considering the difficulty in achieving unrestricted interatrial communication by the previous conventional BAS procedure, we attempted static BAS with a buddy wire.

We placed a 6F Britetip sheath, 23 cm long (Johnson & Johnson Cordis), in the right atrium from the right femoral vein. Mean left and right

atrial pressures were 11 and 6 mmHg, respectively. After left atrial angiography, we introduced 0.018" and 0.014" Platinum PLUS™ guidewires (Boston Scientific) into the left atrium simultaneously. A SLALOM™ balloon catheter (Johnson & Johnson Cordis) 8 mm/2 cm was placed across the ASD over the 0.018" Platinum PLUS™ and dilated, while the 0.014" Platinum PLUS™ wire was kept in place as a buddy wire. During dilation of the SLALOM balloon, we pulled and pushed the 0.014" Platinum PLUS™ slightly to see the atrial septum. At this point, we decided the stenting of the atrial septum carried a considerable risk of migration, as there was no waist on the balloon even under full dilation, and only a Palmaz Genesis (PG1880BPX, Johnson & Johnson Cordis), dilatable to 8 mm, was available. Consequently, we performed redilation with a Tyshak II™ balloon catheter (NuMED) 12 mm/3 cm without a buddy wire (**Fig. 1**). Mean left atrial pressure decreased to 6 mmHg, and mean right atrial pressure was 5 mmHg. The diameter of the ASD increased from 3.7 mm just before static BAS to 6.7 mm, and the peak velocity decreased to 0.9 m/sec.

DISCUSSION

The present case illustrated a novel modification of transcatheter dilation of the ASD in a situation where neither a Park blade nor a cutting balloon

was available, while stenting was considered risky because of a highly elastic atrial septum. The buddy wire technique, *i.e.* the use of a second 0.014" guidewire placed alongside the one employed to advance balloons, stents or other devices, facilitates otherwise challenging procedures during percutaneous coronary interventions. It improves balloon or stent support and also provides stability to the guiding catheter.^{10,11)} Furthermore, it can be used to focus stretching forces transferred from the balloon along the line of the wire.^{12,13)}

We chose a 0.014"Platinum PLUS guidewire as the buddy wire during static BAS in a patient in whom efficacy of a standard BAS was insufficient even with the use of a fully dilated balloon. This application of this technique is unique in congenital heart diseases. We not only placed a second guidewire along with the balloon for focused-force dilation, but we also pulled and pushed the wire to saw the atrial septum while dilated by the balloon, assuming that the sharp guidewire would cut the septum.

We cannot fully explain how the buddy wire causes a difference from the simple static BAS. However, based on the elastic property of the septum during the standard BAS, we believed that some additional technique was essential to ensure formation of an adequate ASD in this patient. The technique is a simple, quick, readily available, and deliverable for lesions in which simple balloon dilation may be inadequate. We do not have enough data on the size and the material of the guidewire which is optimal for this technique. There may be some increased risk of balloon rupture because of the proximity to the sharp guidewire. Consequently, further studies are required to establish the efficacy and safety of the buddy wire technique in congenital heart diseases, and to clarify the optimal size and material for guidewires for this technique.

Acknowledgements

We thank Dr. Peter M. Olley, Professor Emeritus of Pediatrics, University of Alberta, and Dr. Setsuko Olley for language consultation.

要 約

Buddy Wire を用いた Static 心房中隔裂開術

富田 英 畠山 欣也 早田 航 渡邊 学 高木 伸之

Buddy wire technique はガイドリングカテーテルに挿入したバルーン、ステントなどのデバイスの脇にもう1本0.014インチのガイドワイヤーを挿入するものであり、ガイドリングカテーテルを安定させることにより、バルーンやステントの通過性を高めようとする方法である。また、バルーン拡大に際してはワイヤー部分に拡張力を集中させる効果を持つ。我々はラシュキント法による心房中隔裂開術が無効であった、生後19日の左心低形成症候群に対し、0.014"Platinum PLUSTMガイドワイヤーをbuddy wireとしたstatic心房中隔裂開術を行った。本法により心房中隔を良好に裂開することができた。

J Cardiol 2007 Oct; 50(4): 259–262

References

- 1) Jenkins PC, Flanagan MF, Jenkins KJ, Sargent JD, Canter CE, Chinnock RE, Vincent RN, O'Connor GT: Morbidities in patients with hypoplastic left heart syndrome. *Pediatr Cardiol* 2004; **25**: 3–10
- 2) Mahle WT, Spray TL, Wernovsky G, Gaynor JW, Clark BJ III: Survival after reconstruction surgery for hypoplastic left heart syndrome: A 15-year experience from a single institution. *Circulation* 2000; **102**(Suppl 3): III136–III 141
- 3) Galantowicz M, Cheatham JP: Lessons learned from the development of a new hybrid strategy for the management of hypoplastic heart syndrome. *Pediatr Cardiol* 2005; **26**: 190–199
- 4) Chan KC, Mashburn C, Boucek MM: Initial transcatheter palliation of hypoplastic left heart syndrome. *Catheter Cardiovasc Interv* 2006; **68**: 719–726
- 5) Park SC, Neches WH, Zuberbuhler JR, Lenox CC, Mathews RA, Fricker FJ, Zoltun RA: Clinical use of blade atrial septostomy. *Circulation* 1978; **58**: 600–606
- 6) Vlahos AP, Lock JE, McElhinney DB, van der Velde ME: Hypoplastic left heart syndrome with intact or highly restrictive atrial septum: Outcome after neonatal transcatheter atrial septostomy. *Circulation* 2004; **109**: 2326–2330
- 7) Leonard GT Jr, Justino H, Carlson KM, Rossano JW, Neish

- SR, Mullins CE, Grifka RD: Atrial septal stent implant: Atrial septal defect creation in the management of complex congenital heart defects in infants. *Congenit Heart Dis* 2006; **1**: 129–135
- 8) Daehnert I, Hennig B, Walther T, Kostelka M: Stent implantation for recurrent interatrial obstruction in an infant with hypoplastic heart syndrome. *Pediatr Cardiol* 2005; **26**: 658–661
- 9) Gossett JG, Rocchini AP, Lloyd TR, Graziano JN: Catheter-based decompression of the left atrium in patients with hypoplastic left heart syndrome and restrictive atrial septum is safe and effective. *Catheter Cardiovasc Interv* 2006; **67**: 619–624
- 10) Burzotta F, Trani C, Mazzari MA, Mongiardo R, Rebuzzi AG, Buffon A, Niccoli G, Biondi-Zoccai G, Romagnoli E, Ramazzotti V, Schiavoni G, Crea F: Use of a second buddy wire during percutaneous coronary interventions: A simple solution for some challenging situations. *J Invasive Cardiol* 2005; **17**: 171–174
- 11) Vijayvergiya R, Swamy AJ, Grover A: Buddy wire technique: A simple technique for treating calcified lesion during percutaneous coronary intervention: A case report. *J Invasive Cardiol* 2006; **18**: E129–E130
- 12) Meerkin D: My buddy, my friend: Focused force angioplasty using the buddy wire technique in an inadequately expanded stent. *Catheter Cardiovasc Interv* 2005; **65**: 513–515
- 13) Hussain F, Kashour T, Rajaram M: Ostial RCA intervention: Guiding catheter challenges and use of a buddy wire to perform focused-force angioplasty on a severely calcific ostial right coronary lesion. *J Invasive Cardiol* 2006; **18**: E298–E301